

Dermoid Cyst

WHAT IS A DERMOID?

A dermoid cyst is an overgrowth of normal, non-cancerous tissue in an abnormal location [See figure 1]. Dermoids grow all over the body. Those ones in and around the eye are usually made up of skin, hair, and/or fat.

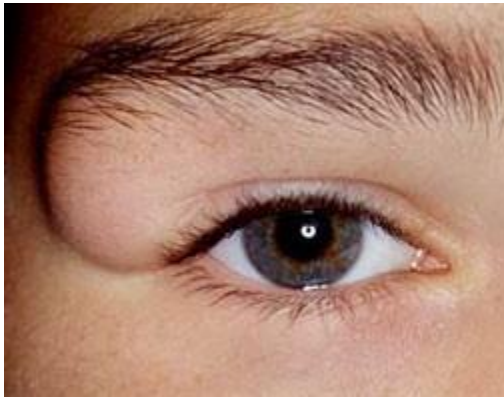


Fig. 1: A dermoid is an overgrowth of normal, non-cancerous tissue in an abnormal location. This dermoid is shown as in the picture as the lump on the outer edge of the eyebrow.

WHERE ARE DERMIODS FOUND AROUND THE EYES?

There are two main types of dermoids that occur on or around the eyes. First, an orbital dermoid is typically found connected to the bones of the eye socket. Second, an epibulbar dermoid is found on the surface of the eye. For epibulbar dermoids there are two typical locations for them to grow. One of the places that epibulbar dermoids grow is where the cornea, the clear part at the front of the eye, meets the sclera, the white part of the eye. This is called a limbal dermoid. The second place an epibulbar dermoid can be found is on the surface of the eye where the lids meet in the corner closest to the ear, which is often called a dermolipoma or lipodermoid.

WHAT DOES AN ORBITAL DERMOID LOOK LIKE?



An orbital dermoid appears as an egg-shaped lump under the skin near the bones of the eye socket. The lump is smooth, firm, and not painful. The skin on top of the dermoid is normal, not red or swollen. Dermoids can change the shape of the bone next to them so they often sit in a small pocket in the bone or may be stuck to the bone. Sometimes dermoids are dumbbell-shaped, with one half of the dermoid on the outer part of the bone of the eye socket and the other part in the inside of the bone of the eye socket (next to the brain). Orbital dermoids are cysts filled with a greasy material that is yellow in color.

WHERE ARE ORBITAL DERMoids USUALLY FOUND?

Orbital dermoids usually form on the outside of the bones surrounding the eye. They typically grow where two bones join to form the eye socket. During development, tissue gets trapped in this area where the bones meet and forms a cyst that slowly grows. The most common place for dermoids to grow is in the upper and outer part of the eye socket near the end of the eyebrow closest to the ear. They can also form next to the bridge of the nose but are rarely found near the bones in the lower part of the eye socket. Rarely, orbital dermoids are found deeper in the eye socket close to the brain.

DO ORBITAL DERMoids NEED TO BE REMOVED?

Dermoids don't usually cause vision loss in the nearby eye. There is a risk, however, that orbital dermoids can open up and cause inflammation around the eye. For this reason, the pediatric ophthalmologist will often recommend that the dermoid be removed. An MRI scan may be needed before surgery to remove to remove the cyst in order to understand how big the dermoid is and how deep in the eye socket it grows.

HOW ARE ORBITAL DERMoids REMOVED?

During surgery, a cut is made in the skin over top of the dermoid. The dermoid is then carefully loosened from the surrounding tissue and bones and removed. The cyst is usually sent to a pathologist who can look at it under a microscope and confirm the diagnosis. Stitches are then placed to close up the cut in the skin.

DO ORBITAL DERMoids CAUSE VISION LOSS?



Not usually. See above for more.

ARE ORBITAL DERMoids FOUND WITH OTHER DISEASES?

No.

WHAT DOES AN EPIBULBAR DERMoid OR DERMOLIPOMA LOOK LIKE?

An epibulbar dermoid is often yellow in color and soft to touch. It doesn't form a cyst like the orbital dermoid. It molds around the curve of the eye. The conjunctiva (thin tissue on top of the white part of the eye) overlying an epibulbar dermoid may be thick. Occasionally there can be hairs sticking out from the mass.

WHERE ARE EPIBULBAR DERMoids (DERMOLIPOMAS) USUALLY FOUND?

Epibulbar dermoids are usually found under the outer part of the upper eyelid in the space where the eyeball meets the eyelid. Depending on how big they are, epibulbar dermoids may be hard to see unless the upper lid is lifted or if larger they may be seen with the eyelids in the usual position.

DO EPIBULBAR DERMoids NEED TO BE REMOVED?

It is rare for epibulbar dermoids to need to be removed. They are usually not bothersome to the patient or patient's family and can be left alone.

HOW ARE EPIBULBAR DERMoids REMOVED?

Epibulbar dermoids are usually not attached to the eyeball itself. They are attached to the conjunctiva, the thin layer of tissue that covers the white of the eye. They often grow behind the eye and into the eye socket and usually cannot be removed completely. Removal of an epibulbar dermoid can be challenging. It involves stripping the dermoid free of the overlying conjunctiva, clamping the mass at the part furthest back behind the eye and removing the front part of the mass. The excised mass is typically sent to a pathologist who can confirm the diagnosis.

DO EPIBULBAR DERMoids CAUSE VISION LOSS?

Not usually.

ARE EPIBULBAR DERMoids SEEN WITH OTHER DISEASES?

Yes, sometimes epibulbar dermoids can be found in persons with problems like: Goldenhar syndrome, linear nevus sebaceous syndrome, and encephalocraniocutaneous lipomatosis. They can also be seen in persons without those syndromes.

WHERE ARE LIMBAL DERMoids USUALLY FOUND?

Limbal dermoids are found on the surface of the eye either on the cornea (the clear shield on the front of the eye) or where the cornea meets the sclera (the white part of the eye) [See figure 2].

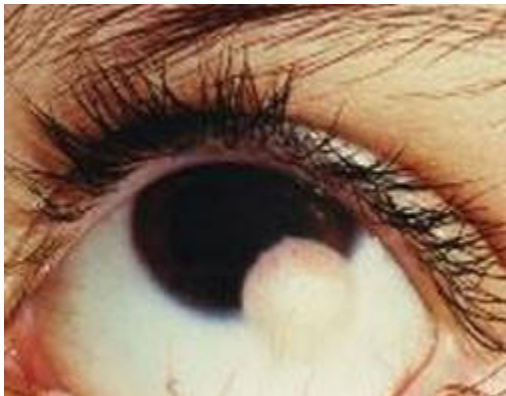

Fig. 2: Limbal epibulbar dermoid.

DO LIMBAL DERMoids NEED TO BE REMOVED?

Limbal dermoids may be removed to help improve the appearance of the eye or to help improve eye irritation.

HOW ARE LIMBAL DERMoids REMOVED?

These dermoids are carefully removed with a surgery in the operating room. Sometimes the epibulbar dermoid deep into the eye so care must be taken to avoid causing problems to the other parts of the eye during removal. After a limbal dermoid is removed, the area under the dermoid may be covered or patched with a piece of transplanted cornea or other tissue.

DO LIMBAL DERMoids CAUSE VISION LOSS?



Sometimes the dermoid is so large that it blocks light from entering the eye and causes problems with vision. More often, the dermoid causes the cornea to have a funny shape. This warping of the cornea can cause [astigmatism](#) and blurry vision. The blurred vision can cause brain to ignore the affected eye, and vision loss through [amblyopia](#). Fortunately, if amblyopia is caught early during childhood, it can often be successfully treated. For more information on amblyopia please visit: <https://aapos.org/glossary/amblyopia>.

DOES THE RISK OF VISION LOSS GO AWAY AFTER THE LIMBAL DERMOID IS REMOVED?

Not typically. Even when the dermoid is gone, it has often already permanently changed the shape of the cornea. The blurry vision and the risk of developing amblyopia remains and may need other treatments.

ARE LIMBAL DERMoids SEEN WITH OTHER DISEASES?

Yes, sometimes. They can be found in persons with problems like: Goldenhar syndrome, linear nevus sebaceous syndrome, and encephalocraniocutaneous lipomatosis, oculoectodermal syndrome, and Townes-Brocks Syndrome. They can also be seen in persons without those syndromes.

Visit [EyeWiki](#) to learn more.

Updated 03/2023