

Anisocoria and Horner's Syndrome

WHAT IS THE PUPIL?

The colored part of the eye is called the iris. It is a round muscle, similar in shape to a donut. The empty hole in the middle, which allows light to enter the eye, is called the pupil. The size of the pupil depends on how much the iris muscle is constricted (tightened). When in a bright room or in sunlight, the pupil usually gets smaller (or constricts). When in a dark room the pupil usually gets bigger (or dilates) to allow more light to enter the eye [See figure 1].

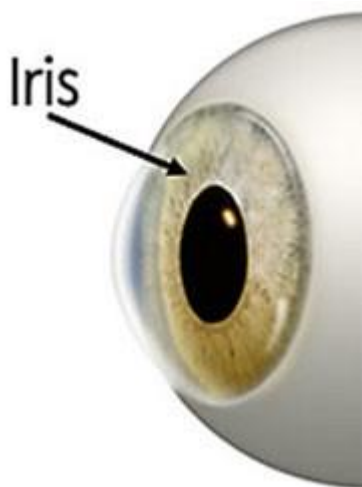


Fig. 1: The iris is the colored part of the eye. In the center, the dark spot is a hole in the iris called the pupil.

IS IT NORMAL TO HAVE PUPILS OF DIFFERENT SIZES?

Normally pupils are in the same size, with both eyes dilating or constricting together. The term anisocoria means that the pupils are not the same size at the same time. Anisocoria can be normal (physiologic), or it can be a sign of a medical problem.

WHEN IS ANISOCORIA NORMAL?

Up to 30% of people have anisocoria and it is normal for them. The amount of anisocoria can be different from day-to-day and can even switch eyes. Anisocoria that is NOT caused by a medical problem is called physiologic anisocoria. Typically, with physiologic anisocoria, the difference in pupil size between the two eyes is small, about one millimeter or less. In physiologic anisocoria, the difference in pupil size does not usually change under bright or dim light. For example if there is a one millimeter difference in



the size of the pupils in bright light, there will be a one millimeter difference in size in dim light as well.

HOW DOES THE DOCTOR DETERMINE WHETHER ANISOCORIA IS DUE TO AN UNDERLYING MEDICAL PROBLEM?

Certain signs, such as when the anisocoria was first noted, whether it is more noticeable in bright or dim light, and whether there was an event that happened in the past that could have caused it, will help the ophthalmologist understand the cause. A complete eye exam is performed by an ophthalmologist to check vision, eyelid position, how the eyes move, and the health of the front and back of the eyes (among other things). The ophthalmologist will look at the size of the pupils and how they react to bright and dim light. Based on the exam, the ophthalmologist may do extra tests with eyedrops, blood work or CT scan/MRI.

HOW DOES THE DOCTOR KNOW IF THE BIG PUPIL IS 'TOO BIG' OR THE SMALL PUPIL IS 'TOO SMALL'?

One of the most important parts of the exam for anisocoria is figuring out which pupil is not normal. If the difference in size between the pupils is larger in the dark, then the smaller pupil may not be reacting well and could be the abnormal one. On the other hand, if the difference in pupil size is larger in bright light, then the larger pupil may be the abnormal one because it is not getting smaller (or constricting) like it should.

WHAT ARE SOME CAUSES OF AN ABNORMALLY LARGE (DILATED OR MYDRIATIC) PUPIL?

- Trauma to the eye can damage the iris tissue and the iris muscle so that it does not work well. The pupil on the injured iris is often larger than the normal side.
- Medications such as some eye drops, nose sprays or medicine skin patches can enlarge or dilate the pupil. Tell your ophthalmologist about any medications that might have accidentally gotten into the eyes.
- Adie's tonic pupil syndrome is a problem that can affect pupil constriction. The pupil is slow to react and may not react as much. There may be other signs like decreased deep tendon reflexes and difficulty seeing at near in people with Adie's tonic pupil.
- A weakness of the third cranial nerve (a nerve that comes from the brain to the eye and controls eyelid movement, eye movement, and pupil size) can cause dilation of the pupil. Along with pupil dilation, there is often droopiness (known as [ptosis](#)) of the upper eyelid on the same side as the larger (dilated) pupil. In addition, the eye may not move normally and the child may have double vision. A third cranial nerve weakness can be a

sign of a serious condition, and the ophthalmologist may want to order testing, including imaging studies of the brain (MRI or CT scan).

WHAT ARE SOME CAUSES OF AN ABNORMALLY SMALL (MIOTIC) PUPIL?

Inflammation inside the eye (iritis,), whether from trauma or another cause of iritis, can result in a small (miotic) pupil. Horner's syndrome can also cause a small pupil one eye.

WHAT ARE THE SIGNS OF HORNER'S SYNDROME?

In Horner's syndrome, the pupil on the eye with the problem is smaller and does not dilate (increase in size) as well as the other eye. The difference in pupil size between the two eyes is more noticeable in dim light. The child may have mild droopiness (ptosis) of the upper eyelid [See figure 2]. Sometimes the lower eyelid on the side with the problem may be slightly higher than normal (known as inverse ptosis). When the upper eyelid is slightly lower than normal and the lower eyelid is slightly higher than normal, the eye may look smaller.

If the Horner's syndrome started during the first year of life, the colored part of the eye (iris) on the affected side may be lighter in color than the normal side. It is called heterochromia when the two eyes are different colors. Sometimes, the pressure in the eye is lower in the eye with Horner's syndrome and sometimes there is less sweating or less flushing of the skin on the face on the affected side (anhidrosis).



Fig. 2: In Horner's syndrome, ptosis may occur in the eye with the smaller pupil.

WHAT ARE THE CAUSES OF HORNER'S SYNDROME IN CHILDREN?

Horner's syndrome is caused by injury to specialized nerves (the sympathetic nerves) in the brain, neck, or upper chest on the same side as the smaller pupil. These nerves control the muscles that constrict the pupil and raise the eyelid. Horner's syndrome can be divided into congenital (occurring in the first 4 weeks of life) and acquired cases (those



that happen after 4 weeks of life). Congenital Horner's most commonly occurs from neck/shoulder trauma during childbirth. Injury to the neck or shoulder can damage the sympathetic nerves traveling in the brachial plexus (group of nerves in the shoulder and arm). Often there is no known cause for congenital Horner's syndrome. Acquired cases (occurring after 4 weeks of age) can be due to neck trauma, neck surgery, or a tumor or growth in the chest, neck, or brain. In children, Horner's syndrome may be caused by a tumor called neuroblastoma. Neuroblastoma is a tumor that comes from other parts of the body and spreads to the sympathetic nerves that control the pupil. Although rare, neuroblastoma is more likely to be seen with acquired Horner's syndrome than it is with congenital cases.

WHAT TESTS MAY BE CONSIDERED WHEN HORNER'S SYNDROME IS SUSPECTED?

When eye exam findings point towards a diagnosis of Horner's syndrome, extra testing may be needed. There are tests that the ophthalmologist may do in the office using eye drops to confirm a diagnosis of Horner's syndrome. When Horner's syndrome is diagnosed in a child, the ophthalmologist may also order imaging studies (CT scan or MRI) and urine tests to understand the cause of the Horner's syndrome.

Speak with your ophthalmologist if you have more questions about anisocoria or Horner's syndrome.

For more scientific information on anisocoria or Horner's syndrome see:

<https://eyewiki.org/Anisocoria>

https://eyewiki.org/Horner_Syndrome

Updated 03/2023