American Association for Pediatric Ophthalmology and Strabismus

AAPOS 45TH ANNUAL MEETING

ABSTRACT BOOK

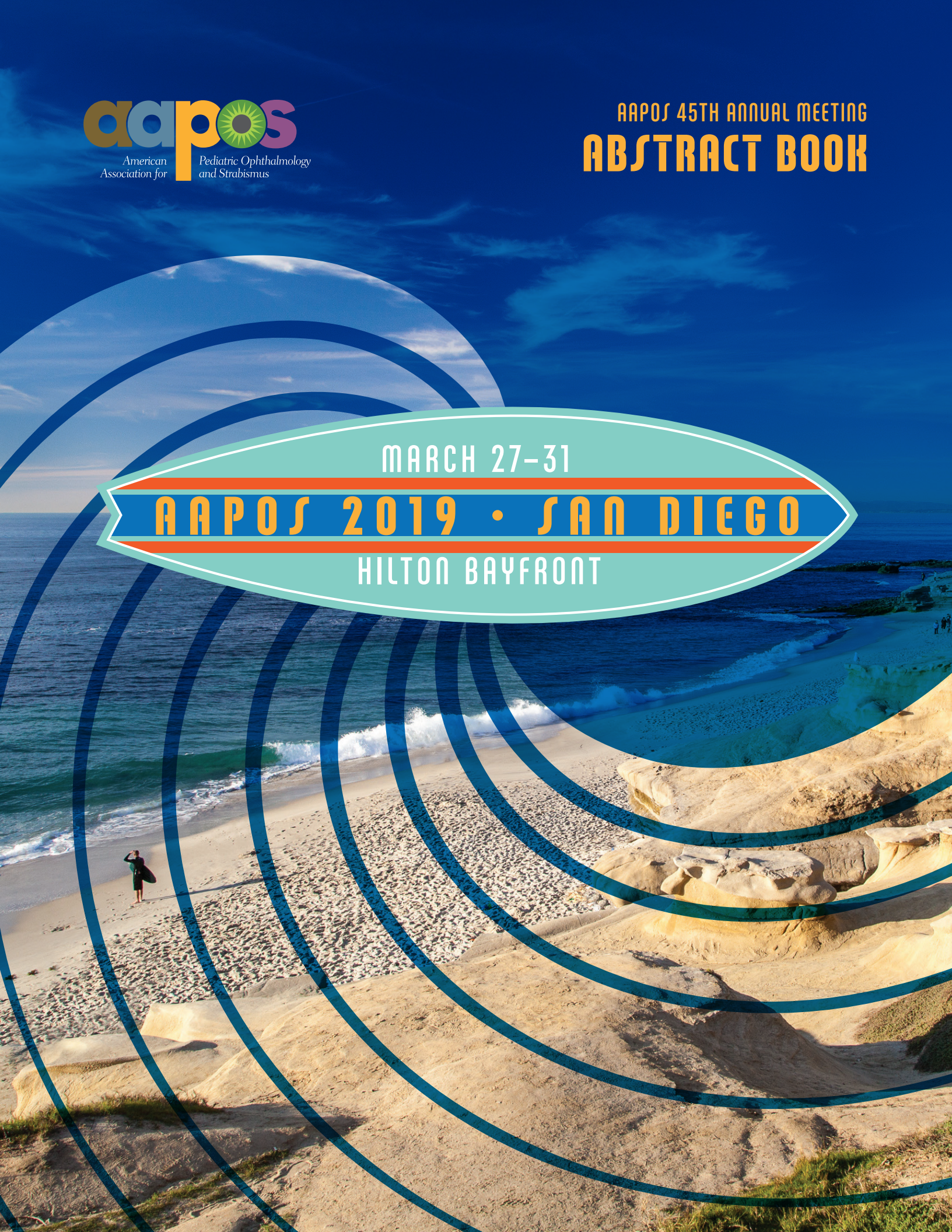

Table of Contents

Lectures
- Costenbader page 3
- Helveston page 4

Papers page 5

Posters page 44
- Session 1 page 45
- Session 2 page 145

Workshops page 245

The Costenbader Lecture

Making the Superior Oblique Great Again

David A. Plager, MD

Purpose/Relevance: To review the history and bring up to date clinically relevant knowledge about the anatomy and physiology of the superior oblique

Target Audience: Strabismus surgeons

Current Practice: Varies widely among strabismologists according to their training and personal experience

Best Practice: Evaluation and treatment algorithms based on the author's 30 years of learning from others, personal experience and mistakes. There will be emphasis on the importance of relative tendon laxity, how it is easily evaluated and how it can be applied to surgical decision making. When torsion should be specifically addressed or perhaps can be willfully ignored will be discussed.

Expected Outcomes: Audience will have an appreciation of the history of strabismologist attitudes toward operating on the superior oblique, the evolution of knowledge about its structure and function, and the author's approach toward formulating individual surgical plans based on a combination of clinical and intraoperative findings.

Format: Lecture supplemented with illustrations and videos

Summary: The superior oblique is by far the most complicated extraocular muscle and the source of more angst and controversy when learning how best to approach its dysfunction than all the other EOMs combined. However, by applying a few basic principles and avoiding a few common pitfalls, surgeons can have many grateful patients whose annoying or even debilitating symptoms they have relieved.

Cataract Surgery in Children from Birth to Less than 13 Years of Age in the PEDIG Registry: Status Three Years Following Surgery

Michael X. Repka, MD, MBA for the Pediatric Eye Disease Investigator Group
Jaeb Center for Health Research, Tampa, Florida

Introduction: To describe visual outcome and complications three years following lensectomy in children.

Methods: Prospective observational study in children <13 years of age at time of lensectomy with follow-up between 30 and 42 months after surgery. Review of registry data for 789 eyes of 611 children for visual acuity, rates of amblyopia, change in refractive error, glaucoma and glaucoma suspect, and other intraocular surgery.

Results: Lens surgery was bilateral in 274 (45%; 95% confidence interval (CI)=41% to 49%) children and unilateral in 337 (55%; 95% CI=51% to 59%). An intraocular lens (IOL) had been implanted in 414 (56%; 95% CI=52% to 59%) eyes. Amblyopia was identified in 390 (64%; 95% CI=60% to 68%) children. In 488 children 3 years of age and older at follow up, the mean VA was 0.53 (about 20/63) in bilateral aphakic eyes, 0.28 (about 20/40) in bilateral pseudophakic eyes, 0.90 (20/160) in unilateral aphakic eyes, and 0.54 (about 20/63) in unilateral pseudophakic eyes. Age-normal visual acuity was reported for 117 (32%; 95% CI=27% to 37%) pseudophakic eyes and 45 (27%; 95% CI=20% to 35%) aphakic eyes.

A myopic shift in refractive error was found with a mean change of -6.87D (95% CI= -8.45 to -5.28) in bilateral aphakia, -1.28D (95% CI= -1.57 to -0.98) in bilateral pseudophakia, -10.66D (95% CI= -13.43 to -7.90) in unilateral aphakia, and -1.41D (95% CI= -1.75 to -1.06) in unilateral pseudophakia.

A new diagnosis of glaucoma or glaucoma suspect was made in 97 (13%; 95% CI=10% to 15%) eyes. Additional intraocular surgery was performed in 259 (33%; 95% CI=30% to 37%) eyes, most commonly vitrectomy or membranectomy to clear the visual axis.

Discussion: About one-third of the eyes with IOLs achieved normal VA for age by 3 years post-lensectomy. Management of visual axis obscuration was the most common surgical intervention, also affecting one-third of eyes.

Conclusion: Myopic shift was minimal with the placement of an IOL, about 0.50D per year. This finding will affect the ultimate refractive outcomes and may require adjustment of guidelines for IOL power selection.

Papers

Paper #1
Thursday, 8:50 am – 8:57 am

Are Piggyback IOLs Recommendable for Children?

M. Edward Wilson, MD; Rupal H. Trivedi, MD, MSCR

Storm Eye Institute
Medical University of South Carolina

Introduction: The selective use of piggyback IOLs for young children has been reported since the mid-1990s but only in small numbers and without longer term follow-up. Surgeons currently have insufficient information about whether these techniques are recommendable.

Methods: An IRB-approved retrospective chart review was conducted of consecutive cases of piggyback IOL implantation in children at one institution.

Results: 51 eyes of 40 children received piggyback IOL implantation, 42 eyes at the time of cataract surgery and 9 eyes as a later secondary procedure. Median age at cataract surgery and piggyback IOL placement were 0.51 and 0.73 years respectively. 4/51 (8%) eyes underwent unplanned piggyback IOL removal (1 each for IOL tilt, pupillary capture, pupillary block, and pupillary membrane). 44 eyes had >5 years of follow-up (median 12.42 years of follow-up). 35/44 eyes had the piggyback IOL explanted in a planned manner at a median 3.24 years after implantation. 9 eyes have still not had the piggyback IOL explanted after a median 11.6 years of follow-up. 9 eyes have needed IOP-lowering topical medications, and 1 eye has been operated for glaucoma.

Discussion: Planned sulcus IOL explantation was uncomplicated in our series. While early-unplanned complications required IOL removal in 4 eyes, late complications were not noted and glaucoma developed at predictable rates for this population.

Conclusion: Piggyback IOL placement in young children (1 in the bag and 1 in the sulcus) appears to have an acceptable safety profile. It allows the surgeon to aim for emmetropia at surgery and manage increasing myopia over time rather than decreasing hyperopia.

References: Wilson ME, Peterseim MW, Englert JA, et al. Pseudophakia and polypseudophakia in the first year of life. J AAPOS 2001; 5:238-245.

Paper #2
Thursday, 8:57 am – 9:04 am

Outcomes of Bilateral Cataracts Removed in Infants 1 to 7 Months of Age Concurrent with the Infant Aphakia Treatment Study

Erick D. Bothun, MD; Deborah K. Vanderveen, MD; David A. Plager, MD; Sharon Freedman, MD; Rupal H. Trivedi, MD, MSCR; Nancy N. Diehl, BS; M. Edward Wilson, MD; Elias I. Traboulsi, MD, Med; Jill S. Anderson, MD; Nancy C. Weil, MD; Allison R. Loh, MD; David Morrison, MD; Kimberly G. Yen, MD; Scott Lambert, MD

Mayo Clinic
Rochester, Minnesota

Introduction: This study evaluates outcomes of bilateral cataract surgery in infants ages 1 to 7 months performed by Infant Aphakia Treatment Study (IATS) investigators during IATS recruitment and compares them to IATS outcomes of unilateral cases.

Methods: Retrospective clinical study at 10 IATS sites

Results: 178 eyes (89 children) were identified with median age of 1.8 months (range 1-7) at cataract surgery. 51 (29%) eyes of 26 patients received primary intraocular lens (IOL) implantation. Of the 60 children followed between 4-6 years of age with optotype visual acuity (VA) testing, corrected visual acuity was excellent (<20/40) in 45% of better seeing eyes and 20% of worse-seeing eyes. 2% had poor acuity (>20/200) in the better eye and 10% in the worse eye. Median best eye visual acuity was 20/50 (logMAR 0.40) (p=0.84)) in both aphakic and pseudophakic children. Unplanned reoperation occurred in 29% of right eyes (including glaucoma surgery in 9%).

Discussion: Good visual outcomes were obtained in both eyes following bilateral infantile cataract surgery. With or without the inclusion of children who tested poorly due to associated neurologic disease, the VA of the worse seeing eye in these bilateral cases is better than VA in unilateral cases included in the IATS. The rates of reoperation and glaucoma are consistent with the published IATS data. Aphakia management did not affect visual acuity outcomes.

Conclusion: Visual acuity after bilateral cataract surgery in infants younger than 7 months is better than VA following unilateral cataract surgery, but adverse events were similar.

References: 1. The Infant Aphakia Treatment Study Group. Comparison of Contact Lens and Intraocular Lens Correction of Monocular Aphakia During Infancy A Randomized Clinical Trial of HOTV Optotype Acuity. JAMA Ophthalmol. 2014;132(6):676-682.
2. Plager DA, Lynn MJ, Buckley EG, Wilson ME, Lambert SR; Infant Aphakia Treatment Study Group. Complications in the first 5 years following cataract surgery in infants with and without intraocular lens implantation in the Infant Aphakia Treatment Study. Am J Ophthalmol. 2014 Nov;158(5):892-8.

Paper #3
Thursday, 9:04 am – 9:11 am

Outcomes and Complications of Simultaneous Bilateral Cataract Surgery (SBCS) in Children - A 10-Year Review

Vishaal Bhambhwani; Sina Khalili; Maram Isaac; Asim Ali; Nasrin Tehrani; Kamiar Mireskandari

The Hospital For Sick Children (SickKids), Toronto, Canada
Toronto, Canada

Introduction: SBCS has been viewed with caution by the ophthalmology community due to risk of devastating complications in both eyes. There is paucity of literature in children, for whom significant benefits can be derived by operating both eyes under the same anesthesia.

Methods: Retrospective analysis of children who underwent SBCS from 2008-2018 was performed. Procedures were consented to by parents following detailed discussion about risks/benefits of surgery in two sessions versus one. Data on outcomes and complications (ophthalmological, anesthesia-related) upto 8 weeks post-op is presented.

Results: 37 patients (74 eyes) (mean-age 4.4 months) (21F:16M) underwent bilateral lens aspiration with anterior vitrectomy (6 with, 68 without IOL). Average ASA score was 2.1 (1-4). 19 were admitted for observation post-surgery (per anesthesia protocol). There were no devastating anesthesia-related complications; however, one with aortic stenosis needed phenylephrine support, one was managed with re-intubation (laryngeal spasm post-op) with no further complications.
Average 3.89 follow-up visits (in 8 weeks post-op) occurred. One patient had fibrinous reaction and another glaucoma (needing goniotomy) in both eyes associated with Wolfram and Lowe syndromes, respectively. One eye had epithelial defect (resolved spontaneously). There was no endophthalmitis.

Discussion: SBCS in children have several potential advantages including avoidance of multiple anaesthesia, faster visual rehabilitation, reduced post-operative follow-up visits, cost savings to parents and healthcare systems.

Conclusion: Outcomes and complication rates of SBCS in this study were comparable to reported literature for unilateral procedures. SBCS may be offered to parents as a viable option; however, studies with larger sample sizes are desirable.

References: 1. Lambert SR, Dave H, Phoenix V, Becker ER. Simultaneous vs Sequential Bilateral Cataract Surgery for Infants With Congenital Cataracts: Weighing the Risks of General Anesthesia During Infancy vs Endophthalmitis. Arch Ophthalmol. 2011;129(4):512-526.
2. Nallasamy S, Davidson SL, Kuhn I, Mills MD, Forbes BJ, Stricker PA, et al. Simultaneous bilateral intraocular surgery in children. J AAPOS. 2010;14:15-9.

Paper #4
Thursday, 9:15 am – 9:22 am

Home Tonometry Redefines Glaucoma Drainage Device Management in Childhood Glaucoma

Michelle S. Go, MD; Navajyoti R. Barman, BS; Robert J. House, MD; Sharon F. Freedman, MD

Department of Ophthalmology, Duke University Medical Center
Durham, NC

Introduction: The postoperative management of the non-valved Baerveldt glaucoma drainage device (GDD) presents challenges in children due to widely variable intraocular pressure (IOP) often occurring perioperatively. We evaluated the use of home tonometry in the management of Baerveldt GDDs for refractory childhood glaucoma.

Methods: As part of an ongoing prospective study involving home rebound tonometry, the families of patients receiving Baerveldt GDDs were trained to use the Icare® rebound tonometer (Ta01,Finland,Oy) and asked to document IOP, relevant symptoms, and medication changes onto a web-based data application or Excel spreadsheet. Data were analyzed for time to tube opening, multiple-day fluctuations, and various IOP trends. Clinician response to IOP fluctuations detected by home tonometry was also evaluated.

Results: Included were 19 patients (mean age 16.1+/-9.6 years) having Baerveldt implantation from 2015-2018 by one attending. Home tonometry detected 100% (12/12) of spontaneous tube openings, which occurred at 6.0+/-0.5 weeks. Mean IOP decreased 32.8% (25.1 vs. 16.9 mmHg, $P < 0.01$) and 5-day IOP fluctuation decreased from 14.5 to 6.2 mmHg ($P < 0.05$) after tube opening. Preoperative, post-implantation, and post-opening IOP ranged 11-59, 3-61, and 1-50 mmHg, respectively. Home tonometry corroborated clinical hypotony in 5 eyes and early hypertensive phase in 9. It prompted 75 documented medication changes among 14 patients.

Discussion: Home rebound tonometry accurately detected tube opening and alarming IOP fluctuations, allowing clinicians to promptly and appropriately respond to these events.

Conclusion: Home tonometry-augmented GDD management in childhood glaucoma may improve care of these challenging patients.

References: Bitner DP, Freedman SF. Long-term home monitoring of intraocular pressure in pediatric glaucoma. Journal of American Association for Pediatric Ophthalmology and Strabismus. 2016;20(4):515-518.
Mali YP, Rotruck JC, Bitner DP, Freedman SF. Home tonometry in childhood glaucoma: clinical indications and physician and parental attitudes. Journal of American Association for Pediatric Ophthalmology and Strabismus. 2018;22(4):319-321.

Paper #5
Thursday, 9:22 am – 9:29 am

Trabeculotomy Ab-Interno with the Trab360 Device for Childhood Glaucomas

Raymond G. Areaux, Jr, MD; Alana L. Grajewski, MD; James D. Brandt, MD; Beth Edmunds, MD, PhD; Elena Bitrian, MD

University of Minnesota
Minneapolis, MN, USA

Introduction: The Trab360 (Sight Sciences) device facilitates up to 360 degrees of trabeculotomy ab-interno via clear corneal incision (Trab360). This study investigated the success rate and complications of Trab360 in childhood glaucomas.

Methods: Multicenter retrospective review of eyes with childhood glaucomas that underwent Trab360 with at least 3 months follow-up. Post-operative IOP less than 25 mmHg with or without medications and no additional glaucoma surgery defined success.

Results: 48 eyes of 43 patients were included. Mean age at surgery was 83 months; 50% occurred prior to 20 months. 50% were right eyes; 43% were male. Mean treatment was 293 degrees. Mean follow-up was 14.8 months. Preoperative IOP was 31.2 ± 6.9 mmHg; postoperative reduction of IOP was 17 [95% CI 14.3-19.7] mmHg. Mean number of preoperative glaucoma medications was 2.7 ± 1.4; mean decrease postoperatively was 1.2 [95% CI 0.7-1.7]. 69% [95% CI: 53.6%-80.9%] of eyes succeeded. Among the 42 eyes for which Trab360 was the first glaucoma surgery, 71.4% [95% CI 55.2%-83.8%] succeeded. 83.3% [95% CI 61.8%-94.5%] of PCG eyes succeeded. Among PCG eyes for which Trab360 was the first glaucoma surgery, 85.7% [95% CI 62.6%-96.2%] succeeded. Two eyes (4.2%) suffered partial cyclodialysis. There were no other significant complications.

Discussion: Trab360 success resembles literature on other angle surgeries for childhood glaucomas. Good surgical technique and caution in high-risk angles is imperative to avoid cyclodialysis. Our study is limited by the imperfections inherent in any retrospective analysis.

Conclusion: Trabeculotomy ab-interno with the Trab360 device is effective and safe for treating childhood glaucomas, especially PCG.

References: 1. Girkin CA, Rhodes L, McGwin G, Marchase N, Cogen MS. Goniotomy versus circumferential trabeculotomy with an illuminated microcatheter in congenital glaucoma. J AAPOS 2012;16:424-7.
2. Bothun ED, Guo Y, Christiansen SP, et al. Outcome of angle surgery in children with aphakic glaucoma. J AAPOS 2010;14:235-9.
3. Neely DE. False passage: a complication of 360 degrees suture trabeculotomy. J AAPOS 2005;9:396-7.

Paper #6
Thursday, 9:33 am – 9:40 am

Failure of Methotrexate Monotherapy and Subsequent Response to Tumor Necrosis Factor Inhibitors in Pediatric Non-Infectious Uveitis

Basak Can Ermerak, MD; Erin D. Stahl, MD; Ashley M. Cooper, MD; Katie Keck, MD

Children's Mercy Hospital
Kansas City, MO

Introduction: This study aimed to determine the rates of treatment failure with methotrexate (MTX) monotherapy and subsequent efficacy of anti-tumor necrosis factor (TNF) alpha inhibitors adalimumab (ADA) and infliximab (IFX) in refractory pediatric noninfectious uveitis.

Methods: The charts of patients evaluated with non-infectious uveitis between January 2013 and December 2017 were reviewed retrospectively. Data recored included: demographic information, site and degree of uveitis, associated systemic conditions, systemic and topical therapy. Treatment failure was defined as steroid dependence with persistent or recurrent inflammation despite maximum dose for 3 months or longer.

Results: Seventy-three patients (male/female=33/40) were included. Anterior uveitis (AU) was the most common presentation (n=51 total; juvenile idiopathic arthritis (JIA) associated n=23, idiopathic n=28), followed by pars planitis (n=13) and panuveitis(n=9). Mean age at diagnosis was 7.6 years. Mean follow-up period was 76.5 months (range 18-192). Overall treatment failure with MTX monotherapy was 83.5%. Of those who failed MTX monotherapy, 27 were controlled with ADA and 10 with IFX as the first additional treatment. Twenty one patients on ADA therapy were switched to IFX for persistent inflammation and %85.7 were controlled. Subgroup analysis for each type of uveitis was further performed.

Discussion: There is limited data on control of various pediatric uveitis subtypes with MTX monotherapy. This study suggests many patients with uveitis require TNF inhibitors for disease control.

Conclusion: MTX was effective as monotherapy in less than 50% of pediatric uveitis patients. Additional IFX and ADA were effective and safe treatment modalities to achieve steroid-free remission for pediatric uveitis.

References: 1- Simonini G, Paudyal P, Gareth T, et al. Current evidence of methotrexate efficacy in childhood chronic uveitis: a systematic review and meta-analysis approach. Rheumatology (Oxford) 2013;52:825–31.
2- Simonini G, Taddio A, Cattalini M, et al. Prevention of flare recurrences in childhood- refractory chronic uveitis: An open-label comparative study of adalimumab versus infliximab. Arthritis Care & Research. 2011 Apr;63(4):612-8.
3- Vallet H, Seve P, Biard L, et al. Infliximab versus adalimumab in the treatment of refractory inflammatory uveitis: a multicenter study from the French Uveitis Network. Arthritis & Rheumatology. 2016 Jun;68(6):1522-30.

Paper #7
Thursday, 11:45 am – 11:52 am

Optical Coherence Tomography Guided Localization and Laser Photocoagulation of Invisible New Retinoblastoma

Sameh E. Soliman; Cynthia VandenHoven; Leslie Mackeen; Brenda L. Gallie

The Hospital for Sick Children, the University of Toronto
Toronto, ON, Canada

Introduction: Invisible retinoblastoma tumors are now detected by prenatal identification of RB1 pathogenic variants inherited from affected parents, followed by early delivery with screening for retinal tumors using handheld optical coherence tomography (OCT). Laser photocoagulation is challenging, requiring exact localization of an invisible tumor. We describe an OCT-guided localization and photocoagulation technique and its preliminary outcome.

Methods: OCT revealed round homogeneous invisible tumors within the inner nuclear layer. Software calipers placed beside anatomical retinal landmarks (branched/curved vessels, fovea or optic disc) mapped the tumor location and extent. A single laser (532 nm) burn flagged the location and OCT evaluated the tumor-laser burn relationship; laser treatment was then continued in the correct location. Post-laser OCT ensured complete treatment. This technique was used to treat 11 new invisible posterior pole tumors in 7 eyes of 5 children.

Results: Localization and tumor-laser burn relationships were 100% accurate. All showed swelling and hyper-reflectiveness in post-laser OCT. A maximum of 2 photocoagulation sessions (2 weeks apart) were sufficient to successfully manage 10/11 (91%) tumors with resulting permanent scars. Two tumors (18%) developed OCT-detected subclinical recurrences within 4 months, each treated by one laser session. No treatment scar showed migration, foveal involvement or retinal traction at 1 year follow-up.

Discussion: Precise localization avoided misapplied laser burns, preserving normal retina resulting in small treatment scars with less treatment burden and a good visual outcome (no foveal involvement by tumor/laser).

Conclusion: OCT-guided localization and photocoagulation technique is valuable in achieving precision results in managing invisible new retinoblastoma tumors.

References: 1. Rootman DB, Gonzalez E, Mallipatna A, Vandenhoven C, Hampton L, Dimaras H, et al. Hand-held high-resolution spectral domain optical coherence tomography in retinoblastoma: Clinical and morphologic considerations. Br J Ophthalmol. 2013;97:59–65.
2. Soliman SE, VandenHoven C, MacKeen LD, Héon E, Gallie BL. Optical coherence tomography-guided decisions in retinoblastoma management. Ophthalmology. 2017;124:859–72.
3. Welch RJ, Rao R, Gordon PS, Say EAT, Shields CL.Optical Coherence Tomography of Small Retinoblastoma.Asia Pac J Ophthalmol (Phila). 2018 Jul 9. doi: 10.22608/APO.2018189.

Paper #8
Thursday, 11:52 am – 11:59 am

Comparison of Outcomes, Adverse Events, and Treatment Burden of Intravenous Chemotherapy vs. Intra-Arterial Chemotherapy for Retinoblastoma: Results of a Pilot Study

Pranav R. Santapuram, BA; Jessica L. Burris, BS; Debra L. Friedman, MD; Tatsuki Koyama, PhD; Anthony B. Daniels, MD, MSc

Vanderbilt University Medical Center
Nashville, TN

Introduction: Intra-arterial chemotherapy (IAC) is gaining widespread acceptance to treat retinoblastoma, replacing intravenous chemotherapy (IVC) in many centers (1). Higher globe salvage rates are reported with IAC than IVC. A direct comparison of adverse events and treatment burden with each modality has not been performed.

Methods: Pilot retrospective cohort study of 20 consecutive patients (IVC only=9, IAC only=7, IAC after IVC failure=4). Globe salvage rate, unplanned healthcare visits, cytopenias, transfusions, and opioid usage were recorded, both during treatment and in the 12-months following treatment completion. Primary outcomes were globe salvage, number of grade 3/4 cytopenias, number of transfusions, number of unplanned healthcare visits, and opioid use.

Results: Compared to patients receiving IAC, patients receiving IVC had more unplanned healthcare visits (1.0 (0.5, 1.0) vs. 4.0 (1.0, 5.2) [IAC vs. IVC], p=0.012) more grade 3/4 cytopenias (1.0 (1.0, 2.0) vs. 6.0 (5.0, 9.2) p<0.001), more transfusions (0.0 (0.0, 0.0) vs. 4.0 (1.0, 5.2), p=0.004), required greater use of opioids (mean oral morphine equivalents: 63.5 (37.4, 79.1) vs. 120.1 (79.2, 142.5), p=0.013), and lower rates of globe salvage (100% vs. 58% of eyes [IAC vs. IVC], p=0.016).

Discussion: Prior studies have compared success rates for patients undergoing IVC and those undergoing IAC. However, in selecting therapy, likelihood of treatment success, expected adverse events, and treatment burden must be considered. This study provides evidence regarding adverse events and burden associated with each treatment modality.

Conclusion: Treatment success is greater with IAC. IVC is associated with more adverse events and greater treatment burden.

References: 1. Abramson DH, Daniels AB, Marr BP, et al. Intra-Arterial Chemotherapy (Ophthalmic Artery Chemosurgery) for Group D Retinoblastoma. Plos One. 2016;11(1). doi:10.1371/journal.pone.0146582.

Paper #9
Thursday, 11:59 am – 12:06 pm

Determining the Tractional Forces on Vitreoretinal Interface Using Computer Simulation and Animal Models to Elucidate the Retinal Hemorrhage Patterns in Abusive Head Trauma

Donny W. Suh, MD

University of Nebraska Medical Center
Omaha, NE

Introduction: Pathophysiology of the retinal findings in abusive head trauma (AHT) is not clearly understood, but the role of vitreoretinal traction has been hypothesized. Combining computer simulation (CS) and animal models, we test the hypothesis that vitreo-retinal traction during forcible shaking can exceed the vitreo-retinal adhesion.

Methods: CS model of pediatric eye was developed to determine stresses on various layers of retina and its vessels during shaking. To provide empirical context surrounding the computationally predicted stresses, young sheep eyes (n=7) were harvested at 6 months of age. A 5x5 mm sclerotomy was created, and the underlying retina exposed. Polytetrafluoroethylene patch was attached to the subretinal surface and then pulled to measure the stress required to create vitreoretinal separation.

Results: Stress values from the CS ranged from 3-16 kilopascal (kPa). Maximal stress was observed at the peripheral retina, retinal vessel bifurcations, and the posterior pole. Stress values were similar in preretinal, intraretinal, and subretinal layers. Stresses predicted by the computer simulations exceeded those measured in the ex vivo animal eye model, which showed stress values of 2-5 kPa.

Discussion: Ocular manifestations from abusive head trauma reveal unique retinal characteristics. Our model predicted stress patterns consistent with the diffuse retinal hemorrhages (RH) typically found in the posterior pole and around the peripheral retina in AHT. Our computer model demonstrated that similar stress forces were produced in different layers of the retina, consistent with the finding that retinal hemorrhages are often found in multiple layers of the retina. The computer model predicted that intraocular forces attained during forcible shaking of an eye can exceed the minimum threshold needed to produce vitreoretinal separation as measured in ex vivo sheep eyes. These data also support the theory that vitreous traction at the retinal surface is an important contributor to retinal hemorrhages and retinoschisis in AHT.

Conclusion: CS demonstrated that similar stress forces were produced in all three layers of the retina, consistent with the clinical findings that pan-retinal hemorrhages. Also, CS demonstrated that forces generated during shaking can potentially exceed the minimum threshold needed to produce vitreoretinal separation as measured in ex vivo sheep eyes. Our data support the theory that vitreous traction at the retinal surface may be an important contributing factor to retinal findings in AHT.

References: 1. Hedlund, Gary L. Subdural Hemorrhage in Abusive Head Trauma: Imaging Challenges and Controversies. J. Am. Osteopath. Coll. Radiol. 1, 23-30 (2012).
2. Binenbaum, G., Mirza-George, N., Christian, C. W. & Forbes, B. J. Odds of abuse associated with retinal hemorrhages in children suspected of child abuse. J. AAPOS Off. Publ. Am. Assoc. Pediatr. Ophthalmol. Strabismus 13, 268-272 (2009).
3. Schroeder, Lauryn. Hot Spots - Pinpointing Shaken Baby Syndrome Cases Medill Justice Project. Available at: http://www.medilljusticeproject.org/2013/12/10/hot-spots/. (Accessed: 16th January 2018)

Paper #10
Thursday, 12:10 pm – 12:17 pm

Diagnosis of Inherited Retinal Degenerations in Pediatric Patients using the RETeval Handheld Electroretinogram

Cole J. Swiston; Melanie A. Schmitt, MD; James N. Ver Hoeve, PhD

University of Wisconsin Department of Ophthalmology and Visual Sciences
Madison, Wisconsin

Introduction: To investigate practicality and utility of the RETeval handheld electroretinogram (ERG) in the diagnosis of inherited retinal degenerations (IRD) in pediatric patients.

Methods: Electronic medical records of pediatric patients who received RETeval ERG testing at our institution were searched for patient demographic information, ophthalmic diagnoses, ocular exam data, and ERG results. Patients were stratified based on ophthalmic diagnosis and the presence of abnormal RETeval photopic and/or scotopic waveforms.

Results: In total, 64 pediatric patients with an average age of 6.7 years (median 5.63 years, range 2.86 months - 16.9 years) received 71 RETeval ERG's. 68 (96%) were performed without sedation. Among 21 patients with IRD's (seven genetically confirmed, 11 clinically diagnosed, and three suspicious retinal dystrophies), 18 (86%) had abnormal photopic waveforms. Of the three normal photopic results, two were in the suspicious category, and one had a known rod-cone dystrophy. 20 patients presumed to have an IRD based on clinical findings completed dark adapted testing, and 100% had abnormal scotopic waveforms.

Discussion: Our results show that the RETeval handheld ERG is a practical and accurate tool for early diagnosis of pediatric IRD's, often avoiding the need for sedation and operating room time with conventional corneal electrode ERG testing.

Conclusion: To our knowledge, this is the first study investigating both scotopic and photopic responses obtained with the handheld RETeval ERG in a cohort of pediatric IRD patients. This device is especially useful in younger children and may allow for widespread use of ERG's outside the tertiary care setting.

References:

Paper #11
Thursday, 12:17 pm – 12:24 pm

How Long Does Gene Therapy Last? 4 Year Follow-Up of Phase 3 Voretigene Neparvovec Trial in RPE65-Associated LCA/Inherited Retinal Disease

Arlene V. Drack, MD; Jean Bennett, MD; Stephen Russell, MD; Katherine A. High, MD; Zi-fan Yu, ScD; Amy Tillman, MS; Daniel Chung, DO; Kathleen Z. Reape, MD; Thomas Ciulla; Albert Maguire

University of Iowa
Iowa City, IA

Introduction: Voretigene neparvovec (VN) gene therapy improves ambulatory navigation, light sensitivity, and visual field in subjects with RPE65-associated Leber Congenital Amaurosis /Inherited Retinal Disease.1 We report Year 4 results for original intervention (OI) subjects, Year 3 for delayed intervention (DI), and Y1 results for all subjects stratified by age < 10, 11-17 or > 18 years at treatment for the primary endpoint.

Methods: Subjects were randomized to either original intervention (OI:bilateral subretinal VN at baseline) or delayed intervention (DI:VN after 1 year). Primary endpoint was change in bilateral performance on the Multi-Luminance Mobility Test (MLMT).

Results: There were no significant differences in MLMT between subjects aged </=10 (n=13), 11–17 (n=7), and >/=18 years (n=9) at Year 1. Mean changes in MLMT at Year 1 were maintained at Year 4 for OI and Year 3 for DI (1.7 and 2.4 light levels, respectively). At Year 4, five/twenty OI subjects (ages at treatment 4, 6, 11, 11 and 34 years) showed a decrease of one light level. Three of the five remained stable compared to Year 2 or 3. No subject declined below baseline, and 1/20 (age at treatment 16 years) gained a light level.. One subject had a retinal detachment detected at Year 4.

Discussion: Amblyopia may not be a major hindrance to gene therapy treatment but loss of photoreceptors in a progressive disease may affect outcome.

Conclusion: Functional vision is stable in 24 of 28 (86%) patients from one year post-treatment through 3-4 years of follow-up.

References: 1.Russell S, Bennett J, Wellman JA, et al. Efficacy and safety of voretigene neparvovec (AAV2-hRPE65v2) in patients with RPE65-mediated inherited retinal dystrophy: a randomised, controlled, open-label, phase 3 trial. Lancet. 2017;390(10097):849-860.

Paper #12
Thursday, 12:24 pm – 12:31 pm

Diagnosis of Congenital Special Forms of Strabismus Based on High-Throughput Sequencing and High-Resolution MRI

Yonghong Jiao; Hongyan Jia; Yi Liang; Yulan Liang; Qinglin Chang; Hui Wang

Beijing Tongren Hospital
Beijing China

Introduction: Congenital special forms of strabismus (CSS) are a group of clinically and genetically heterogeneous diseases, which are considered to be neuropathic or myopathic. We aim to establish an effective diagnosis workflow for CSS by utilizing and combining exonic sequencing and MRI.

Methods: 61 families with CSS were enrolled in the study. 22 were familial and 39 were sporadic. All patients underwent comprehensive ophthalmic examinations and MRI. 115 candidate genes have been captured and sequenced, which may be associated with congenital cranial dysinnervation disorder (CCDDs), congenital ptosis, ophthalmoplegia, congenital myopathy and congenital muscular dystrophies (CMD). After excluding mutations in the 115 candidate genes in 22 probands, we conducted Whole-Exome Sequencing (WES).

Results: MRI examinations of 61 patients showed marked hypoplasia cranial nerve and/or extraocular muscles. 9 mutations in 5 genes (KIF21A, 45.9%; TUBB3, 13.2%; POMGNT1, 1.6%; RYR1, 1.6%; CHN1, 1.6%) from 39 patients (63.9%) were identified. Out of 39 patients, 27 were diagnosed with congenital fibrosis of extraocular muscles (CFEOM), 2 patients were diagnosed with muscle-eye-brain disease (MEB), 2 patients diagnosed with familial Duane syndrome and 1 patient diagnosed with CMD. 4 patients with potentially pathogenic variants were identified with WES.

Discussion: Since CSS usually have overlapping clinical features, accurate diagnosis of CSS-related diseases is challenging. Combining MRI with exonic sequencing, the diagnosis rate could increase effectively.

Conclusion: We established a high sensitivity and specificity diagnosis workflow for CSS, based on MRI and targeted exonic sequencing, which could be a rapid, cost-efficient diagnostic option for clinicians to utilize.

References: 1.Demer JL, Ortube MC, Engle EC, Thacker N. High-resolution magnetic resonance imaging demonstrates abnormalities of motor nerves and extraocular muscles in patients with neuropathic strabismus. J Aapos. 2006;10(2):135-42
2.Graeber CP, Hunter DG, Engle EC. The Genetic Basis of Incomitant Strabismus: Consolidation of the Current Knowledge of the Genetic Foundations of Disease. Semin Ophthalmol. 2013;28(5-6):427-437
3.Kunii M, Doi H, Ishii Y et al. Genetic analysis of adult leukoencephalopathy patients using a custom-designed gene panel. Clin Genet. 2018;94(2):232-238

Paper #13
Thursday, 12:31 pm – 12:38 pm

Evaluation of a Computer-Based Facial Dysmorphology Analysis Algorithm (Face2Gene) using Standardized Textbook Photos

Ta C. Chang; Alana L. Grajewski; Elizabeth A. Vanner

Bascom Palmer Eye Institute
Miami, FL

Introduction: Face2Gene (F2G) is a smart-phone based computerized facial dysmorphology analysis program that analyzes facial images to provide differential diagnoses of possible syndromes. In this study, we tested the sensitivity and specificity of F2G using the images within two standard genetic textbooks.

Methods: Under standard lighting conditions, all facial images contained with the two textbooks were analyzed using F2G. Variables captured include color vs black/white photo, gender of the patient (if known), age of the patient (if known), disease categories, diagnosis as listed in the textbook, and whether the disease has ophthalmic involvement (as described in the textbook entries).

Results: A total of 353 facial images were analyzed. The top F2G diagnosis matched the book diagnosis in 150 (42.5%) entries, while it is included in the top three in 191 (54.1%) entries. 259 entries had ophthalmic involvement, and within this subgroup, the top F2G diagnosis matched the book diagnosis in 108 (49.4%) entries, while it is included in the top three in 140 (54.1%) entries. F2G is highly sensitive for craniosynostosis syndromes (point estimate [PE] 80.0%, 95% confidence interval [CI] 56.3 - 94.3%, P = 0.0118) and syndrome with facial defects as major feature (PE 77.8%, 95% CI 52.4 - 93.6%, P = 0.0309). F2G is highly specific for all categories (PE > 90% with P < 0.05 for all).

Discussion: F2G is a highly specific tool for facial dysmorphology in all categories.

Conclusion: F2G may be a useful tool for pediatric ophthalmologists to rule out certain syndromes when evaluating a child with dysmorphic facial features.

References: Jones, Kenneth Lyons, Marilyn C. Jones, Miguel del Campo, and David W. Smith. Smith's Recognizable Patterns of Human Malformation. Seventh edition. Philadelphia, Pa.: Elsevier Saunders, 2013.
Traboulsi EI. Ed. Genetic Diseases of the Eye. Second edition. New York, NY.: Oxford University Press, 2012.
Vorravanpreecha N, Lertboonnum T, Rodjanadit R, Sriplienchan P, Rojnueangnit K. Studying Down syndrome recognition probabilities in Thai children with de-identified computer-aided facial analysis. Am J Med Genet A. 2018 Aug 2. doi: 10.1002/ajmg.a.40483. [Epub ahead of print]

Paper #14
Thursday, 12:38 pm – 12:45 pm

Incidence of Symptomatic Torsional and Vertical Diplopia after Superior Rectus Transposition for Esotropic Duane Syndrome and 6th Nerve Palsy

Anna G. Escuder, MD; Melanie A. Kazlas, MD; Gena Heidary, MD, PhD; David G. Hunter, MD, PhD; Linda R. Dagi, MD

Boston Children's Hospital, Department of Pediatric Ophthalmology
Boston, MA

Introduction: To describe the incidence of symptomatic vertical and torsional strabismus after superior rectus transposition (SRT) for esotropic Duane syndrome (DS) and 6th nerve palsy

Methods: Retrospective chart review of pre- and post-operative sensorimotor exams on patients with 6th nerve palsy or esotropic DS treated with SRT with or without medial rectus recession (2000-2018). Patients with bilateral SRT, or treatment with additional rectus or oblique surgery were excluded.

Results: 66 patients met inclusion criteria, including 32 patients with sixth nerve palsy and 34 patients with DS. Average follow up was 2.4 years and age at surgery, 22.8 years. Average pre-operative esotropia was 42 PD (95% CI 38.5- 46.2) and post-operative was 10.2 PD (95% CI 7.76-12.7). Average pre- and post-operative vertical deviation in primary gaze was 1.78PD (95% CI 0.95-2.62) and 2.62PD (95% CI 1.48-3.63), respectively. Abduction enhancement was performed with SR-LR loop myopexy in 47 and scleral-fixated myopexy in 7 patients. Symptomatic vertical diplopia occurred in 4 of 47 treated with loop myopexy and in 1 of 7 with scleral-fixated. None of the 66 patients developed symptomatic torsion.

Discussion: Superior rectus transposition has been advocated as an alternative to balanced vertical rectus transposition. In this largest-to-date retrospective review, 7.5% of patients developed symptomatic vertical diplopia and none developed symptomatic torsional diplopia.

Conclusion: Superior rectus transposition with or without medial rectus recession provides a muscle-sparing alternative to balanced vertical rectus transposition with similar rates of induced vertical and torsional diplopia.

References:
- Velez FG, Oltra E, Isenberg S, Pineles S. Assessment of torsion after superior rectus transposition with our without medial rectus recession for Duane syndrome and abducens nerve palsy. J AAPOS. 2014 Oct; 18(5):457-460.
- Mehendale RA, Dagi LR, Wu C, Ledoux D, Johnston S, Hunter DG. Superior rectus transposition and medial rectus recession for Duane syndrome and sixth nerve palsy. Arch Ophthalmology. 2012 Feb; 130 (2): 195-201.
- Ruth AL, Velez FG, Rosenbaum AL. Management of vertical deviations after vertical rectus transposition surgery, J AAPOS. 2009 Feb; 13 (1): 16-9.

Paper #15
Saturday, 8:02 am – 8:12 am

Young Investigator Award Paper

The Functional Impact of Strabismus

Stacy L. Pineles, MD, MS

Introduction: Despite strabismus being common, little is known about its effect on functional vision and associated systemic morbidity in children. Common pediatric eye diseases often have a negative effect on children's depth perception, visual field, and binocular summation but it is unclear how this affects a child's ability to function.

Methods: Review of studies related to the functional impact of strabismus on children.

Results: Strabismus in children significantly diminishes stereopsis and binocular summation, while increasing binocular inhibition, which has been associated with a decrease in patient quality of life. In most cases, strabismus surgery improves binocular summation in children. However, in some cases such as infantile esotropia, binocular summation does not improve. Although there are no published studies in pediatric patients, claims data in adults reveals that the presence of strabismus increases the risk of fractures, falls and musculoskeletal injuries by 27%. This increased risk is presumably due to the functional limitations induced by strabismus. Data from our ongoing studies on the risk of injuries in children with strabismus will be presented.

Discussion: Binocular summation is significantly decreased in children with strabismus. This impact, combined with other functional and psychosocial effects, lead to diminished scores in quality of life. In addition, there is evidence in adults that the functional impact of strabismus leads to an increased risk of injuries. It is not clear how strabismus affects a child's risk of physical injuries.

Conclusions: Continued claims-based studies will focus on the risk of physical injuries in children with various eye diseases. We will also evaluate the effect of strabismus surgery on the risk of physical injuries.

Paper #16
Saturday, 8:13 am – 8:20 am

Validation of the G-ROP Modified Retinopathy of Prematurity Screening Criteria

Gil Binenbaum; Lauren A. Tomlinson; Alejandra de Alba Campomanes; Edward Bell; Pamela Donohue; David Morrison; Graham Quinn; Michael X. Repka; David Rogers; Michael Yang; Yinxi Yu; Gui-shuang Yang

The Children's Hospital of Philadelphia
Philadelphia, PA

Introduction: The Postnatal Growth and ROP Study (G-ROP-1) developed modified screening criteria with 100% sensitivity for ETROP Type-1 ROP and 30% reduction of infants requiring examinations in a retrospective development cohort of 7,483 infants from 29 North American hospitals in 2006-2012. Infants meeting one or more criteria undergo examinations: GA<28wks; or BW<1051g; or weight gain<120g, <180g, or <170g during ages 10-19, 20-29, or 30-39 days, respectively; or hydrocephalus. We evaluated the generalizability of the G-ROP screening criteria in a new cohort of at-risk infants.

Methods: We conducted a prospective validation study (G-ROP-2) of infants examined at 41 North-American hospitals (25 G-ROP-1 hospitals, 16 new hospitals) in 2015-2017. Primary outcomes were sensitivity of G-ROP criteria for Type-1 ROP and reduction in infants meeting criteria to receive examinations.

Results: 3,980 infants were studied (median BW-1072g (range 350-2190), GA-28wks (22-38)). In this new cohort, the G-ROP criteria correctly predicted 219/219 Type-1 (sensitivity 100%; 95%CI--98.3%-100%) and 253/256 treated cases, reducing infants undergoing screening by 36%(95%CI--34%-37%). In a combined G-ROP-1/G-ROP-2 cohort of 11,463 infants, the criteria predicted 677/677 Type-1(100%; 99.4%-100%) and 767/770 treated cases, reducing infants meeting criteria by 33%(32%-34%); while current criteria (BW<1501g or GA</=30-weeks-0-days without subjective 'poor-postnatal-course' criterion) predicted 674/677 Type-1(99.6%; 98.7-99.8%) and 766/770 treated cases.

Discussion: These large cohorts provide evidence-based screening criteria that have higher sensitivity and specificity (less infants receive examinations) for Type-1 ROP than currently recommended guidelines.

Conclusion: The G-ROP modified screening criteria were generalizable upon validation and could be used clinically to greatly reduce the number of infants requiring examinations.

References: 1. Binenbaum G, Tomlinson L, on behalf of the G-ROP Study Group: Postnatal Growth and Retinopathy of Prematurity Study: Rationale, Design, and Subject Characteristics. Ophthalm Epidem 24(1): 36-47, Feb 2017.
2. Binenbaum G, Bell EF, Donohue P, Quinn G, Shaffer J, Tomlinson LA, Ying GS; on behalf of the G-ROP Study Group. Development of Modified Screening Criteria for Retinopathy of Prematurity: Primary Results From the Postnatal Growth and Retinopathy of Prematurity Study. JAMA Ophthalmol. 2018 Sep 1;136(9):1034-1040.

Paper #17
Saturday, 8:20 am – 8:27 am

Punctate Hyperreflective Vitreous Opacities Visualized by Handheld Spectral Domain Optical Coherence Tomography in Premature Infants Screened for Retinopathy of Prematurity

Emily M. Zepeda, MD; Thomas B. Gillette, MD; Ayesha Shariff, MD; Laura Grant, MD; Leona Ding, MS; Kristina Tarczy-Hornoch, MD; Michelle T. Cabrera, MD

University of Washington
Seattle, Washington USA

Introduction: Vitreous changes in retinopathy of prematurity (ROP) are poorly understood. The goal of this study was to characterize punctate hyperreflective vitreous opacities seen on handheld spectral domain optical coherence tomography (SD-OCT).

Methods: This is a prospective observational study of infants requiring ROP screening between July 2015 and December 2017. Infants were imaged using handheld SD-OCT at the time of routine examinations. Trained graders masked to the clinical assessment analyzed each OCT scan of the right eye for vitreoretinal findings. Disagreement was mediated by a third trained grader. Punctate hyperreflective vitreous opacities seen on OCT were correlated with clinical ROP severity and other OCT vitreoretinal pathologies.

Results: Among 93 infants studied (51% male, mean gestational age 28.3+/-2.9 weeks, mean birthweight 1008.2 kg+/-287.8 grams), 22/93 (38%) developed ROP (14/93 (15%) Stage 3). Agreement for OCT graders was 91% (kappa=0.8, $p<0.001$). Punctate hyperreflective vitreous opacities developed in 31/93 (33%) of infants and were associated with the presence of ROP ($p=0.005$), maximum ROP stage ($p=0.005$), and pre-plus or plus disease ($p=0.002$).

Discussion: Punctate hyperreflective vitreous opacities seen on handheld SD-OCT were strongly correlated with presence of ROP, maximum stage, and pre-plus or plus disease among premature infants screened for ROP. The opacities may represent cellular proliferation, protein or hemoglobin associated with advanced ROP.

Conclusion: Punctate hyperreflective vitreous opacities on OCT are a marker for advanced ROP. Further study should explore handheld SD-OCT as a non-invasive ROP screening tool.

References: 1. Dubis AM, Subramaniam CD, Godara P, Carroll J, Costakos DM. Subclinical macular findings in infants screened for retinopathy of prematurity with spectral-domain optical coherence tomography. Ophthalmology. 2013;120(8):1665-1671.
2. Zepeda EM, Shariff A, Gillette TB, et al. Vitreous Bands Identified by Handheld Spectral-Domain Optical Coherence Tomography Among Premature Infants. JAMA Ophthalmol. 2018;136(7):753-758.
3. Sun Y, Dalal R, Gariano RF. Cellular Composition of the Ridge in Retinopathy of Prematurity. Archives of Ophthalmology. 2010; 128(5): 638-641.

Paper #18
Saturday, 8:27 am – 8:34 am

Deep Learning for Monitoring ROP Progression

Kishan Gupta, MD, PhD; Stanford Taylor, MD; J. Peter Campbell, MD, MPH; Jayashree Kalpathy-Cramer,PhD; James M. Brown, PhD; R.V.Paul Chan, MD; Sang J. Kim, PhD; Michael F. Chiang, MD

Introduction: To evaluate the clinical utility of quantitative image analysis using a deep learning plus disease severity score to monitor disease progression and response to treatment in patients with retinopathy of prematurity (ROP).

Methods: Images from clinical exams performed between July 2011 and December 2016 of infants in the multicenter Imaging and Informatics in ROP study were reviewed to identify babies with treatment-requiring disease, and scored by an automated deep learning algorithm with from 1 (normal retinal vasculature) to 9 (severe plus disease). Severity scores for treated and untreated eyes were compared longitudinally. The 4-week pre- and post-treatment scores with either laser or anti-vascular endothelial growth factor (anti-VEGF) were assessed.

Results: A total of 1692 eyes were analyzed. 91 eyes progressed to treatment-requiring disease. Mean severity scores of the two groups significantly differed at all time-points analyzed but became more apparent with advancing post-menstrual age (PMA). At 36-38 weeks PMA, mean score for treatment-requiring disease was 5.2 compared to 1.2 in untreated eyes ($p<0.01$). 47 eyes received laser (n=39) or anti-VEGF therapy (n=8). The mean severity score 2 weeks pre-treatment (4.2) and post-treatment (4.0) significantly differed from treatment time (7.4, $p<0.0001$ for each).

Discussion: The ROP severity score correlates with clinical progression and response to treatment. The score was an independent predictor of progression to treatment-requiring disease. The score at time of treatment was an independent predictor of disease recurrence.

Conclusion: Automated computer-based image analysis may be considered as a means to monitor disease progression and treatment response in infants undergoing screening for ROP.

References:

Paper #19
Saturday, 8:34 am – 8:41 am

Short- and Long-Term Effects of Aflibercept on Retinal Vascular Development in the Oxygen-Induced Retinopathy Mouse Model of Retinopathy of Prematurity

Sarina M. Amin, MD; Jade Guevara, MD; Andres Gonzalez, MD; Wesley C. Smith, PhD

University of Florida
Gainesville, Florida

Introduction: The goal of this study was to assess the effect of aflibercept on retinal vasculature and determine potential long-term detrimental effects in the oxygen-induced retinopathy mouse model.

Methods: 81 mouse eyes were randomly assigned to a room air control (n=21) or hyperoxia with 75% oxygen (n=60). The hyperoxia eyes were divided into three groups: 0 ng (n=13), 100 ng (n=25), or 1000ng (n=22) of aflibercept. Intravitreal aflibercept injections were administered on day 14 of life. The eyes were assigned to be enucleated 3 days (P17) or 11 days (P25) post-injection. Stained flat mount retina preparations were processed and areas of perfusion and nonperfusion were quantified using Image J software. The ratios of nonperfused area of the hyperoxic groups to perfused area of the control groups were determined and a two-sample test was performed.

Results: Only the P25 hyperoxic control eyes had a statistically significant larger ratio of nonperfusion compared to the 1000ng eyes ($p<0.05$); however, there was no significant difference between the P17 groups in terms of nonperfusion. There was a statistically significant decrease ($p<0.05$) in the ratio of nonperfusion for the 1000ng treatment dose in the P25 group compared to the P17 group.

Discussion: These results suggest that the effect of aflibercept dissipates between P17 and P25, and that normal retinal vasculature is not completely inhibited at the 1000ng dose by P25.

Conclusion: This study highlights the efficacy of aflibercept in the mouse model of ROP. It also ascertains that aflibercept does not inhibit the development of normal retina long-term.

References: 1. Tokunaga CC et al. Effects of anti-VEGF treatment on the recovery of the developing retina following oxygen-induced retinopathy. IOVS. 2014;55(3):1884-1892.
2. Lutty GA et al. Effect of VEGF Trap on normal retinal vascular development and oxygen-induced retinopathy in the dog. IOVS. 2011;52(7):4039-4047.

Paper #20
Saturday, 8:41 am – 8:48 am

Can Fluorescein Angiography Retinal Findings Predict the Late-Onset Risk of Recurrence Post Intravitreal Bevacizumab for ROP?

Swati Agarwal-Sinha, MD; Andres Gonzalez, MD

University of Florida
Gainesville, Florida

Introduction: Fluorescein angiography (FA) use has documented retinal vascular changes in eyes treated with Intravitreal bevacizumab (IVB) for retinopathy of prematurity (ROP). We studied the retinal vasculature post IVB with FA and assessed features imposing risk for sight threatening complications.

Methods: Retrospective study of 25 infants treated with IVB between 7/2014 to 08/2018 was performed.

Results: 25 infants had Retcam and FA performed at an average 68 weeks PMA. Of these,19 infants had second FA at an average 98 weeks PMA and 10 infants had third FA at an average 120 weeks PMA. Average GA and BW was 24.7 weeks and 675 grams respectively. Average PMA at first IVB treatment was 37.1 weeks. 8 eyes of 6 infants received repeat IVB for recurrent stage 3 at an average 46.6 weeks. The average number of IVB treatments was 2. All 25 infants continued to show inhibited retinal vasculature in zone 2. 22 of 25 infants had or conventional FA features which included avascular retina, peripheral leakage, shunts, abnormal vessels branching and tangles. Three infants showed unconventional FA findings; significant posterior vascular tortuosity, extreme peripheral vascular branching, diffuse hyperfluorescence at the regressed proliferation site. Of the three infants only one had late tractional proliferation at 92 weeks PMA which was treated with barrier laser

Discussion: Unconventional FA features post-IVB may need close long-term follow-up for early detection of sight-threatening complications.

Conclusion: FA features can categorize infants as low and high-risk which would be beneficial in redefining the ROP follow-up guidelines post-IVB treatment.

References: 1. Lepore D, Quinn GE, Molle F, Baldascino A, Orazi L, Sammartino M, Purcaro V, Giannantonio C, Papacci P, Romagnoli C. Intravitreal bevacizumab versus laser treatment in type 1 retinopathy of prematurity: report on fluorescein angiographic findings. Ophthalmology. 2014 Nov;121:2212-9.
2. Hajrasouliha AR, Garcia-Gonzales JM, Shapiro MJ, Yoon H, Blair MP. Reactivation of Retinopathy of Prematurity Three Years After Treatment With Bevacizumab. Ophthalmic Surg Lasers Imaging Retina. 2017;48:255-259.
3. Agarwal-Sinha S, Gieseke Guevara J, Amin S. Late onset tractional fibrovascular proliferation post intravitreal bevacizumab following treatment of retinopathy of prematurity. Can J Ophthalmol. 2018;53:e99-e103.

Paper #21
Saturday, 8:48 am – 8:55 am

Comparison of Hand-Held Spectral Domain Optical Coherence Tomography (HH-SDOCT) findings in Non-Accidental Injury (NAI) and non-NAI

Bhamy Hariprasad Shenoy, MBBS, MS, FICO, FRCOphth; Vinod Sharma, MBBS, MS, DNB, FRCSEd, FRCOphth; William Newman, MB,BS,FRCS (Glasg), FRCOphth, LL.M (Medical Law); Jane Ashworth, BMCh, FRCOphth, PhD; Susmito Biswas, BSc Hons, MBBS, FRCOphth

Manchester Royal Eye Hospital
Manchester, United Kingdom

Introduction: We previously reported the utility of HH-SDOCT in identifying characteristic and unique vitreoretinal abnormalities not detected on clinical examination in children with NAI. The aim of this study was to compare HH-SDOCT findings in retinal haemorrhages of NAI and non-NAI and evaluate their usefulness in differentiating NAI from non-NAI.

Methods: Retrospective comparative study of HH-SDOCT findings in children with confirmed diagnosis of NAI and children with retinal hemorrhages due to non-NAI. All the children underwent complete ophthalmic evaluation in addition to the HH-SDOCT imaging.

Results: A total of 10 children with retinal findings due to child protection multidisciplinary confirmed NAI and 4 children with retinal hemorrhages due to non-NAI causes were included in the study. All children with NAI induced retinal hemorrhages showed evidence multi-layered retinoschisis and multi-layered retinal haemorrhages. None of the eyes with retinal hemorrhage due to non-NAI causes demonstrated vitreo-retinal interface changes or inner retinal schitic changes.

Discussion: This HH-SDOCT study represents the largest consecutive NAI series reported to date. It demonstrates that the HH-SDOCT identifies characteristic retinal findings associated with NAI cases which may not be seen in non-NAI cases and are usually not evident using routine examination techniques and imaging. These findings add further evidence that could potentially help distinguish between lesions secondary to NAI from non-NAI causes.

Conclusion: HH-SDOCT helps in identifying characteristic retinal findings associated with NAI which may not be may not be seen in retinal hemorrhages due to non-NAI. Future studies with larger sample is needed to validate this finding.

References: 1.Muni RH, Kohly RP, Sohn EH, Lee TC. Hand-held spectral domain optical coherence tomography finding in shaken-baby syndrome. Retina 2010;30:45-50
2.Scott AW, Farsiu S, Enyedi LB, Wallace DK, Toth CA. Imaging the infant retina with a hand-held spectral-domain optical coherence tomography device. Am J Ophthalmol 2009;147:364-37
3.Sturm V, Landau K, Menke MN. Optical coherence tomography findings in Shaken Baby syndrome. Am J Ophthalmol 2008;146:363-8

Paper #22
Saturday, 8:55 am – 9:02 am

A Prospective Observational Study of Adult Divergence Insufficiency Esotropia

Eric R. Crouch, MD; Trevano W. Dean, MPH; Jonathan M. Holmes, MD; Raymond T. Kraker, MSPH; Aaron M. Miller, MD; Courtney Kraus, MD; Kammi B. Gunton, MD; Michael X. Repka, MD, MBA; Justin D. Marsh, MD; Monte A. Del Monte, MD; Paula A. Luke, OD; Jason H. Peragallo, MD; David K. Wallace, MD, MPH

Pediatric Eye Disease Investigator Group
Jaeb Center for Health Research, Tampa, Florida

Introduction: This study was designed to assess treatment outcomes for adult onset divergence insufficiency distance esotropia.

Methods: In a non-randomized observational study, we prospectively enrolled adults with divergence insufficiency (defined as distance esodeviation of 2-30PD at least 1.25 times larger than near esodeviation by prism and alternate cover test, and distance diplopia with frequency of 'sometimes', 'often' or 'always' in primary gaze by diplopia questionnaire.),1-3 Participants were enrolled when a new treatment was being initiated (either prism, orthoptic exercises, or surgery). The primary 12-month outcome was 'symptom success' defined as diplopia 'rarely' or 'never' straight ahead in the distance.

Results: One-hundred-fourteen participants were enrolled and initiated treatment: surgery (n=76, 67%), prism (n=34, 30%), or exercises (n=4, 4%). Prior treatment was reported primarily in the surgery group (n=61, 80%). Success criteria were met for 55 (89%, 95% CI=78% to 95%) with surgery and 17 (65%, 95% CI=44% to 83%) with prism. Success rates were high for both major types of surgery [Bilateral medial rectus recession: 32 (91%) of 35 and Bilateral lateral rectus resection: 10 (91%) of 11].

Discussion: Although success rates cannot be compared directly in this non-randomized study because there were important differences in baseline characteristics, success was common.

Conclusion: When assessed 12 months after initiating treatment, strabismus surgery or prism often successfully improves symptoms in divergence insufficiency. These data may be useful for counseling patients and for future RCTs.

References: 1. Holmes, JM, et al. Quantifying diplopia with a questionnaire. Ophthalmology. 2013; 120(7): 1492-1496.
2. Martinez-Thompson JM, Diehl NN, Holmes JM, Mohney BG. Incidence, types, and lifetime risk of adult-onset strabismus. Ophthalmology. 2014 Apr; 121(4):877-82.
3. Tamhankar MA, Ying GS, Volpe NJ. Effectiveness of prisms in the management of diplopia in patients due to diverse etiologies. J Pediatr Ophthalmol Strabismus. 2012 Jul-Aug;49(4):222-8

Paper #23
Saturday, 9:02 am – 9:09 am

The Medial Rectus is the Bad Actor in Intermittent Esotropia

Joseph L. Demer, MD, PhD; Robert A. Clark, MD

University of California, Los Angeles
Los Angeles, California

Introduction: Fusional convergence controls exophoria, but failure of fusional divergence in esodeviations has been enigmatic. Magnetic resonance imaging (MRI) can clarify muscle function during divergence.

Methods: Orbital MRI was performed during binocular fusion of centered targets. Nine orthophoric controls fused monocular 4PD base-in prism at 400cm and 10 fused 8PD base-in at 20cm. Four patients fused acquired, intermittent esotropia averaging 24±4PD. Changes in compartmental posterior partial volumes of the horizontal rectus muscles quantified contractility.

Results: In patients and controls, both diverging lateral rectus (LR) compartments contracted symmetrically for near and distant targets, although contractility was much larger in patients ($P<0.002$). At near in controls, only the diverging medial rectus (MR) superior compartment relaxed, while the inferior compartment remained contracted ($P<0.03$). The normal MR did not relax during far divergence. At near in patients, the MR superior relaxed significantly more than the inferior compartment ($P=0.005$). For near targets, MR and LR co-relaxed in the aligned eye in both patients and controls.

Discussion: The diverging MR inferior compartment co-contracts against the LR, resisting fusional divergence at near, and the entire MR fails to relax as much as the LR contracts for far targets. The MR and LR co-relax in the aligned eye when its fellow diverges to fuse intermittent esotropia.

Conclusion: The inferior compartment of the MR actively opposes fusional divergence in intermittent esotropia, not reciprocating the LR. Poorer MR relaxation accounts for lower fusional divergence for far than near targets. Selective weakening of the inferior MR compartment may treat acquired intermittent esotropia.

References: Demer, J. L. and Clark, R. A. Functional anatomy of human extraocular muscles during fusional divergence. J. Neurophysiol. 2018 Sep 19. doi: 10.1152/jn.00485.2018.

Paper #24
Saturday, 9:09 am – 9:16 am

High Prevalence of Sagging Eye Syndrome in Adults with Binocular Diplopia

Toshiaki T. Goseki, MD, PhD; Suh Soh Youn, MD; Laura Robbins, OD; Stacy L. Pineles, MD; Federico G. Velez, MD; Joseph L. Demer, MD, PhD

Pediatric Ophthalmology and Adult Strabismus division, Stein Eye Institute, David Geffen School of Medicine, UCLA
100 Stein Plaza Driveway, Los Angeles, CA 90095

Introduction: Sagging eye syndrome (SES), horizontal and/or vertical strabismus caused by orbital connective tissue degeneration, was first defined 10 years ago. While SES is increasingly recognized as a cause of acquired diplopia, its prevalence is unknown. We investigated SES prevalence in diplopic adults.

Methods: We reviewed all new adults over age 40 years, presenting to the UCLA strabismus division with binocular diplopia between August 2017 and September 2018. Age, gender, and type of strabismus were analyzed.

Results: We reviewed 208 total patients of mean (± SD) age 67±11 (range, 40-91) years of whom 113 (54%) were female. The most common cause of diplopia was SES (28.8%), followed by exotropia (10.1%), thyroid ophthalmopathy (8.2%), trochlear palsy (8.2%), abducens palsy (7.7%), decompensated esophoria (4.8%), orbital trauma (3.4%), scleral buckling (2.9%), and skew deviation (2.4%). The 63 patients with SES were older at 71±9 years (range, 52-91 years, $p<0.0001$) and more predominantly female at 63% than other patients (49%, $p=0.02$). SES caused 15% of all diplopia in patients from ages 50-59 years, 33% from ages 60-69 years, 37% from ages 70-79 years, and 33% over age 79 years, but no diplopia under age 50 years.

Discussion: SES is the most common cause of acquired binocular diplopia in adults over 50 years old, comprising about 30% of all cases, easily surpassing cranial neuropathies and thyroid eye disease. However, SES was not encountered in patients under age 50 years.

Conclusion: It is important to recognize that SES is a very common cause of adult binocular diplopia.

References: 1. Rutar T, Demer JL. 'Heavy Eye' syndrome in the absence of high myopia: A connective tissue degeneration in elderly strabismic patients. J AAPOS 2009;13:36-44.
2. Chaudhuri Z, Demer JL. Sagging eye syndrome: connective tissue involution as a cause of horizontal and vertical strabismus in older patients. JAMA Ophthalmol. 2013;131:619-625.
3. Chaudhuri Z, Demer JL. Long-term surgical outcomes in the sagging eye syndrome. Strabismus. 2018;26:6-10.

Paper #25
Saturday, 9:16 am – 9:23 am

Horizontal and Vertical Eye Movements After Horizontal and Vertical Recti Were Detached from Eyes in Patients with Nystagmus

Dongsheng Yang, MD,PhD; Ping Wang, MD

Shandong Liangkang Eye Hospital, Bright Eye Hospital Group
Jinan, Shandong Province, P.R. China

Introduction: We usually believe that horizontal or vertical eye movements would be eliminated if horizontal or vertical recti were detached from the eye. However, we observed large horizontal or vertical eye movements after horizontal or vertical recti were detached from the eye. We will report the video-recorded eye movements.

Methods: The medial and lateral recti were surgically detached from insertions of the eyes during extra-ocular muscle (EOM) surgeries in 5 adult patients with infantile nystagmus syndrome. In another patient with acquired nystagmus, whose right superior rectus and inferior oblique were detached from her right eye, large (up to 20 degree) upword eye movements were also recorded. The amplitudes of the eye movements was estimated based on the distance of the movements.

Results: The amplitudes of the horizontal eye movements are about 25±5 degrees after the the medial and lateral recti were detached and amplitude of upward eye movements were about 20 degrees after the superior rectus and inferior oblique were detached.

Discussion: Large horizontal and vertical eye movements were recorded after horizontal and vertical EOM were detached. It indicates that vertical recti may involve in horizontal eye movments and horizontal recti may involve in vertical eye movements .

Conclusion: Activity of vertical recti during the horizontal eye movements may need to be investigated, and vice versa for vertical eye movements.

References: 1. Demer JL, Clark RA, Crane BT, Tian JR, Narasimhan A, Karim S.Functional anatomy of the extraocular muscles during vergence. Prog Brain Res. 2008;171:21-8.
2. Koene AR, Erkelens CJ.Properties of 3D rotations and their relation to eye movement control.Biol Cybern. 2004 Jun;90(6):410-7. Epub 2004 Jul 23.
3.Angelaki DE.Three-dimensional ocular kinematics during eccentric rotations: evidence for functional rather than mechanical constraints. J Neurophysiol. 2003 May;89(5):2685-96.

Paper #26
Saturday, 9:27 am – 9:34 am

Machine Learning for Prediction of Pediatric Ophthalmology Examination Lengths and Scheduling Optimization

Michelle R. Hribar, PhD; Wei-Chun Lin, MD; Isaac H. Goldstein, BA; Michael F. Chiang, MD

Oregon Health & Science University
Portland, Oregon

Introduction: Pediatric ophthalmologists are under pressure to see more patients in less time. This study investigates a machine learning model for predicting exam length in pediatric ophthalmology, based on existing electronic health record (EHR) data.

Methods: Data from 3049 office visits (2015-2018) from five pediatric ophthalmologists were used in a random forest machine learning classification model with 12 features (including prior average exam time, ICD-10 diagnosis code, age, dilation of eyes, patient's language, clinic volume, hour of the office visit). The exam time was predicted to be: short (shortest 20% of exam lengths), medium (middle 60%), or long (longest 20%). Ophthalmologists predicted exam lengths before scheduling each patient based on clinical and social factors. Accuracy was determined by comparing predictions to the actual exam lengths.

Results: The classification model had 65% accuracy for predicting exam length (short vs. medium vs. long) while the providers' accuracy was 41%. In the machine learning model, the top five predictors of exam length based on mean decrease accuracy (MDA) were prior average exam length, dilation, ICD-10 code, ophthalmologist, and patient age.

Discussion: This study demonstrates that existing EHR data may be used in machine learning algorithms to predict patient exam lengths. We have previously shown using computer-based simulations that scheduling patients according to their exam lengths (shortest exams first) reduced patient wait times. Taken together, this has potential to improve clinical efficiency for pediatric ophthalmologists.

Conclusion: Machine learning methods can predict patient exam lengths with comparable or better accuracy than physicians.

References: 1. Read-Brown S, Hribar MR, Reznick LG, et al. Time Requirements for Electronic Health Record Use in an Academic Ophthalmology Center. JAMA Ophthalmol. 2017;135(11):1250-1257.
2. Sanders DS, Lattin DJ, Read-Brown S, et al. Electronic health record systems in ophthalmology: impact on clinical documentation. Ophthalmology. 2013;120(9):1745-1755.
3. Hribar MR, Read-Brown S, Reznick LG, et al. Evaluating and Improving an Outpatient Clinic Scheduling Template Using Secondary Electronic Health Record Data. In: AMIA Annu Symp Proc. 2017.

Paper #27
Saturday, 9:34 am – 9:41 am

Pediatric Ophthalmology Documentation using Electronic Health Records (EHRs): Where Does the Data Come From, and How Often is it Reviewed?

Michael F. Chiang; Isaac H. Goldstein; Brad Henriksen; Abigail E. Huang; Jimmy Chen; Leah G. Reznick; Lorri Wilson; Michelle R. Hribar

Oregon Health & Science University Casey Eye Institute
Portland, Oregon

Introduction: Because EHR use is time-consuming, pediatric ophthalmologists frequently adopt strategies such as copy-paste and templates, which create long, redundant documentation. This study uses data analytic methods to quantitatively assess the prevalence of imported content in progress notes, and the proportion of prior notes opened.

Methods: Two attending pediatric ophthalmologists were included. There were three components: (1) Progress note text from 10 new and 20 follow-up office visits were characterized as manually-entered vs. imported using EHR audit log tools (EpiCare; Epic, Verana, WI). (2) 30 pairs of notes from serial follow-up encounters for the same patients were compared for similarity using computation tools (Workshare Compare, San Francisco, CA). (3) EHR audit logs from 1577 office visits were analyzed to identify the proportion of prior notes opened during each encounter (R, www.R-project.org).

Results: (1) On average, the majority of text words in new and follow-up progress notes was imported using sources such as copy-paste and templates (358/482 [74%] new, 464/524 [88%] follow-up). (2) On average, 647/947 [70%] text words in serial follow-up encounters were identical between notes. (3) On average, attending ophthalmologists reviewed 3.3±6.1% of prior notes at each encounter.

Discussion: Pediatric ophthalmologists may address these issues by collaborating in EHR system design, and in policymaking efforts to support regulations that promote documentation for clinical care rather than compliance.

Conclusion: EHR documentation in pediatric ophthalmology is heavily redundant and largely copied from outside sources, and few notes are being read during office encounters. These findings raise concerns about quality of clinical documentation.

References: 1. Read-Brown S, Hribar MR, Reznick LG, Lombardi LH, Parikh M, Chamberlain WD, Bailey ST, Wallace JB, Yackel TR, Chiang MF. Time requirements for electronic health record use in an academic medical center. JAMA Ophthalmol 2017; 135:1250-7.
2. Goldstein IH, Hribar MR, Read-Brown S, Chiang MF. Association of the presence of trainees with outpatient clinic appointment times in an ophthalmology clinic. JAMA Ophthalmol 2018;136:20-6.
3. Hribar MR, Read-Brown S, Goldstein IH, Reznick LG, Lombardi L, Parikh M, Chamberlain W, Chiang MF. Secondary use of electronic health record data for clinical workflow analysis. J Am Med Inform Assoc 2018;25:40-6.

Paper #28
Saturday, 11:20 am – 11:27 am

A Prospective Outcomes Study of Pediatric Optic Neuritis

Stacy L. Pineles, MD; Michael X. Repka, MD, MBA; Elizabeth L. Lazar, MS, MPH; Grant T. Liu, MD; Amy T. Waldman, MD; Mark S. Borchert, MD; Sangeeta Khanna, MD; Gena Heidary, MD, PhD; Jennifer S. Graves, MD; Veeral S. Shah, MD; Mark J. Kupersmith, MD; Raymond T. Kraker, MSPH; David K. Wallace, MD, MPH

Pediatric Eye Disease Investigator Group
Jaeb Center for Health Research, Tampa, Florida

Introduction: We are aware of no prospective data on visual outcomes in children with optic neuritis (ON).

Methods: In a non-randomized observational study, we prospectively enrolled 3-<16 year olds with a clinical diagnosis of acute ON (onset within 2 weeks) and at least one of the following: visual acuity (VA) deficit >/=0.2 logMAR below age-based norms in the affected eye, diminished color vision, abnormal visual field, or optic disc swelling. The primary outcome was percentage of study eyes within age-normal VA range after 6 months.[1-3]

Results: Fifty-four eyes of 44 participants age 3-15 years were enrolled; 41% were female. Regarding type of ON and central nervous system associations: 14 participants had unilateral isolated ON, 10 had bilateral isolated ON, 8 had acute disseminated encephalomyelitis, 5 had multiple sclerosis, 5 had neuromyelitis optica spectrum disorder, and 1 had myelin oligodendrocyte glycoprotein-associated demyelination. Twenty-two (51%) had cerebral white matter lesions and 39 (89%) were treated with steroids. Of the 31 affected eyes with 6-month follow-up, 8 (26%) had VA within age normal range at enrollment (median 0.50 logMAR, range -0.20 to 1.70 logMAR) and 24 (77%) eyes had VA within age normal range (median 0.00 logMAR, range -0.22 to 0.60 logMAR) after 6 months.

Discussion: Despite poor VA at presentation (median Snellen equivalent = 20/63), there was marked improvement in the majority six months after onset (median = 20/20).

Conclusion: In this prospective study visual acuity outcomes in pediatric ON were often favorable with current treatment practice patterns, although some patients have significant deficits.

References: [1] Pan Y, Tarczy-Hornoch K, Cotter SA, Wen G, Borchert MS, Azen SP, et al. Visual acuity norms in pre-school children: the Multi-Ethnic Pediatric Eye Disease Study. Optom Vis Sci. 2009;86:607-12.
[2] Drover JR, Felius J, Cheng CS, Morale SE, Wyatt L, Birch EE. Normative pediatric visual acuity using single surrounded HOTV optotypes on the Electronic Visual Acuity Tester following the Amblyopia Treatment Study protocol. Journal of AAPOS : the official publication of the American Association for Pediatric Ophthalmology and Strabismus / American Association for Pediatric Ophthalmology and Strabismus. 2008;12:145-9.
[3] Yamada T, Hatt SR, Leske DA, Moke PS, Parrucci NL, Reese JJ, et al. A new computer-based pediatric vision-screening test. J AAPOS. 2015;19:157-62.

Paper #29
Saturday, 11:27 am – 11:34 am

A Novel Algorithm for Visual Field Testing in Pediatric Neuro-Ophthalmic Disease Using Saccadic Vector Optokinetic Perimetry

Bilal K. AlWattar, MD; D.Luisa Mayer, PhD; Ronald M. Hansen, PhD; Gena Heidary, MD, PhD

Boston Children's Hospital
Boston, Massachusetts, USA

Introduction: Formal methods for visual field testing in young children are limited. Saccadic Vector Optokinetic Perimetry (SVOP), which utilizes eye tracking technology, has been introduced as a potential method for visual field assessment. This study seeks to determine the validity of a novel visual field algorithm which was specifically tailored for testing pediatric patients with neurologic disease using SVOP.

Methods: We prospectively compared a novel 33 point visual field algorithm developed at Boston Children's Hospital using SVOP to modified automated Humphrey perimetry testing protocol to assess the validity of the new method in pediatric patients.

Results: Eighteen participants (56% female) were enrolled between the ages of 10-18 (median 16) years. Ten subjects had normal visual fields and eight had known visual field loss; 3 had bitemporal hemianopias, 3 had homonymous hemianopias, and 2 had quadrantanopias. Successful completion of both testing paradigms occurred in 17/18 patients. The sensitivity of the new algorithm was 70%, the specificity was 91.5%, the positive predictive value was 62.4%, and the negative predictive value was 94%.

Discussion: SVOP testing with the new BCH pediatric neuro-ophthalmic disease algorithm was relatively sensitive in detecting neurologic visual field defects and was able to exclude the presence of visual field loss with high predictability.

Conclusion: Compared with standard perimetry, SVOP testing using this novel algorithm has the potential to detect visual field loss from underlying neurologic disease in pediatric patients and warrants further evaluation in a larger cohort of patients.

References: 1. Cummings MF, van Hof-van Duin J, Mayer DL, Hansen RM, Fulton AB. Visual fields of young children. Behav Brain Res. 1988; 29:7-16.
2. Murray IC, Fleck BW, Brash HM, MacRae ME, Tan LL, Minns RA. Feasibility of saccadic vector optokinetic perimetry. Ophthalmology 2009;116: 2017-26.
3. Pel J J-M, van Beijsterveld M C-M, Thepass G, van der Stern J. Validity and repeatability of saccadic response times across the visual field in eye movement perimetry. Trans Vis Sci Tech 2013;2: 1-12.

Paper #30
Saturday, 11:34 am – 11:41 am

The Effect of Decreasing Working Distance in Stereopsis and its Role in Perception of Closure While Texting and Driving

Amanda M. Selchau, MD; Kelli M. Coleman; Wyche T. Coleman, MD; Arthur S. Kavanaugh, MD; Alan Richards, MD

Louisiana State University, Shreveport
Shreveport, Louisiana

Introduction: The hypothesis was that working distance as well as the working angle are independent variables that provide a physiologic basis for the dangers of texting while driving.

Methods: Ninety-four medical students with no significant ocular disease volunteered to participate in the study. While viewing a video of a car in front of their own, participants had to respond when the participant perceived the leading car getting closer, and the trial was repeated while performing a math problem on a cell phone. Trials were done where the math game was held at 30 cm, 60 cm, 30 cm at 30 degrees, and 60 cm at 30 degrees.

Results: All trial had times that were significantly slower than the control. The slowest trial overall was 30 cm at 30 degrees. The trial at 30 cm was significantly slower than the trial at 60 cm ($p<0.01$). Furthermore, the trial at 30 cm held at 30 degrees was slower than 30 cm at 90 degrees ($p<0.01$)

Discussion: Both viewing angle and working distance affect the ability to perceive closure. Both visual acuity and stereopsis are severely affected. These findings help explain why texting and driving is so distracting when compared to other distracting tasks such as changing the radio or viewing the dash.

Conclusion: Other authors have established that texting while driving is dangerous. This study helps to isolate the visual effects of altering working angle and distance and the significant effects upon visual acuity and stereopsis.

References: 1. Carney et al. Examining teen driving crashes and the prevalence of distraction: Recent Trends, 2007-2015. Journal of Safety Research 2018;64:21-27.
2. Ortiz C et al. Driver distraction by smartphone use (WhatsApp) in different age groups. Accident Analysis & Prevention 2018;117:239-249.
3. Sheila G. Klauer, Ph.D., Feng Guo, Ph.D., Bruce G. Simons-Morton, Ed.D., M.P.H., Marie Claude Ouimet, Ph.D., Suzanne E. Lee, Ph.D., and Thomas A. Dingus, Ph.D. Distracted Driving and Risk of Road Crashes among Novice and Experienced Drivers. New England Journal of Medicine 2014;370:54-59.

Paper #31
Saturday, 11:41 am – 11:48 am

Treating Central-Peripheral Rivalry (CPR)-Type Diplopia

Jonathan M. Holmes, BM, BCh; Sarah R. Hatt, DBO; David A. Leske, MS; Raymond Iezzi, MD

Mayo Clinic
Rochester, Minnesota

Introduction: Epiretinal membranes (ERM), and other maculopathies associated with abnormalities of the photoreceptor mosaic, may cause central-peripheral rivalry (CPR)-type diplopia (aka dragged-fovea diplopia, binocular retinal diplopia). CPR-type diplopia is notoriously difficult to treat. We evaluated the success of various treatments.

Methods: 50 patients (44 with ERM) undergoing treatment for CPR-type diplopia (101 treatment episodes) were included. We only included patients with 'sometimes' or worse diplopia for distance or reading, using the Diplopia Questionnaire. We evaluated: prism, Bangerter filter/tape, iseikonic treatment, and ERM peeling. We defined success as improvement in diplopia to 'never' or 'rarely' for distance and reading, at a 6-month follow-up examination. Failure was assigned if diplopia was 'sometimes' or more at follow-up or if in-office treatment failed (persistent diplopia or not tolerated). Each treatment episode was assigned an outcome (not all patients tried every treatment) and success rates calculated with 95% confidence intervals (CIs).

Results: Success was achieved in 4/7 (57%, 95% CI 18%-90%) using Fresnel prism and 4/28 (14%; 4%-33%) using Bangerter/tape. 8/18 (44%; 22%-69%) had successful resolution of diplopia following ERM peeling (with or without prism). There was one success with iseikonic treatment (1/23; 5%, 0%-22%) but none using loose or ground prism (0/25; 0%, 0%-14%).

Discussion: Fresnel prism treatment was somewhat more successful than expected (presumably by blur) and Bangerter/tape treatment less successful. Unexpectedly, ERM peeling improved CPR-type diplopia in many patients.

Conclusion: CPR-type diplopia may be amenable to treatment by ERM peel, Fresnel prism, or blur and each should be considered for such patients.

References:

Paper #32
Saturday, 11:48 am – 11:55 am

Stepped Strabismus Surgery

Amr A. Elkamshoushy, MD; Ahmed Kassem, MD

University of Alexandria
Alexandria, Egypt

Introduction: To present and evaluate a new intraoperative technique in strabismus surgery that allows further operation on additional extra ocular muscles or to be skipped if the immediate intraoperative alignment is satisfactory.

Methods: This is a retrospective chart review of cases of stepped strabismus surgery from 2010 till 2018. In stepped surgery the first muscle is done under Propofol IV infusion general anesthesia (GA). The anesthesia technique is modified to allow full recovery within 30 minutes in the OR. Patient is assessed in the OR. If deemed necessary, GA is given again and another muscle is operated. No adjustable sutures were utilized.

Results: A total of 56 cases were included (22 superior oblique palsy (SOP), 29 horizontal deviations and 5 thyroid eye disease). The technique was used in SOP cases with angles ranging 12-25 PD. Inferior oblique myectomy was done as first step in all cases and 5 cases needed additional muscle surgery. Horizontal deviations ranged from 12 to 20 PD and all cases underwent a single horizontal rectus recession. 13 cases required another muscle surgery. Overall reoperation rate was 9%.

Discussion: The technique was utilized in borderline cases where the decision to operate on one or two muscle was difficult to make. It obviated the need for adjustable sutures in such cases with comparable success rate.

Conclusion: Stepped strabismus surgery is a useful technique for borderline cases with the potential for reducing the number of extra ocular muscles operated on without compromising the surgical outcome.

References:

Paper #33
Saturday, 11:55 am – 12:02 pm

What Causes Slow Binocular Reading in Amblyopic Children?

Krista R. Kelly, PhD; Reed M. Jost, MS; Bryan De La Cruz; Jeffrey S. Hunter, MD; Lori Dao, MD; Cynthia L. Beauchamp, MD; Joel N. Leffler, MD; Becky Luu, OD; Eileen E. Birch, PhD

Retina Foundation of the Southwest
Dallas, Texas

Introduction: Amblyopic children read slowly and make more forward saccades during binocular reading compared with nonamblyopic strabismic and control children (Kelly et al, 2015). Binocular inhibition - better performance during fellow eye viewing than binocular viewing - is related to slow reading in age-related macular degeneration and to contrast sensitivity loss in amblyopia. Here, we investigated whether binocular inihibition slows reading in amblyopia (i.e., slower reading for binocular versus fellow eye viewing).

Methods: 41 children age 7-12 years treated for strabismus, anisometropia, or both (24 amblyopic [0.2-1.2 logMAR], 17 nonamblyopic) were enrolled. Children silently read grade-appropriate paragraphs during binocular (BV) and fellow eye viewing (FEV) while fitted with the ReadAlyzer. Reading rate (words/min) and number of forward saccades (per 100 words) were recorded. Visual acuity (VA) and stereoacuity were obtained.

Results: Consistent with our previous study, amblyopic children read more slowly and made more forward saccades than nonamblyopic children during BV ($ps<0.05$). Nonetheless, no differences were found between BV and FEV for amblyopic children (Reading Rate: BV, mean±SD=160±57 vs. FEV, 154±63 words/min, $p=0.50$; Saccades: 107±35 vs. 109±46 per 100 words, $p=0.75$). Reading rate was not related to etiology, amblyopic eye VA, or stereoacuity.

Discussion: Binocular reading did not differ from fellow eye reading in amblyopic children; binocular inhibition is unlikely to play a role in their slow reading.

Conclusion: Slow reading in amblyopic children is not due to inhibition of the fellow eye by the amblyopic eye. We are currently exploring other potential factors contributing to slow binocular reading, including fixation instability and abnormal saccadic eye movements.

References: Kelly KR, Jost RM, De La Cruz A, Birch EE. Amblyopic children read more slowly than controls under natural, binocular reading conditions. J AAPOS, 2015;19(6):515-20.

Paper #34
Saturday, 12:06 pm – 12:13 pm

Feasibility of Eye Patch Assistant Plus a Microsensor to Monitor Objective Adherence with Patching

Jingyun Wang; Hongxin Xu; Reed M. Jost; Bryan De La Cruz; Sarah E. Morale; Eileen E. Birch

Salus University
Elkins Park, PA

Introduction: A microsensor was suggested to monitor adherence with patching amblyopia treatment due to its advantages: small, waterproof, long-lasting battery.(1) However, its application has been limited because of a number of practical challenges: 1) it is so small that it is hard to hold and is easily lost. 2) children or pets may swallow it due to its candy-like appearance. To overcome these challenges, we designed a small device, the Eye Patch Assistant (EPA), to facilitate patching with a microsensor. This study reports pilot data for use of the EPA coupled with a microsensor to monitor patching adherence.

Methods: 13 adults (11 control, 2 amblyopic) and 20 children (6 control, 14 amblyopic) were enrolled. Participants were asked to wear an Ortopad eyepatch (Patch) or an Ortopad eyepatch plus the EPA with a microsensor embedded (Patch+EPA). Each adult completed both testing conditions for 2 hours each in random order and reported their wearing time (based on clock). Each child was randomized to either Patch or Patch+EPA for a short period of time (5-20Min). The sensor reading interval was set to 5 min. After each test condition, a questionnaire with 12 questions related to comfort was administered.

Results: In the adult group, self-reported time wearing Patch+EPA (mean±SD) was 119±4Min, while the microsensor-reported 121±6Min. In the child group, self-reported time wearing Patch+EPA was 9.4±5.4Min, while the microsensor-reported 8.5±5.3Min. There was no significant difference between self-reported and microsensor-reported patch-wear time (paired t-test, $P=0.5$).There was no significant in comfort scores ($P>0.05$) for all questions.

Discussion: Objective adherence with patching can be monitored safely with a microsensor assisted with the EPA.

Conclusion: Within a predictable variability due to its 5-min sampling interval, a microsensor embedded in the EPA device provides a promising way to safely monitor adherence with patching in children.

References: 1. Januschowski K, Bechtold TE, Schott TC, Huelber-Januschowski MS, Blumenstock G, Bartz-Schmidt KU, et al. Measuring wearing times of glasses and ocular patches using a thermosensor device from orthodontics. Acta Ophthalmol. 2013;91(8):e635-40.

Paper #35
Saturday, 12:13 pm – 12:20 pm

Novel Digital Therapeutic Improves Visual Acuity and Encourages High Adherence in Amblyopic Children

Aaron M. Miller, MD; Lisa I. Bohra, MD; Christie L. Morse, MD; Louis C. Blumenfeld, MD; Noha S. Ekdawi, MD; Ann U. Stout, MD; Scott Xiao; David G. Hunter, MD; Eric Gaier, MD; Malcolm L. Mazow, MD

Houston Eye Associates; Children's Eye Care Michigan; Concord Eye Center; Eye Physicians of Central Florida; Wheaton Eye Clinic
Houston, TX; Detroit, MI; Concord, NH; Orlando, FL; Chicago, IL

Introduction: Current amblyopia treatments can be limited in effectiveness due to low adherence over long treatment periods (33-54%)[1] and monocular viewing conditions. We tested the clinical effectiveness and adherence of Luminopia One - a virtual reality system that applies binocular therapeutic modifications to television shows or movies chosen by the patient.

Methods: This single-arm, multi-center study enrolled children aged 4-12 with anisometropic, strabismic, or mixed amblyopia at 10 centers to use Luminopia One at-home for 1 hour/day, 6 days/week for 12 weeks. Best-corrected visual acuity (BCVA) and stereoacuity (Randot) were assessed at each visit. A group of participants (n=20) was excluded from this analysis due to improper software calibration.

Results: Of the 55 enrolled participants (mean age 7.1 +/- 2.3 years), 53 had stable BCVA at enrollment and 46 had prior treatment beyond glasses (e.g., patching, atropine). Thirty-one participants have completed 12 weeks of treatment with mean adherence 84% of prescribed dose. Mean amblyopic eye BCVA improved 0.20 logMAR (2 lines; 95% CI 0.14-0.25, $p<0.0001$) after 12 weeks from baseline of 0.47 logMAR. Mean stereoacuity improved 0.30 log arcsec (1 octave step; 95% CI 0.00-0.59, $p=0.047$). Infrequent mild blurry vision (n=3), headache (n=3), and double vision (n=1) were reported and resolved without additional treatment.

Discussion: Patients demonstrated clinically and statistically significant improvements in visual acuity and stereoacuity, maintaining high adherence over 12 weeks.

Conclusion: Luminopia One shows promise as an engaging and potentially effective at-home amblyopia treatment.

References: 1. Wallace MP, Stewart CE, Moseley MJ, Stephens DA, Fielder AR. Compliance With Occlusion Therapy for Childhood Amblyopia. Invest Ophthalmol Vis Sci 2013;54(9):6158-6166

Paper #36
Saturday, 12:24 pm – 12:31 pm

Baseline and Clinical Factors Associated with Response to Binocular Amblyopia Treatment

Eileen E. Birch, PhD; Reed M. Jost, MS; Krista R. Kelly, PhD; Joel N. Leffler, MD; Lori Dao, MD; Cynthia L. Beauchamp, MD

Retina Foundation of the Southwest
Dallas, TX, USA

Introduction: We previously reported results from our primary cohort (n=28) enrolled in a randomized clinical trial (NCT02365090) that reported binocular amblyopia treatment was effective in treating childhood amblyopia and more efficacious than patching (Kelly, Jost et al JAMA Ophthalmol 2016). Completion of enrollment into our preplanned secondary cohort combined with the primary cohort (n=48), has now provided sufficient power to determine whether there exist baseline and/or clinical factors that are predictive of response to binocular treatment.

Methods: 48 amblyopic children (4-10 y) were randomly assigned binocular game or patching treatment at home. The primary outcome was change in amblyopic eye best-corrected visual acuity (AE BCVA) at the 2-week visit. Change in stereoacuity was a secondary outcome. Baseline factors: age at enrollment, AE BCVA, stereoacuity, suppression. Clinical factors: etiology, age at diagnosis, prior treatment, baseline alignment.

Results: AE BCVA improvement was greater with the binocular game than patching (mean±SD=0.14±0.08 vs 0.07±0.09 logMAR; t=3.00, p=0.004). Improvement from baseline was significant for the binocular game [95%CI: 0.11-0.17 logMAR] and patching [95%CI: 0.03-0.10 logMAR]. Stereoacuity improvement was greater with the binocular game than patching (0.06±-0.18 vs -0.06±0.23 log arcsec; t=2.07, p=0.04). Only one factor was associated with AE BCVA change with game treatment; orthotropic children had greater improvement than children with 2-4pd esotropia (0.17±0.07 vs 0.09±0.05 logMAR; t=2.37, p=0.03). In addition, change in AE BCVA was significantly correlated with hours of game play (r=0.67; p<0.0001).

Discussion: Binocular amblyopia treatment was effective in treating childhood amblyopia, especially among orthotropic children who had more game play time.

Conclusion: Orthotropia and adherence were associated with binocular amblyopia treatment success.

References:

Paper #37
Saturday, 12:31 pm – 12:38 pm

Reliability of Telemedicine for Real-Time Pediatric Ophthalmology Consultations

Sudha Nallasamy, MD; Josephine Coffey-Sandoval, OD; Carly Stewart, MHA; Mark W. Reid, PhD; Thomas C. Lee, MD

Children's Hospital Los Angeles
Los Angeles

Introduction: Geographic and socioeconomic disparities in access to care impede timely diagnosis and treatment of pediatric ophthalmic conditions.(1) Telemedicine may address these disparities, but its technological and diagnostic reliability are uncertain.(2)

Methods: This prospective, non-inferiority study included 349 examinations of 210 patients aged 0-17 years (median, 6 years). Examinations were conducted by an optometrist using Pivothead glasses, a digital slit lamp, and a digital indirect ophthalmoscope, and streamed via Polycom codec to an ophthalmologist, who recorded diagnoses, measurements, and management plans. Following each telemedicine examination, the ophthalmologist verified the results in-person.

Results: Sixty-two percent of patients were primarily diagnosed with strabismus (n=130); other common primary diagnoses included nasolacrimal duct obstruction (n=8) and glaucoma (n=7). No primary diagnoses were changed (although two non-primary diagnoses were), and no management plans (including surgical plans) were changed following in-person examination. In strabismus patients, almost perfect agreement was observed for angle measurements (ICCs=0.97-1.00) and disease categorization (κ=0.94-1.00). Almost all patients who consented for surgery (54/55) did so during the telemedicine examination, masked to receiving an in-person exam. Most families felt comfortable with the quality of the telemedicine examination (99%), and indicated they would participate in another one in the future (97%).

Discussion: The ophthalmologist was able to make accurate diagnoses, plans, and measurements via telemedicine, in contrast to previous studies with older technology.(3)

Conclusion: Pediatric ophthalmic conditions can be reliably diagnosed and monitored by ophthalmologists via telemedicine. Care delivery for underserved populations can be improved by collaboration between optometrists and ophthalmologists using video-conferencing technology.

References: 1. Ehrlich JR, Anthopolos R, Tootoo J, Andrews CA, et al. Assessing Geographic Variation in Strabismus Diagnosis among Children Enrolled in Medicaid. Ophthalmology. 2016;123:2013-22.
2. Sreelatha OK, Ramesh SV. Teleophthalmology: improving patient outcomes? Clin Ophthalmol. 2016;10:285-95.
3. Cheung JC, Dick PT, Kraft SP, Yamada J, et al. Strabismus examination by telemedicine. Ophthalmology. 2000;107:1999-2005.

Paper #38
Saturday, 12:38 pm – 12:45 pm

Redesigning Surgical Magnification Loupes: Effect of Angle of Declination, Weight, and Strap Design on the Postural Ergonomics of Ophthalmic Surgeons

Safeer F. Siddicky, PhD; Hozhabr Mozafari, MS; Gregory W. King, PhD, PE; Donny W. Suh, MD

University of Arkansas for Medical Sciences
Little Rock, AR

Introduction: Ophthalmologists using surgical loupes often report chronic neck pain [1,2]. We designed a surgical loupe and head-strap to reduce neck loading in surgeons. To quantify the effect of this new loupe design on surgeons' posture, we utilized kinematic motion capture [3], musculoskeletal modeling and electromyography (EMG).

Methods: We customized a Galilean loupe through 3D printing. It was lighter than conventional designs, had a large angle of declination, and was fitted with a novel head strap that reduced loupe slippage and offloaded weight from the nasal bridge. We compared the redesigned loupe to a conventional loupe by quantifying the force on the nasal bridge, operating neck flexion, and neck muscle effort and activity by using material properties, a bubble inclinometer, computational modeling, and EMG, respectively.

Results: Results are presented as conventional loupe vs. redesigned loupe. Loupes' forces on the nasal bridge were calculated as 0.648 N vs. 0.272 N. Operating neck flexion angles were 40° vs. 15°. From the computational model, the counter torques needed to maintain the neck at the loupes' operating postures were 1537 Nmm vs. 933 Nmm. Upper Trapezius EMG activity was found to be 0.521± 0.047 vs. 0.150± 0.037 (% of maximal voluntary muscle contraction).

Discussion: The reduction in nasal bridge force, operating neck flexion, and neck muscle effort and activity indicate that using a lighter Galilean loupe, with a high angle of declination and an offloading head strap, has the potential to reduce neck muscle loading in surgeons.

Conclusion: New designs of surgical loupes may reduce the risk of musculoskeletal disorders of the neck and lower back of ophthalmologists, by improving the surgeons' ergonomics.

References: 1. Sivak-Callcott JA, Diaz SR, Ducatman AM, Rosen CL, Nimbarte AD, Sedgeman J a. A survey study of occupational pain and injury in ophthalmic plastic surgeons. Ophthal Plast Reconstr Surg. 2011;27(1):28-32.
2. Nimbarte AD, Sivak-Callcott JA, Zreiqat M, Chapman M. Neck Postures and Cervical Spine Loading Among Microsurgeons Operating with Loupes and Headlamp. IIE Trans Occup Ergon Hum Factors. 2013;1(4):215-223.
3. Branson BG, Abnos RM, Simmer-Beck ML, King GW, Siddicky SF. Using motion capture technology to measure the effects of magnification loupes on dental operator posture: A pilot study. Work. 2018;59(1):131-139.

Posters

Poster #1
Thursday, 9:55 am – 10:55 am

Reaching Target Communities in a Preschool Vision Screening Program

Richard A. Ulangca, BS; Chase R. Atiga, BA; Connie J. Oh, BS; Jennifer A. Dunbar, MD; Leila M. Khazaeni, MD

Loma Linda University School of Medicine
Loma Linda, California

Introduction: Preschool vision screening programs often utilize day care facilities as screening sites. This study describes a novel methodology to identify childcare facilities that serve the greatest number of children in the lowest income communities.

Methods: Vision screening locations, number of children screened, and referral rates in a vision screening program from 2015 to 2018 were grouped by ZIP code. Licensed childcare facilities were scored (1 to 5) based on the socioeconomic status of the ZIP code (median household income, U.S. Census Bureau) and the facility capacity (California Department of Social Services). The scoring system prioritized larger facilities in lower income communities. Facilities were mapped using geoinformatics software (ESRI, Redlands, CA).

Results: 21663 screenings were performed at 216 locations in 83 ZIP codes. 7037 childcare facilities in this region had a cumulative capacity for 395,167 children. Referral rates were higher in ZIP codes with lower median household income. Heat maps were created identifying areas not currently screened with the largest preschool populations and greatest socioeconomic need. The availability and capacity of childcare facilities (for children age <5) positively correlated with median household income ($p<0.05$, Kolmogorov-Smirnov analysis).

Discussion: Challenges to vision screening in underserved communities include the lack of childcare facilities and smaller facility size. This scoring system, incorporating heat maps, can geographically display and prioritize potential screening sites based on greater daycare capacity and socioeconomic need.

Conclusion: The use of a scoring system and GIS mapping software can direct vision screening programs to reach a greater number of children with the most efficient use of resources.

References: Longmuir SQ, Pfeifer W, Leon A, Olson RJ, Short L, Scott WE. Nine-year results of a volunteer lay network photoscreening program of 147 809 children using a photoscreener in Iowa. Ophthalmology. 2010. doi:10.1016/j.ophtha.2010.03.036
Child Care Centers. secure.dss.ca.gov/CareFacilitySearch/DownloadData. Accessed July 13, 2018.

Poster #2
Thursday, 9:55 am – 10:55 am

Implications of Community-Based Repeat Annual Vision Screening Using the Spot Photoscreener

Connie J. Oh, BS; Richard A. Ulangca, BS; Chase R. Atiga, BA; Stephanie Terrill, MD; Leila M. Khazaeni, MD; Jennifer A. Dunbar, MD

Loma Linda University School of Medicine
Loma Linda, California

Introduction: The implications of repeat annual visual screening have not been reported. This study compares photoscreening characteristics of children who fail repeat annual preschool vision screening.

Methods: Children screened with the SPOT photoscreener from 2015-2018 were categorized based on the results of repeat screening: Fail-Fail, Fail-Pass, Pass-Fail. The medians of the spherical and cylindrical powers for the first fail, and the medians of the change in spherical and cylindrical powers between the first and second screening were compared among the groups using Kruskal-Wallis ANOVA and Mann-Whitney tests.

Results: Of 20,375 children screened, 1,299 received repeat annual screening and 262 children failed at least once, with 93 in the Fail-Fail, 56 in the Fail-Pass, and 43 in the Pass-Fail group. 70 were excluded due to incomplete data. The Fail-Fail group had greater cylindrical error ($p<0.001$) and smaller change in cylindrical power than the other groups ($p<0.001$). Follow-up rate after initial referral was 71% (Fail-Fail group) and 84% (Fail-Pass group).

Discussion: Children who failed repeat annual vision screening (Fail-Fail group) were more likely to show higher levels of astigmatism and stable levels of astigmatism between screenings with the SPOT photoscreener. This may be due to the lower rate of follow up in this group. High cylindrical power and stable cylindrical power over time have been associated with higher rates of amblyopia.

Conclusion: Astigmatism readings prompting referral with the SPOT photoscreener are stable between annual screenings. Compliance with follow up should be emphasized in children with cylindrical error who fail repeat vision screening.

References: Visual System Assessment in Infants, Children, and Young Adults by Pediatricians. Am Acad Pediatr. 2016;137(1):e20153596. doi:10.1542/peds.2015-3596.
Holmes JM, Clarke MP. Amblyopia. Lancet. 2006;367(9519):1343-1351. doi:10.1016/S0140-6736(06)68581-4.
Sjostrand J, Abrahamsson M. Risk Factors in Amblyopia. Eye. 1990;4:787-793.

Poster #3
Thursday, 9:55 am – 10:55 am

Vision Screening and Educational Development in Preschoolers from Low-Income Communities

Christopher R Lees; Andrea Everett, PhD; Zaynab Sajjadi; April Nakayoshi;
Alejandra G. de Alba Campomanes, MD, MPH

University of California, San Francisco
San Francisco, California

Introduction: Children with uncorrected refractive errors have been shown to have lower cognitive abilities compared to emmetropic children (1). We studied the differences in academic, language, psychosocial, motor and artistic developmental scores between preschoolers identified as needing glasses and those who passed the vision screening test.

Methods: This cross-sectional study included low-income preschoolers in California, who underwent Retinomax-based vision screening (2), free comprehensive eye examination on an eye mobile and evaluation with the Desired Results Developmental Profile (DRDP) at the start of the 2017-2018 academic year. The DRDP assessment included sixty skill indicators grouped into eight domain scores for each child. T-tests for independent samples were used to compare DRDP domain scores (3).

Results: Of 1645 children screened, 861 had matching DRDP results and consented to participate (mean age 47.9 months, range 33-61.4 months), ethnicity was 40% Asian/Pacific Islander and 36% Hispanic/Latino. 139 children failed vision screening with a true-positive rate of 60% (67/112). The mean difference between DRDP scores was 15-63 points (4.2-13.8%) lower for all domains in the group of children identified as needing glasses.

Discussion: Low income preschoolers identified as needing glasses performed significantly lower on educational development assessments.

Conclusion: More studies are needed to show if preschool vision screening and correction of amblyopia risk factors has an effect in narrowing this academic/developmental gap.

References: 1. VIP-HIP Study Group, Kulp MT, Ciner E., Maguire M, Moore B, Pentimonti J, Pstilli M, Cyert L, Candy TR, Quinn G, Ying GS. Uncorrected Hyperopia and Preschool Early Literacy: Results of the Vision in Preschoolers-Hyperopia in Preschoolers (VIP-HIP) Study.' Ophthalmology, vol. 123, no. 4, 2016, pp. 681-689.,

2. Lowry EA, De Alba Campomanes AG. 'Cost-Effectiveness of School-Based Eye Examinations in Preschoolers Referred for Follow-up From Visual Screening.' JAMA Ophthalmology, vol. 134, no. 6, Jan. 2016, p. 658.,

3.California Department of Education, Child Development Division. California Desired Results Developmental Profile© (2010) Technical Report. 2013. Available at: https://www.desiredresults.us/sites/default/files/docs/resources/DRDP%C2%A9%20%282010%29%20Technical%20ReportAug15_13%281%29.pdf Accessed: September 28, 2018.

Poster #4
Thursday, 9:55 am – 10:55 am

Refractive Error Prevalence Among Inner-City Students Receiving School-Based Vision Screenings and Eye Exams

Angeline Nguyen, MD; Xinxing Guo, MD, PhD; Amanda Inns, PhD; Alyssa M. Kretz, BA; Moneesha R. Mukherjee, BA; David S. Friedman, MD, MPH, PhD; Michael X. Repka, MD, MBA; Megan E. Collins, MD, MPH

Johns Hopkins Wilmer Eye Institute
Baltimore, MD, USA

Introduction: Recent publications have reported that a significant proportion of children in high poverty schools have uncorrected refractive error. 1, 2 We present the prevalence and severity of refractive error among students participating in a school-based vision screening and eye exam program in Baltimore.

Methods: During 2016-17, 2273 students who failed a vision screening based on distance acuity or photoscreener underwent a school-based non-cycloplegic eye exam by licensed optometrists. Students were prescribed glasses based on visual acuity and refractive error severity. Associations of refractive error with gender and grade were assessed using generalized estimating equation models.

Results: Based on autorefraction results from 2219/2273 (98%) students, 1201 (54%) had myopia (spherical equivalent (SE) </=-0.5D), 657 (30%) had hyperopia (SE >/=+0.5D), 1341 (60%) had astigmatism (cyl >/=+1D), and 682 (30.8%) had anisometropia (>/=1D). Two hundred sixty-seven (22%) had moderate to severe myopia (SE </=-3.00D) and 210 (32%) had moderate to severe hyperopia (SE > +2.00D). Compared to grade 1, students in grade 3 and higher were more likely to have myopia (odds ratio (OR): 2.16 – 4.83) and less likely to have astigmatism (OR: 0.32 – 0.56). Compared to boys, girls were less likely to have astigmatism (OR: 0.68).

Discussion: In this inner-city population, over 90% of students who failed vision screenings were ametropic. Increased myopia was seen in higher grades. One in five students had moderate to severe refractive error.

Conclusion: A substantial proportion of students in a school-based program have uncorrected refractive error.

References: 1 Ruderman M. Children's vision and eye health: a snapshot of current national issues. Available at http://www.preventblindness.org/sites/default/files/national/documents/Children%27s_Vision_Chartbook.pdf; 2016
2 Mayro EL, Hark LA, Shiuey E, Pond M, et al. Prevalence of uncorrected refractive errors among school-age children in the School District of Philadelphia. J AAPOS. 2018;22:214-217.

Poster #5
Thursday, 9:55 am – 10:55 am

Effects of State Variation in Vision Screening Policy on Likelihood of Vision Screening in Children Ages Three to Five

John H. Lillvis, MD, PhD; Denise F. Lillvis, PhD; Lorin Miller; Gregory Wilding, PhD; Dennis Z. Kuo, MD, MHS

Jacobs School of Medicine and Biomedical Sciences, University at Buffalo
Buffalo, NY

Introduction: Childhood vision screening requirements vary by state; some require screening as early as age three and others fail to require any screening. This study examines the relationship between state vision screening requirements and the likelihood that children ages three to five receive vision screening.

Methods: We collected state vision screening requirements using available sources, validating and updating these policies by reviewing text available through WestLaw. We then combined this data with the 2016 National Survey of Children's Health. The study outcome was parent report on whether their child ever received vision screening, controlling for sociodemographics, insurance status, and other factors. We then utilized survey based logistic regression models, which control for within-state clustering and stratification.

Results: Parents from states with a vision screening requirement were more likely to report that their children had vision screening (OR = 1.37; $p<0.05$). This effect persists even after controlling for medical conditions where vision screening may be indicated. Additionally, vision screening requirements were associated with whether the child received preventative care in the past 12 months, but not race/ethnicity, household income, or language spoken at home.

Discussion: While one would assume that state requirements would positively affect child receipt of preventative health screening, this is not always the case.1 Further work is needed to understand how the specifics of such policies influence vision screening and if they translate to improved clinical outcomes.

Conclusion: Vision screening is important in detecting preventable causes of childhood vision loss. This study demonstrates that state requirements affect the likelihood that children are screened.

References: 1. Bethell C, Reuland C, Schor E, Abrahms M, Halfon N. Rates of parent-centered developmental screening: disparities and links to services access. Pediatrics 2011;128(1):146-155

Poster #6
Thursday, 9:55 am – 10:55 am

Analysis of Vision Screening Failures in a School-Based Vision Program (2016-18)

Rachel R. Milante, MD; Xinxing Guo, MD, PhD; Amanda Inns, PhD; Alyssa Kretz, BA; Moneesha R. Mukherjee, BA; David S. Friedman, MD, PhD, MPH; Michael X. Repka, MD, MBA; Megan E. Collins, MD, MPH

Krieger Children's Eye Center, Wilmer Eye Institute
600 North Wolfe St, Wilmer 233, Baltimore MD 21287-9028

Introduction: Vision screenings aim to identify students with possible vision problems. Maryland law mandates vision screening for students at pre-K or K, 1st, and 8th grade[1,2]. As part of a Baltimore school-based vision care program, screenings were conducted for all students, including those in state-mandated grades and non-mandated grades (2-7), in 82 schools. We report failure rates for these vision screenings.

Methods: From 2016-18, 32650 pre-K to 8th grade students from Baltimore schools underwent vision screenings (distance acuity, Spot photoscreener, stereopsis, and alignment) by Health Department staff.

Results: Over a two-year period, 10868 (33.3%) students failed – 5340 (32.2%) in Year 1 and 5528 (34.4%) in Year 2. Reduced visual acuity was the primary reason for screening failure (89% - median 20/50 (20/32 – 20/160). High failure rates were seen across all grades. Failure due to visual acuity increased with grade level, while failure due to refraction decreased in higher grades. Failure rates were higher in non-mandated grades compared with mandated grades (34.5% vs. 30.6%, $p<0.001$).

Discussion: High screening failure rates were seen in all grades suggesting that screening at select grade levels may not be sufficient, especially in similar high-poverty communities.

Conclusion: Nearly a third of Baltimore city grade school students failed vision screening, underscoring the large need for care and possibly limited access to or lack of sustained delivery of eye care in this high-poverty community.

References: 1 Maryland Code on Education 2013 – Hearing & Vision Screening. Available at: https://law.justia.com/codes/maryland/2013/article-ged/section-7-404/. Accessed September 30, 2018.
2 Baltimore City Health Department, Bureau of School Health. School Vision Screening Manual, April 2016

Poster #7
Thursday, 9:55 am – 10:55 am

A Qualitative Approach to Understanding Reasons for Non-Participation in School-Based Vision Programs

Hursuong Vongsachang, BA; Amanda J. Inns, PhD; Alyssa M. Kretz, BA; Moneesha R. Mukherjee, BA; David S. Friedman, MD, MPH, PhD; Michael X. Repka, MD, MBA; Megan E. Collins, MD, MPH

Johns Hopkins Wilmer Eye Institute
Baltimore, MD, USA

Introduction: Despite providing eye care access directly in schools, participation in school-based vision programs is often low. Prior literature examining reasons for non-participation is limited [1, 2]. Our research sought to understand parent and teacher attitudes about these programs and reasons for non-participation.

Methods: We conducted eighteen semi-structured focus groups, eight with parents and ten with teachers/staff, at schools offering school-based vision programs (screening, eye exams, and free eyeglasses if needed). Focus groups ranged in size from 2-9 participants (median=4.5). Sessions were recorded, transcribed, and coded through an iterative process. We used inductive analysis to develop themes.

Results: Thirty-one parents and 58 teachers/staff participated. Major themes identified as reasons for not participating in school-based vision programs related to trust for some and already having an eye doctor for others. Regarding trust, participants were concerned about the providers' qualifications and quality of care provided by school-based programs, stating a preference for accompanying their child with a provider they know. Minor themes included parents not perceiving a need for eye care, considering eye care a low priority, negative feelings about schools invading into personal lives, misunderstanding of the program (such as cost), potential stigma of receiving free services, and negative attitudes towards wearing glasses.

Discussion: In focus groups with parents and teachers, mistrust and current access to care were major reasons why families did not participate in school-based vision programs.

Conclusion: School-based vision programs should explore strategies to build trust with parents and focus services towards those without existing eye care in the community.

References: Frazier M, Garces I, Scarinci I, Marsh-Tootle W. Seeking Eye Care for Children: Perceptions among Hispanic Immigrant Parents. Journal of Immigrant and Minority Health. 2008;11(3):215-221.
Kodjebacheva GD, Maliski S, Coleman AL. Use of Eyeglasses Among Children in Elementary School: Perceptions, Behaviors, and Interventions Discussed by Parents, School Nurses, and Teachers During Focus Groups. American Journal of Health Promotion. 2015;29(5):324-331.

Poster #8
Thursday, 9:55 am – 10:55 am

The Value of Multiple Telephone Calls in Ensuring Follow-Up After Referral From Vision Screening

Chase R. Atiga, BA; Connie J. Oh, BS; Richard A. Ulangca, BS; Leila M. Khazaeni, MD; Jennifer A. Dunbar, MD

Loma Linda University
Loma Linda, CA

Introduction: The success of a vision screening program depends on follow-up of referred children for comprehensive exam. This study evaluates the benefit of multiple phone calls to families of children referred from vision screening for scheduling follow-up appointments.

Methods: Families of children referred from vision screening between 9/2015 and 4/2018 were called up to 3 times to provide referrals and confirm follow-up. Children with scheduled appointments were marked 'completed follow-up'. Follow-up confirmation responses were compared according to number of call attempts made. Follow-up non-confirmation responses for 1st calls, 2nd calls, and consecutive call responses were compared. Chi-squared tests were performed for comparisons.

Results: 1928 (62%) referred children reported follow-up. 7102 telephone calls were made. Follow up yield after the 1st call was 25%. Of those children remaining, a 2nd call yielded 29% and a 3rd call 28% (p=.007).
For 1st (p<.001), 2nd (p<.001), and consecutive (p<.001) call response comparisons, the 'answered phone, without scheduled appointment' group [n=116 (66%); n=156 (66%); n=43 (68%)] had higher follow-up than those 'left a message' [n=397 (36%), n=277 (28%), n=215 (26%)], which had higher follow-up than the 'unable to reach' [n=32 (18%); n=29 (15%); n=11 (10%)].

Discussion: Improved communication following vision screening reduces barriers to follow-up compliance. In this study, follow-up rates increased with multiple phone calls compared to one phone call. Follow-up rates were higher for families reached by telephone than those for whom messages were left or who were unreachable.

Conclusion: Reaching families by pursuing multiple telephone calls is effective in increasing follow-up rates after vision screening referral.

References: Williams S, Wajda BN, Alvi R, McCauley C, Martinez-Helfman S, Levin A V. The challenges to ophthalmologic follow-up care in at-risk pediatric populations. J AAPOS. 2013. doi:10.1016/j.jaapos.2012.11.021

Poster #9
Thursday, 9:55 am – 10:55 am

Vision Screening and the School Nurse in Washington State

K. David Epley, MD; Jeffrey D. Colburn, MD; Matthew C. Weed, MD; Julie Schultz

Introduction: Vision screening (VS) regulations for public schools in Washington were recently revised to modernize procedures, to add the requirement of near VS (unfunded mandate), and to allow the alternative of instrument-based screening. We sought to assess the attitudes and practices of school nurses in Washington with regards to VS, before and after implementation of the new regulations.

Methods: Using an internet survey, we queried school nurses statewide at the end of school years 2017 and 2018.

Results: There were 319 participants in 2017, 399 in 2018. Less than 6% reported checking near vision in 2017, increasing to 96% in 2018. Concurrently, there was an increase in reported use of instrument-based VS from 14% in 2017 to 66% in 2018, (88% reported using the device on all children screened in 2018). In 2018, 60% of participants reported having enough time and resources for VS and 68% reported that the new regulations made screening more difficult. Both years, approximately 90% felt that VS made a difference for their students.

Discussion: The added requirement for near VS without additional resources has placed an undue burden on school nurses in Washington. This has led many districts to adopt instrument-based VS as an allowed alternative for all age groups in place of traditional visual acuity testing.

Conclusion: State-wide VS regulations should consider the resources school nurses need as well as the evidence basis for and efficacy of near VS. Further research is needed to verify that it is equivalent to supplant traditional visual acuity testing in school-age children with instrument-based VS.

References:

Poster #10
Thursday, 9:55 am – 10:55 am

Prevalence and Perception of Childhood Vision Needs Following Discontinuation of School Screenings in Tanzania

Kayla M. White; Ariana Naaseh; Chantal J. Boisvert, MD, OD; Justine Chinn; Justine Maher; Elizabeth Crawford; Emma Cooper; Danielle Zezoff; Andreea Dinicu; Alexa Lucas; Kevin Bera; Ava Runge

University of California Irvine School of Medicine
Irvine, California

Introduction: In 2017, Tanzania discontinued its national in-school vision screening program, leaving caretakers largely responsible for detecting eye problems in their children. This study assesses pediatric vision needs and caretaker perspectives regarding eye care in the little-characterized city of Mwanza, Tanzania.

Methods: UCI medical students worked alongside Tanzanian optometrists to perform vision screenings on 317 children (age 3-17) in Mwanza. Children who failed screening assessments received free comprehensive eye exams at local hospitals. 229 caretakers completed a survey assessing their knowledge of pediatric eye problems and services.

Results: Poor near and distance visual acuity were present in 9.8% and 9.7% of children, respectively, which are significantly higher rates than previously reported in Mwanza ($P<0.049$).1,2 Young age was independently associated with poor near and distance visual acuity. Additional ocular morbidities include astigmatism (2.7%), abnormal red reflex (1.5%), and conjunctivitis (13.5%).
Only 11.7% of children had ever received an eye exam before. While financial barriers were the most common reason caretakers had not sought eye exams for their children, the second leading cause was belief that their child did not have any vision problems. However, caretakers in Tanzania exhibited poor awareness of childhood eye problems compared to developed nations.3

Discussion: Findings indicate a higher prevalence of pediatric vision problems than previously reported, low rate of prior eye exam, and poor caretaker knowledge of childhood eye problems.

Conclusion: Results will be provided to Tanzanian health authorities to convey the need for in-school vision screening programs and increased caretaker education regarding childhood eye care needs.

References: 1. Wedner SH, Ross DA, Todd J, Anemona A, Balira R, Foster A. Myopia in secondary school students in Mwanza City, Tanzania: the need for a national screening programme. British Journal of Ophthalmology. 2002;86(11):1200-1206.
2. Wedner SH. Prevalence of eye diseases in primary school children in a rural area of Tanzania. British Journal of Ophthalmology. 2000;84(11):1291-1297.
3. Donaldson L, Subramanian A, Conway ML. Eye care in young children: a parent survey exploring access and barriers. Clinical and Experimental Optometry. 2018;101(4):521-526.

Poster #11
Thursday, 9:55 am – 10:55 am

Response to Patching in Amblyopic Patients with and without Fusion Maldevelopment Nystagmus

Matteo Scaramuzzi, MD; Aasef Shaikh, MD, PhD; Fatema Ghasia, MD

Cleveland Clinic
Cleveland, OH

Introduction: Amblyopia is a neurodevelopmental disorder due to de-correlated binocular input to the visual cortex. The treatment comprises of occlusion of non-amblyopic eye to promote the development of vision in amblyopic eye)1). Amblyopes who experienced disruption of binocularity during first six months of life develop fusion maldevelopment nystagmus (FMN). The slow phase velocity (SPV) of FMN increases under monocular viewing conditions)2). Limited studies have shown that full-time occlusion causes a compensatory decrease in SPV over days, thus it was recommended in patients with FMN(3).

Methods: Amblyopic patients with and without FMN were recruited. Part-time occlusion (2-6 hours/day) was prescribed depending on the severity of amblyopia per the PEDIG studies. We analyzed the relationship between the presence of FMN and response to part-time occlusion.

Results: Forty-eight amblyopic patients were recruited[FMN(n=15) and no FMN(n=33)]. Patients were stratified by severity of amblyopia at the time of diagnosis (mild=3, moderate=34 and severe=11). Compliance to treatment was comparable between the two groups. 33% of patients with FMN and 30% without FMN were treated with no residual amblyopia (chi squared: p=0.886). The number of months of patching was greater in patients with FMN (27±18.5) versus without FMN (22.4±13.5, p=0,024).

Discussion: The presence of FMN did not have an impact on treatment compliance. Moreover, occlusion showed efficacy in patients with and without FMN. Interestingly, the duration of treatment in successfully treated amblyopic patients was longer in FMN group than in those without FMN.

Conclusion: Amblyopic patients with FMN respond to part-time occlusion, however, treatment should be maintained longer.

References: 1. Wallace DK, Pediatric Eye Disease Investigator Group, Edwards AR, Cotter SA, Beck RW, Arnold RW, et al. A randomized trial to evaluate 2 hours of daily patching for strabismic and anisometropic amblyopia in children. Ophthalmology. 2006 Jun;113(6):904-12.
2. Tychsen L. Binocular vision. In: Adler's Physiology of the eye; clinical application. 9th ed. St Louis, MO: Mosby; 1992.
3. Simonsz HJ. The effect of prolonged monocular occlusion on latent nystagmus in the treatment of amblyopia. Doc Ophthalmol. 1989 Aug;72(3-4):375-84.

Poster #12
Thursday, 9:55 am – 10:55 am

From Bears to Dinosaurs: Lenticular Technology to Measure Stereopsis in Children

Oded Lagstein, MD; Irene Anteby, MD

Department of Ophthalmology, Hadassah Medical Center
Jerusalem, Israel.

Introduction: Stereopsis is usually measured by dissociative methods, affecting fusion. Use of spectacles may reduce compliance in younger children. This pilot study evaluates a new lenticular technology: BEST, or Bernell Evaluation of Stereopsis Test (Bernell Corporation, Mishawaka, IN), a none-dissociative test, to measure fine stereopsis in children, and compare it to the Randot Stereo Test (Stereo Optical, Inc., Chicago, IL).

Methods: A retrospective review of medical records of children examined at the Center for Pediatric Ophthalmology at Hadassah-Hebrew University Medical Center during July to November 2018. All children were evaluated by Randot Test and BEST. Stereopsis scores were compared.

Results: The study included 100 children (3.3 to 17.8 years; mean 8.52±3.18 years), 53% were females, 70% had no strabismus, and mean BCVA was 0.178±0.16 LogMAR. Mean stereopsis scores were statistically better by BEST (78.5±84.7”) compared to Randot (95.2±111.03”), p=0.036. In children younger than 7.8 years (median age of this cohort) mean stereopsis scores were 123.9±138.58” by Randot and 91.4±102.38” by BEST (p=0.036). In children older than 7.8 years there were no differences in stereopsis scores between Randot (67.5±66.16”) and BEST (66.1±61.90"), p=0.956. Gender, heterophoria or visual acuity did not affect differences between test methods (p>0.05).

Discussion: BEST stereopsis scores were comparable to, and possibly slightly better than Randot. In older children BEST and Randot stereopsis scores were similar.

Conclusion: Dissociative tests may reduce compliance in younger children and result in underestimation of true stereopsis. BEST is a promising tool for real life measurements of fine stereopsis in a pediatric clinical practice.

References: 1. Cooper J, Feldman J, Medlin D. (1979). Comparing stereoscopic performance of children using the Titmus, TNO, and Randot stereo tests. Journal of the American Optometric Association. 50, 821–825.
2. Levi DM, Knill DC, Bavelier D. (2015). Stereopsis and amblyopia: A mini-review. Vision Research 114, 17–30.
3. Fricke T. R., & Siderov J. (1997). Stereopsis, stereotests, and their relation to vision screening and clinical practice. Clinical and Experimental Optometry, 80, 165–172.

Poster #13
Thursday, 9:55 am – 10:55 am

Assessing Eye-Related Quality of Life and Functional Vision in Children with Visual Impairment, Using the New PedsEyeQ Pediatric Eye Questionnaires

David A. Leske, MS; Sarah R. Hatt, DBO; Suzanne M. Wernimont, CCRP; Yolanda S. Castañeda, BSN; Laura Liebermann, CO; Christina S. Cheng-Patel, BS, BS; Eileen E. Birch, PhD; Jonathan M. Holmes, BM, BCh

Mayo Clinic
Rochester, Minnesota

Introduction: To report functional vision and eye-related quality of life (ERQOL) in children with bilateral visual impairment (VI), using the newly-developed Pediatric Eye Questionnaires (PedsEyeQ).

Methods: The PedsEyeQs are a set of child-, proxy-, and parent-derived instruments to assess functional vision and ERQOL across childhood eye conditions, with Rasch-scored unidimensional domains. The Child PedsEyeQ was completed by 5-11 year old children, 17 with VI (best-eye acuity worse than 20/70, secondary to retinal, cortical, and corneal conditions) and 22 normal controls. One parent per child completed the Proxy and Parent PedsEyeQs. Domain scores were calculated (range: 0-100) within each questionniare (Child: functional vision, bothered by eyes/vision, social, frustration/worry; Proxy: functional vision, bothered by eyes/vision, social, frustration/worry, eye-care; Parent: impact on parent and family, worry about child's eye condition, worry about child's self-perception/interactions, worry about child's functional vision). Median PedsEyeQ scores were compared.

Results: Child PedsEyeQ scores were significantly lower (worse) for VI children than controls for all but the social domain (P<.008 for each, greatest difference on functional vision, 60 vs 93; P<.001). Proxy PedsEyeQ scores were lower for VI children across all domains (P<.001 for each, greatest difference on functional vision, 25 vs 100; P<.001). Parent PedsEyeQ scores were lower for parents of VI children (P<.001 for each, with the greatest difference on worry about child's visual function 50 vs 100; P<0.001).

Discussion: The new PedsEyeQ demonstrates known-group construct validity.

Conclusion: Visual impairment has a negative impact on functional vision and quality of life for the child and their parents.

References:

Poster #14
Thursday, 9:55 am – 10:55 am

Numeric Equivalents for Alpha Acuities: Salvation for EMR Research Disasters

Robert W. Arnold, MD

Alaska Children's EYE & Strabismus
Anchorage, Alaska

Introduction: You are interested to know how much vision improvement happened with your amblyopia care or cataract surgery? Your techs have labored costly hours to meticulously record patient data. Sounds simple, but your electronic medical record (EMR) CANNOT give you the answer. Why not?

Methods: Multiple EMRs were evaluated to determine whether the visual acuity fields (and refraction and motility fields) are either numeric or alpha formatted. Pediatric pre-verbal vision research(1) and a previous digital conversion(2) were reviewed.

Results: Many prominent EMRs have not formatted visual acuity fields as numeric in part because some adult patients have poor vision characterized as count fingers (CF), hand movement (HM), light projection (LProj), light perception (LP) or no light perception (NLP). Children also have alpha acuities: centered (C), steady (S) and maintained (M). An American and International logMAR paradigm is proposed to simplify digital conversion of typical alpha acuities: CSM (0.44), CS (0.86), C (0.97) in addition to NLP (2.50), LP (2.30), LProj (2.20), HM (2.00), CF (1.70).

Discussion: EMR 'upgrades' may prioritize billing over research, so programmers have defaulted certain data appearance by alpha designating variables that require numeric formats to be analyzable. Reconfiguration of refraction and strabismus field formatting is also needed.

Conclusion: Pediatric ophthalmologists (AAPOS) should lead the effort to scientifically classify infant vision and low vision designations so EMRs have a chance to improve.

References: (1) Mash C, Dobson V: Long-term reliability and predictive validity of the Teller Acuity Card procedure. Vision Res 1998, 38(4):619-626.
(2) Lee JW, Lai JS, Yick DW, Tse RK. Retrospective case series on the long-term visual and intraocular pressure outcomes of phacomorphic glaucoma. Eye (Lond). 2010 Nov;24(11):1675-80.

Poster #15
Thursday, 9:55 am – 10:55 am

The Relationship between Severity of Visual Impairment and Learning Scores of the Blind at the Bangkok School of the Blind

Navapol Kanchanaranya, MD; Pakornkit Phruksaudomchai, MD

Thammasat University
Thailand

Introduction: The development of the education system of the blind student can be considered as an increase in quality of life. At present, there is no definite conclusion about the relationship between visual impairment and cognitive function. The aim is to study the relationship between the severity of visual impairment and learning scores of the blind.

Methods: A cross-sectional descriptive study by collecting information on children in the Bangkok school of the blind was performed. The data was collected by using simple random method and personal data, visual acuity, the severity of visual impairment and learning scores were also collected. Data analysis was performed by frequency, percent, average and analysis of personal factors effect to severity of visual impairment and effect to learning scores by ANOVA statistics.

Results: There were 68 students, divided the severity visual impairment into 4 groups, the largest groups was VA < 3/60 in 63 students (92.6%). The average learning scores was 71.11%. The relationship between personal information and the severity visual impairment was not significant statistical such as gender (p=0.629), education level (p=0.527), preterm labor (p=0.434), underlying disease (p=0.630), eye trauma (p=0.401) or congenital blindness in family (p=0.206). The relationship between the severity visual impairment and learning scores were also not significant statistical (p=0.223).

Discussion: There were no relationships between personal information, the severity visual impairment and learning scores in the blind at the Bangkok school of the blind.

Conclusion: The ability to learn was not correlated with level of visual impairment or personal disabilities.

References: 1. Drobny JV, Anstey KJ, Andrews S. Visual memory testing in older adults with age-related visual decline: a measure of memory performance or visual functioning? Journal of clinical and experimental neuropsychology. 2005;27(4):425-35. Epub 2005/06/21.
2. Henderson RD, Allerhand M, Patton N, Pattie A, Gow AJ, Dhillon B, Starr JM, Deary IJ. Vision and intelligence at age 83 in the Lothian Birth Cohort 1921. Intelligence. 2011; 39:148-154.
3. Hofer SM, Berg S, Era P. Evaluating the interdependence of aging-related changes in visual and auditory acuity, balance, and cognitive functioning. Psychology and Aging. 2003; 18:285-305. [PubMed: 12825777] .

Poster #16
Thursday, 9:55 am – 10:55 am

Accommodation and Refractive Error of Children with Congenital Zika Syndrome

Luiza M. Neves, MD; Julia D. Rossetto, MD, PhD; Lorena Haefeli, MD; Isabel Garcia, MD; Ana Costa, PhD; Jocieli Malacarne, PhD; Maria Moreira, MD, PhD; Andrea Zin, MD, PhD

Instituto Fernandes Figueira-FIOCRUZ
Rio de Janeiro-Brazil

Introduction: It has been suggested in previous studies that infants with Congenital Zika Syndrome (CZS) have an accommodation deficit.(1) The present study aims to evaluate the accommodative response in infants with CZS.

Methods: A retrospective review of records of patients with CZS was conducted between March 2016 and July 2018. Dynamic refraction was performed by retinoscopy at a distance of 50 centimeters and cycloplegic refraction was performed after 30 minutes of two drops of 1% tropicamide and 2.5% phenylephrine in each eye. Spherical equivalent was used. Accommodation was obtained by the difference between static and dynamic refraction.

Results: 49 infants were included. 80% of mother-infant pairs had RT-PCR confirmation of Zika virus infection (39/49). Females accounted for 31 (63%), the median age at exam was 2,13 months (IQR 25-75). Central nerve system (CNS) abnormalities were diagnosed in 86% of subjects (42/49), 38 with microcephaly. Fundoscopic abnormalities were seen in 57% (28/49). Median dynamic refraction was -2.00 D (IQR -4.00D-0.00), median cycloplegic refraction was 1.20D (IQR -5.00D-+2.25 D), and median accommodation response was 2.00D (IQR +1.25D-+4.5D).

Discussion: Few previous publications quantifying the accommodative response of infants showed that the accommodative performance of infants achieves adult-like characteristics by the 3rd-4th postnatal month.2-4 Haynes et al. showed an accommodative response of 5D at 0 to 1 month-old and Currie et al. a response greater than 4.0D among infants at 1.5 and 3 months of age.

Conclusion: Accommodation in infants with CZS is inferior to that found in healthy infants of similar age.

References: 1. Ventura LO, Ventura CV, Lawrence L, et al. Visual impairment in children with congenital Zika syndrome. Journal of AAPOS : the official publication of the American Association for Pediatric Ophthalmology and Strabismus. 2017;21(4):295-299.e292.
2. Brookman KE. Ocular accommodation in human infants. American journal of optometry and physiological optics. 1983;60(2):91-99.
3. Banks MS. The development of visual accommodation during early infancy. Child Dev. 1980;51(3):646-666.
4. Haynes H, White BL, Held R. Visual Accommodation in Human Infants. Science. 1965;148(3669):528-530.

Poster #17
Thursday, 9:55 am – 10:55 am

A 3D-Printed Tool For Improved Retinoscopy Experience

Richard W. Helms, PhD; Maryo C. Kohen, MD; Faruk H. Orge, MD

University Hospitals Rainbow Babies and Children's
Cleveland, OH

Introduction: Loose-lens retinoscopy is a common method for refracting patients who are unable to respond to the examiner due to age, disability, or sedation. Because it requires sustained gaze at the retinoscope, it can be a difficult, time-consuming exam. We present a retinoscope adapter, which provides a dynamic, entertaining fixation target while giving the clinician an unobstructed view of the reflex.

Methods: The key components of our device are a mirror and a 3D-printed tray for holding a video source. The mirror is positioned to reflect the source image along the axis of the retinoscope. Multiple clinicians have used this device with pediatric patients and have provided feedback regarding ease-of-use and patient response.
Results: Based on early tests, physicians report that our device can shorten the time needed to perform retinoscopy and make the procedure more enjoyable for the patient and the provider.

Discussion: Toddlers are the most challenging group to assess for ophthalmic anomalies due to their limited attention span and hyperactive behavior. Our device naturally draws their attention through a familiar audio-visual stimulus (they can watch their own phone through the device). Clinicians have reported that, for many children, this allows them extra time to perform a more thorough exam and gather valuable patient data. Further refinement will broaden the effectiveness of the device and improve its ease of use.

Conclusion: We have shown that an affordable, 3D-printed device can make retinoscopy more pleasant for the patient and the provider, and provide more time to perform this difficult exam.

References: Arshad J, Helms R, Orge F, Sayegh R. Educational Value of a 3D Printer in Ophthalmology Training. Journal of Academic Ophthalmology. 2018;10(01):e69-e71. doi:10.1055/s-0038-1653973.
Wallace DK, Carlin DS, Wright JD. Evaluation of the Accuracy of Estimation Retinoscopy. Journal of American Association for Pediatric Ophthalmology and Strabismus. 2006;10(3):232-236. doi:10.1016/j.jaapos.2006.01.214.

Poster #18
Thursday, 9:55 am – 10:55 am

Estimating Cycloplegic Retinoscopy by School Bus Accommodation-Relaxing Skiascopy (SBA-RS)

Andrew W. Arnold, OMS II; Stephanie L. Arnold, OMS II; Jacob H. Sprano, OMS IV; Robert W. Arnold, MD

Alaska Children's EYE & Strabismus
Anchorage, Alaska

Introduction: Accurate estimation of hyperopia as well as astigmatism axis and magnitude are challenging in delayed children. Conventional skiascopy holds rows of increasing power +/- lenses vertically in front of one eye. The SBA-RS child-friendly design holds convex lenses horizontally with a higher plus power fogging over the non-tested eye to relax accommodation.

Methods: In a prospective IRB study, patients had Retinomax autorefraction and SBA-RS refraction as a part of comprehensive pediatric eye examination with cycloplegia using cyclopentolate 1%.

Results: We examined 504 patients (0.3-66 years, mean 7.9±9, median 6 years) of which 124 had delays. For astigmatism >1D, cylinder power within 1D of exam was achieved by 93% with SBA-RS and 85% with Retinomax, and axis within 10° in 90% with the bus versus 75% with Retinomax. Hyperopia >1D was found in 141; cyclo refraction was +3.03±1.8D and cyclo-Retinomax 2.85±2.0D. SBA-RS without cycloplegia was 2.47±1.7D with neuro-delayed patients 0.36 diopters less than normals. Spherical equivalent actual refraction (Y) was predicted by SBA-RS (x): y=0.98x +0.12, R2=0.95 right eye and y=0.99x+0.17, R2=0.94 left eye.

Discussion: Accommodation-relaxing binocular horizontal skiascopy very precisely estimates astigmatism power and axis and only lags cycloplegic refraction by about 0.5D in hyperopic patients fairly independent of neurodevelopmental delay.

Conclusion: Child-friendly, convex skiascopy can quickly estimate refraction even in many delayed patients reducing the need for cycloplegia.

References:

Poster #19
Thursday, 9:55 am – 10:55 am

A Rule of Astigmatism in Pediatric Subluxated Crystalline Lens

Ran David, MD, PhD; Ori Berger, MD; Hadas Mechoulam, MD; Evelyne Cohen, CO; Ilana Karshai, CO; Irene Anteby, MD

Center for Pediatric Ophthalmology, Department of Ophthalmology, Hadassah-Hebrew University Medical Center Jerusalem, Israel

Introduction: Crystalline lens subluxation leads to refractive error typically resulting in myopic-shift and astigmatism. Retinoscopy is challenging due to phaco/iridodonesis and distorted reflex. |This study explored simplified rules of thumb to help determining the correct refraction. We postulated that the expected axis of astigmatism should be parallel to the direction of subluxation.

Methods: We performed a retrospective study of patients (<19 years old), with dislocated/subluxated lens who underwent lensectomy at Hadassah University Medical Center between 1980-2016. Traumatic cases were excluded. In each case, the correlation between the axis of astigmatism and direction of subluxation was evaluated.

Results: Forty-three eyes were included. The average age was 67.40 (range 10-230) months. The average pre-op astigmatism (-3.90D, range -0.75 - -8.75D) was reduced significantly after lensectomy (-0.68D, range -0.5 - -2D). The average pre-op SE was myopic (-5.93D, range -18.75 - +17D). In each direction the pre-op axis of astigmatism was found to be in 93.33% cases horizontally in superior; 76.92% obliquely in supero-temporal; 100% vertically in temporal; 100% obliquely in infero-temporal; 100% horizontally in inferior; 100% vertically in nasal; 66.67% obliquely in supero-nasal, subluxations. Totally, 86% of measured axis were inside those expected ranges in all directions.

Discussion: We found a high correlation between the direction of subluxation and the astigmatic axis before surgery for pediatric lens subluxation. We postulate that the high and irregular astigmatism in subluxation is mainly lenticular.

Conclusion: As a rule of thumb, the astigmatic axis is expected to be parallel to the direction of subluxation.

References: 1) Wu-Chen WY, Letson RD, Summers CG. Functional and structural outcomes following lensectomy for ectopia lentis. Journal of American Association for Pediatric Ophthalmology and Strabismus. 2005 Aug 31;9(4):353-7.

2) Anteby I, Isaac M, BenEzra D. Hereditary subluxated lenses: visual performances and long-term follow-up after surgery. Ophthalmology. 2003 Jul 31;110(7):1344-8.

3) Konradsen TR, Koivula A, Kugelberg M, Zetterström C. Corneal curvature, pachymetry, and endothelial cell density in Marfan syndrome. Acta ophthalmologica. 2012 Jun 1;90(4):375-9.

Poster #20
Thursday, 9:55 am – 10:55 am

Implantation of Toric Phakic Intraocular Lenses To Treat Astigmatism in Special Needs Children

Nicholas Faron; Lawrence Tychsen, MD; James Hoekel, OD

Washington University in St. Louis School of Medicine
St. Louis, MO

Introduction: Reports of using toric phakic intraocular lenses (T-Ph IOLs) to treat compound myopic & hyperopic astigmatism in children are few. Here we report use of T-Ph IOLs to treat a series of children with amblyopiogenic astigmatism who had difficulties with spectacle or contact lens wear.

Methods: Clinical outcome data were collated prospectively in 6 myopic-astigmatic children (11 eyes) and 2 hyperopic-astigmatic children (4 eyes) treated for isoametropic or anisometropic amblyopia using T-Ph IOLs. Three children had cerebral palsy, two had developmental delay, two had a history of extreme prematurity with ROP, and three had encephalopathy-related optic neuropathy. The mean age at refractive surgery was 13.1 yrs (range 7 to 19 yrs); mean follow-up was 1.82 years (range 1-3.5 yrs).

Results: Myopic spherical refractive error averaged -7.1 ± 3.5 D (range -3 to -12 D) and hyperopic spherical error averaged + 9.1 ± 1.0 D (range 7.8 to 19 D). Average astigmatism in myopes was 5.4 ± 1.6 D (range 2.5 to 8 D) and in hyperopes 3.9 ± 0.9 D (range 3 to 4.3 D). At last follow-up, spherical error was reduced to – 0.4 ± 0.7 D in myopes and + 0.38 ± 1.3 D in hyperopes. Astigmatic error was reduced to an average 1.5 ± 1.5 D in myopes and and 1.8 ± 1.5 D in hyperopes. Myopic and hyperopic UCVA improved 1.05 logMAR and 1.0 logMAR; CDVA improved 0.12 logMAR & 0.06 logMAR, respectively. One eye required re-enclavation of an IOL haptic following blunt eye trauma and one eye required additional treatment using excimer laser PRK for residual ametropia. Endothelial cell density measurements did not show accelerated loss.

Discussion: Toric phakic IOL refractive surgery is an effective means for improving visual function and quality of life in highly ametropic children who have difficulties wearing spectacles. Visual acuity improved substantially and refractive error reduced substantially compared to pre-operative measurements.

Conclusion: Toric phakic IOL refractive surgery is an effective means for improving visual function and quality of life in highly ametropic children who have difficulties wearing spectacles. Visual acuity improved substantially and refractive error reduced substantially compared to pre-operative measurements.

References:

Poster #21
Thursday, 9:55 am – 10:55 am

Emmetropization During Early Childhood

Yvette L. Schein; Yinxi Yu; Gui-shuang Ying; Gil Binenbaum

The Children's Hospital of Philadelphia
Philadelphia, PA

Introduction: Some ophthalmologists delay glasses during infancy, anticipating possible emmetropization. We determined the degree and timing of emmetropization of refractive error in early childhood.

Methods: Retrospective cohort study of children undergoing cycloplegic refraction at ages 6-11 months and 12-24 months, minimum 3 months apart. Children with cataract/other eye surgery were excluded. The primary outcome was 'change towards emmetropia' (CTE) (positive value defined as change in refractive error towards zero).

Results: 730 eyes of 375 children were categorized by initial spherical equivalent, cylindrical, and anisometropic refractive error. Mean 'CTE/month' was [myopia -5/more] -0.06D; [myopia -2.50/-4.75] +0.07D; [myopia -0.25/-2.25] -0.01D; [hyperopia +0.25/+1.50] 0.00D; [hyperopia +1.75/+3.25] +0.06D; [hyperopia +3.50/+5.75] +0.11D; [hyperopia +6/more] +0.03D; [cylinder 0/+1.25] -0.01D; [cylinder +1.50/+2.75] +0.08D; [cylinder +3/more] +0.16D. For myopia>/=-2.50, emmetropization peaked at 7-12 months, then was minimal. For hyperopia>/=+1.75 and cylinder>/=+1.5, emmetropization continued steadily throughout 7-20 months. 96%(myopia), 88%(hyperopia), 42%(astigmatism) of children surpassing AAO glasses-prescribing-levels prior to 12 months subsequently surpassed guidelines for 12-24 months.

Discussion: Degree of emmetropization in early childhood tends to increase with increasing magnitude of refractive error for low to moderate amounts of myopia and hyperopia, and for all levels of astigmatism. However, high hyperopia decreases less, and high myopia tends to worsen over time.

Conclusion: Infants under age 1 year with myopia and hyperopia surpassing AAO glasses-prescribing thresholds are unlikely to emmetropize sufficiently to no longer need glasses. In contrast, over one half of infants with high astigmatism may emmetropize sufficiently, so delaying glasses for such infants is reasonable.

References:

Poster #22
Thursday, 9:55 am – 10:55 am

Verification of Myopia Growth Chart Using Pediatric Cohort Data

Dae Hee Kim, MD (1); Hyun Taek Lim, MD, PhD (2)

Department of Ophthalmology, Konyang University, Kim's Eye Hospital, Seoul, Republic of Korea (1)
Department of Ophthalmology, University of Ulsan College of Medicine, Asan Medical Center, Seoul, Republic of Korea(2)

Introduction: Myopia growth chart, which was derived from refractive error data of national health survey using percentile concept of growth chart, provided age-specific range and prediction for refractive error in childhood. Due to its limitation of cross-sectional data usage, myopia growth chart needed to be verified with cohort data for its predictive value.

Methods: We included subjects aged from 5 to 20 years who underwent at least two exams of cycloplegic refraction with the interval of more than 1 year. We collected spherical equivalents (SE) and corresponding percentiles referring to the myopia growth chart of the first and last cycloplegic refraction data. We calculated the percentile change between the first and the last exam. (percentile deviation) We calculated the difference between a predicted SE using the percentile of the first exam and an actual SE at the last exam. (spherical equivalent deviation)

Results: We investigated 1418 eyes of 709 subjects including 406 females. Mean ages at the first and last exam were 6.3 and 9.3 years. Mean follow-up period was 3.0 years. Within 10 percentile deviation were 87.4 % of all subjects. The mean percentile deviation was 6.1 percentile. The mean spherical equivalent deviation was 1.13 ± 1.04 diopters.

Discussion: Myopia growth chart predicted the refractive change with average error of 6.1 percentile or 1.13 diopters against the actual measurement. The prediction of myopia growth chart was more hyperopic than the actual measurement.

Conclusion: Myopia growth chart yielded reliable prediction results when verified against pediatric cohort data.

References: 1. Kim DH, HT Lim. Myopia growth chart based on a population-based survey (KNHANES IV-V) - a novel prediction model of myopic progression in childhood. J Pediatr Ophthalmol Strabismus. In press.
2. Jung SI, Han J, Kwon JW, Kim DG, Kim DH, Lim HT. Analysis of myopic progression in childhood using the Korea National Health and Nutrition Examination Survey. J Korean Ophthalmol Soc. 2016;57(9):1430-1434.

Poster #23
Thursday, 9:55 am – 10:55 am

Practice Patterns to Decrease Myopia Progression Differ among Pediatric Ophthalmologists around the World

Eedy Mezer, MD; Ari Leshno, MD; Tamara Wygnanski-Jaffe, MD; Sonal K. Farzavandi, MD;
Rosario Gomez-de-Liano, MD, PhD; Derek T. Sprunger, MD

Rambam Health Care Campus, Technion - Israel Institute of Technology
Haifa, Israel

Introduction: Myopia is a worldwide epidemic. Multiple treatments have been offered to decrease myopia progression. The purpose of this study was to compare and analyze demographic variations in the practice patterns utilized globally by pediatric ophthalmologists to decrease the progression of myopia.

Methods: Worldwide responses to a questionnaire (n=794) were analyzed after subcategorization to pharmacological, optical and behavioral treatment modalities as effective or ineffective based on current literature (1,2).

Results: Treatment rates varied significantly between geographical regions (mean 57%, range: 39 - 89%, P<0.001). The majority of those, who had chosen to treat, utilized at least one effective mode of treatment (98%, p=0.16). Europe held the lowest rate of respondents offering an effective pharmacological treatment (82% versus 97%, average). Effective optical treatment rates varied significantly (P<0.001), from 15.2% in Central and South America to 55.3% in the Far East. Most respondents advocated behavioral modifications (average 92%, range: 86%-100%). A combination of treatment modalities was most popular (95%) and all the 3 treatment modalities were offered by 56% of ophthalmologists, although these rates varied significantly between regions (P<0.001). Rates of effective treatment combinations were 77%, nonetheless, all 3 types of effective treatment were incorporated by 21%. Demographic variation was significant (P<0.001)

Discussion: Treatment rates to decrease myopia progression varied considerably among pediatric ophthalmologists globally. Certain types of treatment and combinations were more popular. In some instances, treatment included unsupported evidence-based options.

Conclusion: Further efforts to provide pediatric ophthalmologists with evidence-based data might universally improve their ability to effectively treat to decrease myopia progression.

References: 1. Pineles SL, Kraker RT, VanderVeen DK, Hutchinson AK, Galvin JA, Wilson LB, Lambert SR. Atropine for the Prevention of Myopia Progression in Children: A Report by the American Academy of Ophthalmology. Ophthalmology. 2017 Dec;124(12):1857-1866

2. Morgan IG, French AN, Ashby RS, Guo X, Ding X, He M, Rose KA. The epidemics of myopia: Aetiology and prevention. Prog Retin Eye Res. 2018 Jan;62:134-149

Poster #24
Thursday, 9:55 am – 10:55 am

Amplified Esotropia Syndrome: Long-Standing, Large-Angle Esotropia Causing Laxity of the Lateral Rectus-Superior Rectus Band Leading to Progressive Esotropia

Phillip A. Tenzel; Ekaterina Semenova; Michael R. Chua; Mary T. Labowsky; Steven E. Rosenberg

New York Eye and Ear Infirmary of Mount Sinai
New York City, NY, USA

Introduction: Lateral rectus-superior rectus (LR-SR) band laxity has been implicated in multiple forms of strabismus1,2; we present chronic, large-angle esotropia as a novel cause of this LR-SR laxity.

Methods: This is a retrospective chart review of patients with long-standing esotropia who underwent surgical correction that included LR-SR myopexy. All surgeries were performed by a single surgeon with residents. Patients with high axial myopia (greater than -8.00 spherical equivalent) were excluded.

Results: Seven patients met inclusion criteria; all were male from 12 to 62 years old. Preoperative esotropia ranged from 30 to 90 prism diopters (PD) in primary at distance and 35-95PD at near. None had measurable stereoacuity or fusion on Worth 4 dot testing prior to surgery. Two patients had previous traditional strabismus surgery resulting in large undercorrections, with second surgeries including LR-SR myopexy.

At last post-op follow-up (1 to 50 months, mean 17.3), alignment in primary gaze was <10PD in all patients at both distance and near. Two patients showed <400 arcseconds of stereoacuity, and three patients demonstrated fusion on Worth 4 Dot.

Discussion: In chronic large-angle esotropia, we suspect the posterior globe stretches the LR-SR band, causing a heavy-eye-like syndrome. The importance of recognizing situational restriction preoperatively is highlighted by the two cases in which traditional strabismus surgery led to large undercorrection.

Conclusion: Long-standing, large-angle esotropia may be a cause of lateral rectus inferodisplacement, which may lead to a progressive or variable esotropia. Inclusion of LR-SR myopexy should be considered in the surgical plan for these patients.

References: Tan RJ, Demer JL. Heavy eye syndrome versus sagging eye syndrome in high myopia. J AAPOS. 2015 Dec;19(6):500-6.

Yamaguchi M, Yokoyama T, Shiraki K. Surgical procedure for correcting globe dislocation in highly myopic strabismus. Am J Ophthalmol. 2009;149:341.

Poster #25
Thursday, 9:55 am – 10:55 am

Genetic Associations in Esotropia: Genome-Wide Association Study and Copy Number Variation

Mary C. Whitman, MD/PhD; Sherin Shaaban, MD/PhD; Sarah MacKinnon; Wai-Man Chan;
Strabismus Genetics Research Consortium; David A. Mackey; David G. Hunter, MD/PhD; Elizabeth C. Engle

Boston Children's Hospital, Harvard Medical School
Boston, MA

Introduction: Esotropia is the most common form of strabismus in European ancestry populations. Population, twin and family studies indicate a genetic predisposition, but no causative genes have been identified. Our recently published genome-wide association study (GWAS) identified a risk locus for non-accommodative esotropia in intron 1 of the WRB (tryptophan-rich basic protein) gene on chromosome 21. The risk SNP is differentially methylated and there is a skew toward paternal inheritance of the risk allele.

Methods: Using the cohort of European ancestry esotropia patients included in the previous GWAS, we examined a subset of 1615 individuals with esotropia (both accommodative and non-accommodative) for copy number variants (CNVs) using PennCNV and QuantiSNP and compared to 3922 controls. Statistical comparisons were made using 1 million permutations in plink software. Significant CNVs were validated using Digital Droplet PCR (ddPCR).

Results: A significant association (p=1x10-6) with esotropia was found for four recurrent DNA duplications (involving areas of chromosomes 2, 4, 9, and 10) encompassing 22 genes. Each duplication was validated in esotropia patients by ddPCR. 127 of the 1615 patients had one or more of these four duplications.

Discussion: This is the first study to report associations of esotropia with DNA CNVs. Esotropia is likely inherited as a complex trait, with multiple genetic variants contributing to risk. These duplications may alter gene dosages or may disrupt genes or regulatory regions at their insertion sites.

Conclusion: Future studies of the genes and regulatory regions involved and disrupted by the DNA duplications should provide insight into the pathophysiology of esotropia.

References: Shaaban S, MacKinnon S, Andrews C, Staffieri SE, Maconachie GDE, Chan WM, Whitman MC, Morton SU, Yazar S, MacGregor S, Elder JE, Traboulsi EI, Gottlob I, Hewitt AW, Strabismus Genetics Research Consortium, Hunter DG, Mackey DA, Engle EC. Genome-Wide Association Study Identifies a Susceptibility Locus for Comitant Esotropia and Suggests a Parent-of-Origin Effect. Investigative ophthalmology & visual science. 2018;59:4054-64.

Poster #26
Thursday, 9:55 am – 10:55 am

Histopathologic Study of Accessory Orbital Band in Type I Duane Syndrome

Federico Velez, MD; Muhammad Hassaan Ali, MD; Stacy Pineles, MD; Ben Glasgow, MD; Anika Tandon, MD

UCLA Stein Eye Institute
Los Angeles, CA, USA

Introduction: Accessory bands are rare orbital structures associated with restrictive strabismus. They are usually described as an incidental intraoperative finding or with the use of high resolution orbital imaging.

Methods: During surgery for esotropic Duane syndrome, a tough fibrous band was discovered, inserting 2mm posterior to the medial rectus insertion. After extirpation of the band, a detailed histopathologic study was conducted that included stains for hematoxylin and eosin (H&E), polarization to identify collagen fibers, Masson trichrome stain, elastic Masson trichrome, Sirius red and immunohistochemistry for anti-muscle-specific actin.

Results: Sections stained with H&E revealed compressed soft tissue with closely packed fibers that showed birefringence on polarization. In one focal area striated muscle was seen with faint cross striations and peripheral nuclei. Masson trichrome staining showed marked red stain and polarized light showed birefringence. Sirius red stain showed more staining than the Masson trichrome and demonstrated birefringence and dichroism with polarized light. The histochemical and polarization findings of predominance of collagen in the band were confirmed by the presence of only a small area of reactivity for anti-muscle-specific actin.

Discussion: Orbital bands have been reported as tough fibrous bands located deep to rectus muscles, soft tissue fibers arising from the orbital apex, or anomalous muscular tissues originating from extraocular muscles with separate insertions. The histopathological findings presented here are useful in classifying bands into aforementioned categories.

Conclusion: Immuno-histological evaluation of accessory orbital bands confirms the presence of collagen with small areas of muscle tissue in these structures.

References: 1. Spierer A, Desatnik H, Barishak YR. Aberrant extraocular fibrous band as a cause of strabismus. Am J Ophthalmol. 1991;111(3):370–1.
2. Lueder GT, Dunbar JA, Soltau JB, Lee BCP, McDermott M. Vertical strabismus resulting from an anomalous extraocular muscle. J Am Assoc Pediatr Ophthalmol Strabismus {JAAPOS}. 1998;2(2):126–8.
3. Özkan SB, Çakmak H, Dayanir V. Fibrotic superior oblique and superior rectus muscles with an accessory tissue band. J Am Assoc Pediatr Ophthalmol Strabismus {JAAPOS}. 2007;11(5):491–4.

Poster #27
Thursday, 9:55 am – 10:55 am

'Paradoxical' Duane Retraction Syndrome with Abduction Deficit and Exotropia: Natural History and Surgical Management

Mary E. Runkle, MD; Terry Schwartz, MD; Virginia M. Utz, MD; Stephen Kraft, MD; Elias I. Traboulsi, MD; Razek Coussa, MD

Cincinnati Children's Hospital
Cincinnati, Ohio

Introduction: A less common presentation of Duane retraction syndrome (DRS) type 1 occurs when patients exhibit intermittent exotropia (IXT) with an abduction deficit resulting in a gaze preference toward the adduction deficit to neutralize the exodeviation. This study reviews the natural history and surgical outcomes of patients with this strabismus pattern, managed medically or surgically.

Methods: A retrospective, multi-center case series of nine patients with this strabismus pattern was completed evaluating the clinical presentation and course, preoperative and postoperative exodeviation angle, degree of face turn, and ductions.

Results: Seven of nine patients underwent unilateral single horizontal lateral rectus recession, averaging 7.75±2.04 mm (range 5-10 mm). The exodeviation in primary position (preoperative: 18.83±4.92 PD, postoperative: 5.00±12.25 PD, p=0.03, n=6) and head turn improved significantly (preoperative: 18±14 degrees, postoperative: 2±2 degrees, p=0.05, n=5). However, limitation in abduction increased, although not statistically significant (preoperative: -2.25±0.88, postoperative: -3.17±1.33, p=0.14, n=6).

Discussion: Patients with DRS Type 1 with IXT and abduction deficits require special surgical considerations, as recession to improve the exodeviation may further exacerbate decreased abduction in exchange for a more functional primary position alignment and head position[1]. Surgery was performed based on the magnitude of the deviation in combination with the degree of face turn.

Conclusion: Unilateral single horizontal rectus muscle recession offers improvement in alignment in primary gaze and head turn, although at the sacrifice of reduced abduction. Further prospective studies are needed to evaluate medical and surgical outcomes, including quality of life.

References: 1. Lee, Ju-Yeun, et al. "Lateral Rectus Muscle Recession for Intermittent Exotropia with Anomalous Head Position in Type 1 Duane's Retraction Syndrome." Graefe's Archive for Clinical and Experimental Ophthalmology, 2018, doi:10.1007/s00417-018-4079-5.

Poster #28
Thursday, 9:55 am – 10:55 am

Evaluation of Factors Affecting Sensory Outcome in Patients with Intermittent Exotropia

Zane D. Foster; Mohamed A. Hussein; Anthony Quesada; David K. Coats

Baylor College of Medicine
Houston, TX

Introduction: This study explored factors that could adversely affect sensory outcome in patients with intermittent exotropia.

Methods: We retrospectively reviewed the charts of patients diagnosed with intermittent exotropia who had at least 6 months of follow up. Exclusion criteria included: anisometropia, ocular pathology, developmental delays, or inability perform stereoacuity testing. Analysis included the following data points: age; near and distant deviation; stereoacuity; degree of control of the deviation; duration of exotropia; presence or absence of strabismus amblyopia; and modality of treatment. Stereoacuity testing at the final examination was the primary outcome. Patients were divided into 3 groups based on stereoacuity results at the final visit: poor (>200 arc seconds), fair (40-200 arc seconds) and excellent (40 arc seconds). Logarithmic regression was performed to determine factors within the patients' clinical profile that may adversely affect the final sensory outcome.

Results: 860 patients were reviewed. 219 qualified for analysis. 57 patients (26.4%) had excellent sensory outcomes, 135 (61.6%) had fair outcomes, and 27 (12%) had poor outcomes. After adjusting for all other factors, a larger angle of near deviation at the time of the initial exam was the only factor found to be significantly associated with poor sensory outcome ($P = 0.0296$).

Discussion: A larger angle of near deviation at initial visit was associated with poor sensory outcome in patients with intermittent exotropia.

Conclusion: Early intervention for intermittent exotropia may be needed for patients presenting with an initial large angle of near deviation.

References:

Poster #29
Thursday, 9:55 am – 10:55 am

Block Building Performance Test Using a 3-Dimensional Virtual Reality System in Children with Intermittent Exotropia

Seung Ah Chung, MD; Jaewon Choi; Seungchan Jeong; Jeonggil Ko, PhD; Jong Bok Lee, MD

Department of Ophthalmology, Ajou University School of Medicine
Suwon, South Korea

Introduction: Block building is a typical activity that requires three-dimensional (3D) spatial perception. We developed a novel virtual reality (VR)-based display system that facilitates the 3D block building performance test with both eyes stimulated separately and simultaneously. We evaluated the performance ability in children with intermittent exotropia (IXT).

Methods: Thirty nine children with intermittent exotropia aged 5 to 12 years were compared to 37 age-matched normal controls. Children performed a block building while fitted with the 3D head mounted VR display with eye and hand movement recording system. Time and accuracy to stack five cube blocks of different sizes in order were evaluated after 2 minutes of alternative stimulation for the presentation of IXT.

Results: Children with a mean age of 8.6 years had 33.3 prism diopters of IXT. Children with IXT showed larger horizontal bias than controls (85.5 ± 15.9 mm vs 40.8 ± 8.9 mm, $P < 0.001$); similar vertical bias with controls (65.7 ± 11.8 mm vs 55.1 ± 6.4 mm, $P = 0.708$). Children with IXT performed at a comparable duration to controls (146.0 ± 12.5 secs vs 116.3 ± 9.1 secs, $P = 0.104$). The accuracy and duration in children with IXT did not improve 3 months after muscle surgery (62.8 ± 12.5 mm for horizontal bias, 52.4 ± 8.3 mm for vertical bias, and 135.0 ± 24.2 secs for performance duration).

Discussion: In children with IXT, the bias of spatial perception related to horizontal disparity was measured during binocular viewing using a 3D VR display and even after surgery.

Conclusion: The block building performance test using a 3D VR system can be used to assess the binocular vision of intermittent exotropia.

References: 1.Newman SD, Hansen MT, Gutierrez A. An fMRI study of the impact of block building and board games on spatial ability. Front Psychol 2016;7:1278.
2.Kanonidou E, Gottlob I, Proudlock FA. The effect of font size on reading performance in strabismic amblyopia: an eye movement investigation. Invest Ophthalmol Vis Sci 2014;55:451-9.

Poster #30
Thursday, 9:55 am – 10:55 am

A Prospective Observational Study of Adult Convergence Insufficiency

David K. Wallace, MD, MPH; S. Ayse Erzurum, MD; Elizabeth L. Lazar, MS, MPH; Susan A. Cotter, OD, MS; Raymond T. Kraker, MSPH; Jonathan M. Holmes, MD; Eric R. Crouch, MD; Christina A. Esposito, OD; Erin C. Jenewein, OD, MS; Ingryd Lorenzana, OD; Yi Pang, OD, PhD; Dashaini V. Retnasothie, OD, MS

Pediatric Eye Disease Investigator Group
Jaeb Center for Health Research, Tampa, Florida

Introduction: Few prospective studies report long-term treatment outcomes for adults with convergence insufficiency.

Methods: Adults with symptomatic convergence insufficiency (near exodeviation >/=4PD measuring at least 4PD larger than at distance, distance exodeviation </=15PD, receded near point of convergence, reduced near convergence amplitudes, and a Convergence Insufficiency Symptom Survey (CISS) score >/=21 points) were prospectively enrolled into a non-randomized 1-year observational study of newly (not used in last year) prescribed and investigator-determined treatment with prism, orthoptic exercises, botulinum toxin injection, or surgery. The primary outcome was “symptom success” (CISS score <21 and improved >/=9 points from baseline) measured 10-weeks and 1-year post-treatment initiation.

Results: For the 81 participants, the treatment prescribed was orthoptic exercises (n=50, 62%), base-in prism (n=25, 31%), base-out prism (n=1, 1%), surgery (n=3, 4%), or botulinum toxin (n=2, 2%). At 10-weeks, symptom success rates were 21% [95% confidence interval (CI) =10% to 35%] for orthoptic exercises and 46% (95% CI=26% to 67%) for base-in prism. At 1-year, success was 55% (95% CI =38% to 71%) for orthoptic exercises and 50% (95% CI =26% to 74%) for base-in prism.

Discussion: Success rates cannot be directly compared because participants were not randomly assigned to treatment. Approximately 50% of those prescribed orthoptic exercises and those prescribed base-in prism reported improvement in their symptoms 1 year post-treatment initiation.

Conclusion: Treatment with orthoptic exercises or base-in prism may result in improved symptoms in adults with convergence insufficiency when assessed 1 year after prescribing treatment. These data may be used to inform clinical trial development and for counseling patients.

References:

Poster #31
Thursday, 9:55 am – 10:55 am

Objective Convergence Insufficiency and Fusional Convergence Amplitude Measurements with an Eye Tracking Based Device

Tamara Wygnanski-Jaffe, MD; Michael Belkin, MD; Ran Yam; Dan Oz; Oren Yehezkel, PhD

Goldschleger Eye Institute and Research Institute,Sackler Faculty of Medicine, Novasight Ltd.
Sheba Medical Center, Tel Hashomer, Tel- Aviv University and Airport City, Israel

Introduction: Convergence insufficiency (CI) is a common binocular vision disorder of substantial clinical significance which may cause asthenopia, diplopia, headaches, and blurred vision at near.1

Methods: An automatic eye tracking - based test was developed for measuring both phoria and fusional convergence amplitudes at near in order to evaluate the presence of CI. The new device was compared to the conventional manual test, the magnitude and direction of the phoria were first measured by performing manual cover test and fusional reserves were measured using a prism bar. This was followed by automated cover testing using alternate occluding glasses while monitoring eye movements using an eye tracker. Automated fusional convergence was performed using dichoptic stimuli of an animated movie that were viewed through 3D glasses and continuously measured. While the subject watched a short animation movie, each monocular presentation was shifted inward (nasally) inducing a convergence type movement. In order to avoid diplopia, the subject converges intuitively making instructions unnecessary.

Results: Fifty subjects were tested. A correlation of 90% was found between the automatic test and conventional phoria testing using prisms. In addition, a high correlation was found between the automatic test and conventional testing using prisms for convergence amplitude testing.

Discussion: This tested device, suitable for subjects 3 years of age, provides fast, objective and accurate measurements required for CI testing.

Conclusion: This novel device may provide automated assessment of CI, increasing work efficiency in established clinics and in locations in which these services are unavailable.

References: 1. Ghadban,R.,Martinez,J., Diehl, N., Mohney, B.G.
The Incidence and Clinical Characteristics of Adult-Onset Convergence Insufficiency.Ophthalmology.2015;122:1056-1059.

Poster #32
Thursday, 9:55 am – 10:55 am

'Exotropic' Heavy Eye Syndrome in Unilateral High Axial Myopia

Dina H. Hassanein, MD, FRCS; Ahmed R. Awadein, MD, FRCS

Ophthalmology Department, Cairo University
Cairo, Egypt

Introduction: To describe a pattern of combined exotropia and hypotropia with limited elevation in abduction in patients with unilateral high axial myopia, and to suggest a surgical approach for their management.

Methods: A retrospective observation study was performed for patients presenting with unilateral combined exotropia and hypotropia with high axial myopia in the deviating eye. The cycloplegic refraction, visual acuity, ocular motility, and orbital imaging findings were evaluated. For patients who had surgery, the intraoperative findings, and their surgical outcome were analyzed.

Results: A total of 14 patients were identified (mean age 29.9±14.6years). The mean spherical equivalent (SE) and axial length of the deviated eyes were 13.6±9 diopters and 28.3±1.7mm respectively. The mean horizontal and vertical angles of deviation in the primary gaze were 46.5±12.1 (range,25–60) and 21.1±6.5 (range,15–35) respectively. All patients had a V-pattern with limitation of elevation in abduction. MRI showed no evident displacement of the lateral rectus muscles. Seven patients(50%)had surgical intervention. In 6 cases the lateral rectus was displaced inferiorly by a mean of 2.5mm (range,2-4 mm) and was recessed and transposed 8mm upwards. The muscle was then fixated to the sclera with a non-absorbable polyester suture 2-4 mm behind its new insertion. Successful surgical outcome was achieved in 5 cases(83%).

Discussion: Combined exotropia and hypotropia associated with high myopia shows an overlap in its clinical presentation with heavy eye syndrome.

Conclusion: Although not evident in orbital imaging, downward displacement of lateral rectus muscle was found intraoperatively in patients showing this pattern of strabismus.|

References: 1. Rutar T, Demer JL. 'Heavy Eye' syndrome in the absence of high myopia: a connective tissue degeneration in elderly strabismic patients. J AAPOS. 2009;13:36-44.
2. Yokoyama T, Ataka S, Tabuchi H, Shiraki K, Miki T. Treatment of progressive esotropia caused by high myopia—a new surgical procedure based on its pathogenesis. In: de Faber J-T, editor. Transactions: 27th Meeting, European Strabismological Association, Florence, Italy, 2001. Lisse (Netherlands): Swets & Zeitlinger; 2002:145-8.
3. Krizok TH, Kaufmann H, Traupe H. New approach in strabismus surgery in high myopia. Br J Ophthalmol 1997;81:617-18.

Poster #33
Thursday, 9:55 am – 10:55 am

Globe Size and Eccentric Rotational Axis: Effect of Axial Myopia

Robert A. Clark, MD; Joseph L. Demer, MD, PhD

Stein Eye Institute
Los Angeles, California

Introduction: To evaluate possible effects on strabismus surgical dosing in myopia, we used magnetic resonance imaging (MRI) to examine the relationship between axial length (AL) and ocular rotational axis during adduction and abduction.

Methods: Thirty-six orthophoric adults underwent high-resolution, axial orbital MRI while fixating targets in abduction and adduction. ALs were measured from images containing the largest globe cross-sections. Globe centers were calculated from area centroids of the largest globe cross-sections omitting corneas. Displacements of lens centers and globe-optic nerve junctions in eccentric gaze were used to calculate axes of rotation in orbital coordinates. The lever arms for extraocular musles were calculated as the distances between muscle insertions and axes of rotation.

Results: Average globe rotational axis was 1.1±0.2mm (standard error) medial and 1.1±0.3mm anterior to geometric globe center in initial gaze. Rotational axes did not differ significantly among AL groups <24.0mm, 24.0 to <26.0mm, 26.0 to <28.0mm, and >/=28.0mm. For every 2mm increase in AL, lever arms for the medial rectus (MR, 11.0±0.3mm to 13.2±0.4mm) and lateral rectus (LR, 11.7±0.3mm to 14.0±0.4mm) increased by ~5%, with corresponding ~5% reduction in predicted per mm effect of surgical repositioning of the tendon insertion.

Discussion: Regardless of AL, the globe rotates about a point nasal and anterior to its geometric center, giving the LR a greater lever arm than the MR. This eccentricity may change the effect of muscle repositioning in patients with moderate to high myopia.

Conclusion: Eccentricity of ocular rotational axis may influence the response to strabismus surgery in myopia.

References:

Poster #34
Thursday, 9:55 am – 10:55 am

Quality Analysis of YouTube Videos for Pediatric Strabismus Surgery

Benjamin K. Young; Erol Verter; Martha A. Howard

Yale University School of Medicine, Department of Ophthalmology and Visual Science
New Haven, CT USA

Introduction: The objective of this study was to analyze the quality of publicly available YouTube videos that were most likely to be found by parents or patients searching for information about pediatric strabismus surgery.

Methods: YouTube.com was searched for terms containing 'Strabismus Surgery' 'Lazy Eye Surgery,' and 'Eye turn surgery,' excluding videos that pertained to adults, or with fewer than 100 total views, to best approximate videos viewed by parents. Videos were analyzed based on their audio/video quality, accuracy, comprehensiveness, and ability to answer key questions about pediatric strabismus.

Results: 48 videos were analyzed. The most common category was testimonial (50%), followed by educational (27%), and advertisement (23%). While testimonials represented the plurality of videos, they were significantly poorer than both educational videos and advertisements in audio/video quality, accuracy, comprehensiveness and ability to answer key content questions ($p < 0.05$). Notably, no studied testimonial demonstrated negative outcomes. However, a significant percentage of educational and advertisement videos (34%) provided active disinformation against strabismus surgery, predominantly claiming surgery is never indicated, and that behavioral therapy (ie. muscle training exercises) is always sufficient.

Discussion: Searching for information concerning strabismus on YouTube will typically yield lower quality results in the form of testimonial videos. While educational/advertisement videos tended to be of better quality, some provide active disinformation, advocating against any surgical management of strabismus.

Conclusion: The modern strabismus surgeon should be aware that parents may be viewing publicly available videos with variable quality, or in some cases, disinformation, before or after any surgical consultation.

References:

Poster #35
Thursday, 9:55 am – 10:55 am

Determination of the Strabismus Surgery Dosage Accuracy using a New Technology

Satenik G. Agagulyan, MD; Elena A. Kudryashova, MD; Victoria O. Balasanyan, PhD; Igor E. Aznauryan, Dr Sc, PhD

Association of Pediatric Ophthalmology Clinics ‘Yasniy Vzor’
Moscow, Russian Federation

Introduction: Accurate dosage of strabismus surgery is one of the most important issues in strabismology. The aim of this study was to show the accuracy of mathematical computer program 'Strabo' with the use of Gazelab technology. Gazelab technology shows the motility of eyes and the angle of deviation with one eye closed and both eyes open.

Methods: All patients passed standard pre- and postoperative ophthalmologic examinations. Additionally all patients undergone Gazelab Free or 5-point test before and on the 7th day after surgery.

Results: 11 patients were operated, mean age 5,8 ± 1,5 years. The average value of the deviation with one eye covered was 34,7 ± 12,2 degrees, when two eyes open 27,7±13,9 degrees. Evaluation of the effectiveness of surgery dosage was measured by postoperative angle of strabismus measured by Gazelab technology. The average value of the deviation after surgery with one eye covered was 12,45 ± 7,1 degrees, when two eyes open 10,3 ± 6,1 degrees. Mathematical surgery simulation differed from the actual surgical results by only ± 4,7 degrees.

Discussion: Results obtained after the strabismus surgery correlated with the expected results that was received by 'Strabo' program.

Conclusion: A mathematical model of the surgery allows to distribute the surgical effect on both eyes with a high cosmetic and functional result.

References: 1. Kushner BJ, Fisher MR, Lucchese NJ, Morton GV. Factors influencing response to strabismus surgery. Arch Ophthalmol. 1993: 111(1); 75-9.

Poster #36
Thursday, 9:55 am – 10:55 am

Strabismus Surgical Time-Out: An Illustrated Whiteboard Modification

Natasha N. Loudin, MD; David K. Coats, MD; Joyce Enochs, RN; Madhuri Chilakapati, MD

Baylor College of Medicine/Texas Children's Hospital
Houston, Texas

Introduction: Errors in strabismus surgery can occur due to confusion about surgical plans. Timeout procedures are not standardized and terminology is not well-understood by all team members. We hypothesize that implementation of a strabismus surgery whiteboard during timeout will lead to improved understanding of surgical plans among all team members.

Methods: A strabismus surgery whiteboard was designed with labeled diagrams of both eyes with extraocular muscles. Patient identifiers, diagnosis, motility, deviation, and procedure name were included. This whiteboard was filled out preoperatively and referenced during time-out. The surgeons and operating room staff were trained in its use and filled out pre- and post- implementation surveys.

Results: The pre- and post-implementation surveys were completed by 19 and 14 staff members respectively. The whiteboard timeout increased staff member understanding of which eyes (74% to 86%), which muscles (37% to 79%) and which procedures (37% to 64%) were performed. Staff members felt more confident recognizing surgical errors (from 21% to 43%). Surgeon surveys showed increased confidence in staff member understanding of each parameter with whiteboard use.

Discussion: The survey results demonstrate that staff members better understand surgical plans when the whiteboard is used preoperatively. Enabling staff to become more active participants in the operating room may lead to increased detection and correction of surgical errors thereby improving patient safety.

Conclusion: A standardized timeout using a strabismus surgery whiteboard improves communication between team members and may decrease rates of surgical errors.

References: 1. Shen E., Porco T., and Rutar T. Errors in Strabismus Surgery. JAMA Ophthalmology 2013.
2. Maloley L, Morgan LA, High R, Suh DW. Wrong-Site Surgery in Pediatric Ophthalmology. J Pediatric Ophthalmol Strabismus. 2018 May 1;55(3):152-158
3. Dixon J, Mukhopadhyay D. Hunt J. et al. Enhancing surgical safety using digital multimedia technology. The American Journal of Surgery (2016) 211, 1095-1098

Poster #37
Thursday, 9:55 am – 10:55 am

Abscess Formation After Strabismus Surgery - A Case Series and Review of the Literature

Fran L. Wu, MD, MPH; Jane C. Edmond, MD; Radha Ram, MD; Honey Herce, MD; Kimberly G. Yen, MD; David K. Coats, MD; Madhuri Chilakapati, MD

Baylor College of Medicine / Texas Children's Hospital
Houston, Texas, USA

Introduction: Periorbital infection after strabismus surgery is rare, occurring at a rate of 1 in 1100 surgeries.[1] Abscess formation is extremely rare, with only eight reported cases. Here we describe a series of five cases of abscess formation after strabismus surgery and a review of the literature.

Methods: Cases of abscess formation were collected from four pediatric ophthalmologists at two institutions. A literature search was conducted using the words 'strabismus' and 'abscess' and filtered for cases of abscess formation following strabismus surgery in the post-operative period.

Results: Five cases of abscess formation are described in detail. All patients presented within three days; initial symptoms included pain, conjunctival injection and chemosis, periorbital erythema and edema, change in alignment, fever, nausea, vomiting, and shortness of breath. Three were admitted for IV antibiotics and two were given oral antibiotics; all underwent surgical debridement within seven days of the initial surgery. Four returned to baseline vision with orthotropic alignment within 30 days; the last is still in the post-operative period at the writing of this abstract.

Discussion: No specific surgical technique is indicated as a predisposing factor toward abscess formation. Patients typically present within three days following surgery. Imaging was helpful in characterizing orbital abscesses, but not always necessary for diagnosis. Most patients were admitted to the hospital and received IV antibiotics. Surgical drainage was performed in all cases, typically within a week of the initial strabismus surgery, with marked improvement following drainage. MSSA and Group A Streptococcus pyogenes dominate as causative organisms.

Conclusion: In abscess formation following strabismus surgery, prompt identification and urgent surgical treatment are associated with good outcomes.

References: 1. Kivlin JD, Wilson ME Jr. Periocular infection after strabismus surgery. The Periocular Infection Study Group. J Pediatr Ophthalmol Strabismus. 1995 Jan-Feb;32(1):42-9.

Poster #38
Thursday, 9:55 am – 10:55 am

Loss to Follow-Up after Strabismus Surgery: A Survey of Caregiver Impressions and Impediments to Appointment Attendance

Robert L. Dembinski; Courtney L. Kraus, MD

Johns Hopkins Wilmer Eye Institute
Baltimore, Maryland

Introduction: To determine barriers to compliance with post-operative follow-up after horizontal strabismus surgery in a pediatric population of lower socioeconomic status (SES) and gauge the influence of caregiver perceptions of outcome on appointment attendance.

Methods: Patients from 1/2014-3/2018 who failed to return for examination following strabismus surgery were identified. Medical assistance was used as a proxy for lower SES. A telephone survey was administered to patients' caregivers. Outcome impressions, appointment convenience, reschedule attempts, and decisions to seek care elsewhere were recorded. Obstacles preventing attendance (work, school, childcare, transportation, travel time, insurance, financial struggles, family emergencies, forgetfulness) were also recorded.

Results: 51 patients were identified as lost to follow-up (LTFU). 10 out of 17 caregivers were reachable by phone and consented. 7 caregivers reported good outcomes, 2 were unsure, and 1 reported a negative outcome. 6 caregivers (60%) stated that general forgetfulness affected ability to attend appointments. Other factors were transportation (4), work (4), school (2), family emergencies (2), and financial struggles (1). All caregivers reported one obstacle preventing appointment attendance; 6 reported multiple.

Discussion: We reported that one-third of our population of patients of lower SES was LTFU. Caregiver opinions on outcomes revealed the majority were satisfied. Of those LTFU, 60% forgot; transportation and work obligations were factors for 40%.

Conclusion: Perceived good outcomes may contribute to LTFU, suggesting pre-operative counseling conveying the importance of long term care is important. We observed a trend of forgetfulness playing a role in LTFU in this at-risk population. However, low recruitment limits our ability to draw strong conclusions.

References: 1. Dembinski R, Collins M, Kraus C. Outcomes following horizontal strabismus surgery in children of lower socioeconomic status. AAPOS 2018.

Poster #39
Thursday, 9:55 am – 10:55 am

Effects of Strabismus Surgery on Visually guided Saccades

Fatema F. Ghasia, MD; Graham Lane

Cole Eye Institute, Cleveland Clinic Foundation
Cleveland

Introduction: Strabismic patients have impaired disconjugate binocular horizontal saccades. Other factors such as present or absence of stereopsis, amblyopia, latent nystagmus (LN), and size of strabismic angle may affect disconjugacy of horizontal saccades in strabismic patients. We examined disconjugacy of horizontal saccades in strabismic patients with and without LN, amblyopia and grade of stereopsis before and after surgery.

Methods: Eye movements were recorded with infrared video-oculography in 20 strabismic patients (stereopsis present preop=5; stereopsis absent preop=15; stereopsis present postop=8; stereopsis absent postop=12) with LN (n=12) without LN (n=8) with amblyopia (n=8) without amblyopia (n=12) and 14 controls during visually guided saccades.

Results: Disconjugacy is greater in strabismics with LN (controls = 0.38°, preop no LN = 0.91°, preop LN = 1.325°), amblyopia (amblyopia present = 1.3°, amblyopia absent = 1.1°), those with large angle strabismus (large angle = 1.8°, medium angle preop = 0.82°) and those without stereopsis (stereo absent = 1.3°, stereo present = 0.96°). The disconjugacy decreased significantly after surgery in strabismics with large angle of strabismus. (preop = 1.891, postop = 1.091°). Strabismic patients made greater number of corrective saccades compared to controls and this tendency persisted post surgery.

Discussion: Surgery improves disconjugacy, however, visually guided saccades are still more disconjugate than controls.

Conclusion: Strabismus repair reduces the disconjugacy thereby facilitating fusion in strabismus patients. However, the improvement of the binocular coordination of the saccades is partial post strabismus surgery and may suggest that the central mechanisms could drive the recurrence of strabismus.

References: 1) Kapoula Z, Bucci MP, Eggert T, Garraud L. Impairment of the binocular coordination of saccades in strabismus. Vision research 1997;37(19):2757-66
2) Ghasia FF, Otero-Millan Jorge, Shaikh AG. Abnormal fixational eye movements in strabismus. BJO 2017
3) Cohen, Mark E., and Leonard E. Ross. 'Latency and Accuracy Characteristics of Saccades and Corrective Saccades in Children and Adults.' Journal of Experimental Child Psychology26, no. 3 (1978): 517-27. doi:10.1016/0022-0965(78)90130-3.

Poster #40
Thursday, 9:55 am – 10:55 am

The Changing Face of Adult Strabismus Surgery

Frederick R. Burgess, MBChB; Alan O. Mulvihill, FRCSEd

Princess Alexandra Eye Pavilion
Edinburgh, U.K.

Introduction: Adult strabismus surgery rates increased by 24% in the UK from 2000-2014 (1). This study aims to highlight changes in the subtypes of strabismus being operated on over the past decade.

Methods: Retrospective case study. All adults receiving strabismus surgery from 2008-2017 were included. All patients were operated on by one attending surgeon. Case notes were examined for demographic, diagnostic and operative data.

Results: 492 operations were performed on 466 patients, with an average year-on-year increase in total number of adult strabismus operations of 16% over 10 years. Consecutive or residual strabismus remained the most common subtype throughout the study period and showed increasing rates as a percentage of all operations. Operative rates proportionately decreased for all other subtypes, except for those with esotropia or exotropia associated with myopia.

Discussion: Although the mainstay of adult strabismus surgery remains consecutive or residual strabismus, a new subtype emerged over the study period. That myopia is associated with late-onset esotropia (with lateral rectus weakness) is well known (2). We identified a subgroup of myopic patients presenting in early adulthood with a decompensating esophoria and diplopia. These patients responded well to surgery and now comprise a significant proportion of our operative workload. The authors hypothesise that use of smartphones and associated sustained convergence (3) are partially responsible for this subgroup.

Conclusion: More research is needed into the effect of sustained convergence on those with myopia and esophoria. The nature of strabismus surgery is changing, which has implications for training and workforce planning.

References: 1. Astle AT, Foulsham T, Foss AJ, McGraw PV. Is the frequency of adult strabismus surgery increasing? Ophthalmic Physiol Opt 2016; 36(4):487-93.
2. Ranka MP, Steele MA. Esotropia associated with high myopia. Curr Opin Ophthalmol 2015; 26(5):362-5.
3. Graefe A von. Über die von Myopie abhängige Form convergirenden Schielens und deren Heilung. Graefes Arch. Ophthalmol 1864; 10:156–175.

Poster #41
Thursday, 9:55 am – 10:55 am

Adult Strabismus Surgery Outcomes with Adjustable and Nonadjustable Sutures

Siddharth Bhargava; David Shieh; Dan Liu, MD; Jitka Zobal-Ratner, MD; John W. Simon, MD

Albany Medical Center
Albany, NY

Introduction: Previous series suggest adjustable sutures (AS) in adult strabismus surgery yield improved ocular alignment, better success rates, and fewer reoperations compared to nonadjustable sutures (NAS). We questioned whether this difference is clinically significant and whether it justifies the added time and discomfort required for AS.

Methods: We reviewed all available records of adults undergoing horizontal strabismus surgery by the last two authors between 2000 and 2014. Independently, the two surgeons developed a preference for NAS midway through the study period, permitting a comparison between the two treatment groups. The primary outcome was alignment in primary position two days after surgery and at last follow-up. The secondary outcome was success rate, defined as <10PD residual or consecutive deviation at last follow-up. Reoperations were deemed failures.

Results: We included 175 patients, 57 with AS and 118 with NAS. No significant difference in primary alignment was noted between AS and NAS for esotropia (P=0.60 early, P=0.17 final) or for exotropia (P= 0.40, early, P=0.11, final). Success rates were similar (P= 0.19), and there was no significant difference in reoperation rates (P= 0.19).

Discussion: Although we acknowledge limitations in this retrospective study, our results suggest that AS overall were not associated with improved alignment or surgical success in adults with esotropia or exotropia compared to NAS.

Conclusion: We believe adjustable sutures may be beneficial in cases involving uncertain restrictive or contractile forces, but we no longer use AS in routine cases.

References: 1. Zhang MS, Hutchinson AK, Drack AV, et al. Improved Ocular Alignment with Adjustable Sutures in Adults Undergoing Strabismus Surgery. Ophthalmology. 2012;119:396-402.
2. Leffler CT, Vaziri K, Covuoto KM, et al. Strabismus surgery reoperation rates with adjustable and conventional sutures. Am J Ophthal. 2015;160(2):385-390.
3. Mireskandari K, Colesta M, Schofield J, et al. Utility of adjustable sutures in primary strabismus surgery and reoperations. Ophthalmology. 2012;119:629-633.

Poster #42
Thursday, 9:55 am – 10:55 am

Natural Course and Surgical Outcomes of Ophthalmoplegia after Iatrogenic Ophthalmic Artery Occlusion caused by Cosmetic Filler Injections

Yunjin Lee; Hee Kyung Yang; Se Joon Woo; Kyu Hyung Park; Jeong-Min Hwang

Department of Ophthalmology, Seoul National University Bundang Hospital
300, Gumi-dong, Bundang-gu, Seongnam, Gyeonggi-do 463-707, Republic of Korea.

Introduction: Ophthalmic artery occlusion could be caused by facial filler injections. Although visual loss has been well described, the natural course of ophthalmoplegia and sensory strabismus are lacking in previous reports. Herein, we investigated the incidence and natural course of ophthalmoplegia and strabismus related to facial filler injection along with the surgical outcomes of strabismus.

Methods: Retrospective data were obtained regarding the incidence, clinical characteristics and final sequelae of ophthalmoplegia after cosmetic filler injection. In patients who received strabismus surgery, the type of surgery and final outcomes were noted.

Results: Among 21 patients, ophthalmoplegia occurred in 71%. After a mean follow-up of 2.5 years, complete recovery of ophthalmoplegia was found in 77% and sensory exotropia developed in 46%. Anterior segment ischemia was the only significant factor related to ophthalmoplegia. Six patients received strabismus surgery after a mean follow-up of 2.2 years, while 2 patients with incomplete recovery of ophthalmoplegia showed poor outcomes.

Discussion: This study is the largest series regarding the natural course and surgical outcomes of ophthalmoplegia related to cosmetic facial filler injection. Ophthalmoplegia was associated with anterior segment ischemia, which suggests that occlusion of vessels supplying the rectus muscles along with the anterior ciliary arteries is mainly responsible for ophthalmoplegia occurring after facial filler injections.

Conclusion: Ophthalmoplegia frequently occurred after iatrogenic vascular injury from facial filler injection. After a mean follow-up of 2 years, more than half of patients developed sensory exotropia. Surgical outcomes of strabismus are relatively good unless there is permanent ocular motility limitation.

References: 1. Park SW, Woo SJ, Park KH, Huh JW, Jung C, Kwon OK. Iatrogenic retinal artery occlusion caused by cosmetic facial filler injections. Am J Ophthalmol 2012;154:653-662 e1.
2. Kim A, Kim SH, Kim HJ, Yang HK, Hwang JM, Kim JS. Ophthalmoplegia as a complication of cosmetic facial filler injection. Acta Ophthalmol 2016;94:e377-9.
3. Park KH, Kim YK, Woo SJ, et al. Iatrogenic occlusion of the ophthalmic artery after cosmetic facial filler injections: a national survey by the Korean Retina Society. JAMA Ophthalmol 2014;132:714-23.

Poster #43
Thursday, 9:55 am – 10:55 am

Face and Content Validation of a Low Cost Strabismus Surgery Simulation Model

Saurabh Jain, Mr; Mohsan M. Malik, Dr; Niel Shah, Dr; Vivienne Kit, Dr

Royal Free London
London, United Kingdom

Introduction: Strabismus surgery training has historically focussed on the Halsteadean approach. However, simulation training offers an alternative to practice skills without jeopardising surgical outcomes. Current simulation models for strabismus surgery are limited due to ethical and financial issues. Our aim was to validate a low cost model for training core skills required in strabismus surgery.

Methods: A low cost strabismus model was developed using commercially available materials. Ophthalmic residents, fellows and consultants were surveyed using a questionnaire to assess the realism and training utility of the model using a 5-point likert scale (1 = unacceptable, 2 = poor, 3 = acceptable, 4 = favourable and 5 = excellent).

Results: 26 ophthalmologists completed the questionnaire. The model scored highly for muscle securing (mean 4.24) and suturing (mean 4.17). Muscle dissection and conjunctiva was considered poor (mean 2.50, 2.92 respectively). Overall, participants felt the model simulated muscle resection and recession well (mean 3.88) and was comparable to other dry simulation models (mean 4.00).

Discussion: Our model supports realistic autonomous practice of key strabismus surgical techniques, giving potential to improve surgical outcomes. Trainees can practice in a distributed manner, which has shown to improve and sustain skills compared to a single high validity simulation.
However, it remains a technical challenge to replicate certain parts of the eye using commercial materials and requires time to assemble.

Conclusion: Our model met face and content validity for muscle securing and suturing. Further construct validation is required to evaluate the model as an assessment tool.

References:

Poster #44
Thursday, 9:55 am – 10:55 am

Magnitude and Stability of Alignment in Children Following Bupivacaine and /or Botulinum Toxin A Injection into Extraocular Muscles

Rasha H. Zedan, MD; Ranya A. Badr, MSc; Lobna M. Khasbak, MD; Mohammed S. Zatar, MD

Aboul Reesh Children Hospital, Cairo University
Cairo

Introduction: To asses the magnitude and stability of alignment following fixed dose bupivacaine and /or botulinum A toxin injection into extraocular muscles in children.

Methods: 74 children aged 2 to 14 years with concomitant horizontal strabismus were included in this study. Group A (20 cases) angle < 16PD received bupivacaine 0.75% injection into the agonist muscles. Group B (23 patients) angle 16-30PD received botulinum toxin 5 units injection into the antagonist muscles. Group C (31patients) angle > 30 PD received bupivacaine 0.75% and botulinum toxin 5 units injections into the agonist and antagonist muscles respectively.

Results: In group A; 11 patients were orthotropic, 6 had residual esotropia and 3 had residual exotropia. The mean preinjection angle was 13.55+/-2.56PD and postinjection angle was 8.45+/- 2.56PD. In group B; 8 patients were orthotropic, 2 had residual esotropia and 13 had residual exotropia. The mean preinjection angle was 28.0+/-3.28PD and mean postinjection angle was 15.25+/- 10.79PD. In group C; 10 patients were orthotropic, 14 had residual esotropia and 7 had residual exotropia. The mean preinjection angle was 45.57+/-7.03PD and mean postinjection angle was 20.67+/-16.41PD.

Discussion: Combined fixed doses of bupivacaine 0.75% and botulinum toxin A 5 units injections can achieve stable corrections of approximately 25 PD. Sole injections of each can be used for small angles of 10-15 PD with satisfactory results.

Conclusion: Injection treatment resulted in clinically significant corrections in concomitant horizontal strabismus in children and maybe used as an alternative to surgery.

References: Iara Debert, Joel M. Miller, Kenneth K. Danh and Alan B. Pharmacologic injection treatment of comitant strabismus. JAAPOS 2016; 20:106-111.
Scott AB, Miller JM, Shieh KR. Bupivacaine injection of the lateral rectus muscle to treat esotropia. JAAPOS 2009; 13:119-122.
Scott AB, Alexander DE, Miller JM. Bupivacaine injection of eye muscles to treat strabismus. Br J Ophthalmol 2007; 91:146-8.

Poster #45
Thursday, 9:55 am – 10:55 am

Single Lateral Rectus Resection in Adult Non-Accommodative Esotropia

Vanessa K. Avellaneda-Chevrier, OC(C); Helen A. Kim; Mrunalini D. Parvataneni, MD

Northwest Eye
8401 Golden Valley Road, Suite 330, Golden Valley, Minnesota, 55427

Introduction: One muscle strabismus surgery is typically avoided due to concerns about undercorrection or ocular incomitance. We report the results from a series of patients who underwent single lateral rectus resection to treat a symptomatic moderate angle non-accommodative esodeviation.

Methods: A retrospective chart review was performed for 19 patients (aged 21-85) who were surgically treated with either a 6.0mm or 6.5mm unilateral rectus resection. Patients with esotropia between 15-25 prism diopters (PD) were included. Preoperative and postoperative sensorimotor exams were compared.

Results: Preoperatively, all patients had symptomatic esodeviation (mean 17 ± 2.83 PD). Postoperative visits at less than 2 weeks resulted in an average angle of deviation at distance of 2.21 ± 2.93 PD ($P < 0.0001$) for all patients. Postoperative visits with 13 of the 19 patients at greater than 6 months resulted in an angle at distance of 4.31 ± 4.09 PD ($P < 0.0001$). Two patients were treated with prism glasses and one other with surgery for residual diplopia. No patients had symptoms from lateral incomitancy.

Discussion: Primary single muscle resection has not been typically performed except in divergence insufficiency. It is usually reserved for undercorrected or recurrent strabismus.[1-3] Patients showed improvement in binocular function and had additional benefits of shorter anesthesia time, faster recovery, and less cost.

Conclusion: Unilateral lateral rectus resection as a primary procedure can be an effective surgical option in the management of adult patients with moderate angle esodeviation.

References: 1. Nucci P, Serafino M, Trivedi RH, Saunders RA. One-muscle surgery in small-angle residual esotropia. J AAPOS 2006;11:269-272.
2. Thacker NM, Velez FG, Bhola R, Britt MT, Rosenbaum, AL. Lateral rectus resections in divergence palsy: results of long-term follow-up. J AAPOS 2005;9:7-11.
3. Wang L, Nelson LB. One muscle strabismus surgery. Current Opinion in Ophthalmology 2010;21:335-340.

Poster #46
Thursday, 9:55 am – 10:55 am

Combined Unilateral Recession/ Resection Surgery in the Management of Esotropia with Near-Distance Disparity

Panagiota Antonopoulou, MD, MSc, FRCOphth, FEBO; Mohammad W. Ghaffari; Adam Budd, DO;
Anna P. Maino, FRCOphth, FEBO

Manchester Royal Eye Hospital
Manchester, United Kingdom

Introduction: To study the effect of unilateral combined recession/ resection surgery in patients with near-distance disparity.

Methods: All children with esotropia and near-distance disparity of at least 14 PD were recruited prospectively. Patients suitable for adjustable surgery or with previous strabismus surgery were excluded from the study. A satisfactory outcome was defined as esotropia of <10 PD at near and distance, with full cycloplegic referactive correction, and reduction of near-distance disparity to <10 PD.

Results: 22 patients were enrolled;17 with constant esotropia with accommodative element and 5 with convergence excess, of which 3 had normal AC/A ratio and 1 low. Median age was 7 years (range 3-16). Mean preoperative angle was 35.4 ± 11 PD for near and 18.2 ± 10 PD for distance. Mean near-distance disparity preoperatively was 17.1 ± 4 PD. Two weeks after surgery, near-distance disparity had reduced to 5.8 ± 5 PD. At the final postoperative check (range 6 – 24 months), mean angle for near was 10 ± 5 PD and 5.5 ± 3 PD for distance. Near-distance disparity was 4.5 ± 4 PD. 12 patients (55%) had <10 PD esotropia at near and the remaining 10 measured between 12 and 20 PD.

Discussion: All patients had a satisfactory result for distance and twenty (90%) measured <10 PD near-distance disparity. Stereopsis was demonstrated in 7 patients. No patients developed distance exotropia or convergence insufficiency.

Conclusion: Unilateral combined recession/resection surgery is a promising technique that addresses the challenge of near-distance disparity without the risk of overcorrection.

References: Somer D, Gul Cinar F, Oral B, Ornek F. Combined recession and resection surgery in the management of convergence excess esotropia with different level of AC/A ratio. J AAPOS 2017;21:7.e1-7.e7
Ramasamy B, Rowe F, Whitfield K, Nayak H, Noonan CP. Bilateral combined resection and recession of the medial rectus muscle for convergence excess esotropia. J AAPOS 2007;11:307-309.

Poster #47
Thursday, 9:55 am – 10:55 am

Botulinum Toxin-Augmented Surgery for Large-Angle Esotropia

Lívia A. Kühl, MD; Iara Debert, MD, PhD; Caroline N. Seto, MD; Maria R. Okamura, MD; Mariza Polati MD, PhD

University of Sao Paulo
Sao Paulo, Brazil

Introduction: Surgical correction of large-angle esotropia is challenging when the plan is monocular operation. Supramaximal recession-resection procedure is usually required, but frequently leads to unwanted limitation of ocular motility. The purpose of this study is to evaluate the efficacy of botulinum toxin-augmented monocular surgery for correcting esodeviations >/= 60 PD and its association with limitation of adduction postoperatively.

Methods: Retrospective medical record review of 11 consecutive patients with esotropia >/= 60 PD who underwent monocular recession-resection surgery augmented by intraoperative botulinum toxin injection in the medial rectus. Patients with at least 6 months' follow-up were included.

Results: Age at surgery was 23 ± 16 years. Preoperative deviation was 75 ± 7 PD (range 60 to 85) and postoperative deviation was 10 ± 9 PD (range 0 to 30). On average, 86% of the preoperative deviation was corrected. Nine patients (82%) had postoperative deviation = 15 PD. Thirty days following surgery, average adduction deficit was -2 ± 1 (range -4 to 0). At the most recent follow-up visit, 10 patients (91%) had postoperative adduction deficit ranging from 0 to -1 and one patient (9%) had -2 adduction deficit.

Discussion: The use of botulinum toxin combined with monocular surgery is a good alternative to supramaximal recession-resection procedure. Although the pharmacologic effect of botulinum toxin is temporary, changes in sarcomere density during the early postoperative phase lead to permanent results. This procedure corrected large-angle esodeviations and caused minimal permanent limitation of adduction.

Conclusion: Botulinum toxin-augmented recession-resection surgery is effective for treating large-angle esotropia.

References: (1) Özkan, S. B., Topaloglu, A., Aydin, S. The role of botulinum toxin A in augmentation of the effect of recession and/or resection surgery. J AAPOS. 2006; 10: 124-127

(2) Scott, A. B. Change of eye muscle sarcomeres according to eye position. J Pediatri Ophthalmol Strabismus. 1994; 31(2): 85-88.

(3) Wan, M. J. The effect of botulinum toxin augmentation on strabismus surgery for large-angle infantile esotropia. Am J Ophthalmol. 2018; 189: 160-165

Poster #48
Thursday, 9:55 am – 10:55 am

Surgical Outcomes for Esotropia in Children with High AC/A Ratio

Reecha S. Bahl, MD; Monique J. Cheng, BS; Sabrina Dass, BS

Kresge Eye Institute
Detroit, MI

Introduction: To assess if high accommodative convergence/accommodation ratio (AC/A) impacts surgical outcomes in children with esotropia (ET).

Methods: A retrospective chart review identified patients who underwent primary bilateral medial rectus recessions (BMRc) for ET. High AC/A was defined as an increase of ≥10PD deviation at near compared to distance. Outcome parameters were: (1) near and distance deviations ≤10PD within orthophoria, and/or (2) presence of stereopsis (positive fly) postoperatively. Analysis used Yates' continuity correction, Fischer's exact test, and unpaired t-test.

Results: Of 116 charts identified, thirty had a high AC/A preoperatively compared to 86 with normal AC/A. Mean age was 3.90 years (SD 2.71 years). Surgical success measured by postoperative alignment were 43% and 40% in the high AC/A and normal AC/A groups, respectively (p=0.88). There was a statistically significant difference in postoperative stereopsis success, with 16% of patients with normal AC/A versus 44% of patients with high AC/A having positive fly on postoperative stereopsis testing (p=0.03).

Discussion: In the setting of ET treated with BMRc, the presence of high AC/A does not affect surgical success as measured by postoperative alignment. However, patients with high AC/A preoperatively had a significantly improved surgical success as measured by postoperative stereopsis, compared to those with a normal AC/A. This difference is likely related to a partially accommodative etiology of misalignment when a high AC/A is present, compared to non-accommodative esotropia with normal AC/A, with the latter having a lower probability of postoperative fusion.

Conclusion: Our findings can guide clinicians in their decisions regarding surgical treatment of patients with ET.

References: 1. Arnoldi KA, Tychsen L. Surgery for esotropia with a high accommodative convergence/accommodation ratio: effects on accommodative vergence and binocularity. Ophthalmic Surg Lasers 1996;27(5):342-8.

2. Whitman MC, MacNeill K, Hunter DG. Bifocals Fail to Improve Stereopsis Outcomes in High AC/A Accommodative Esotropia. Ophthalmology 2016;123(4):690-696.

3. Ludwig IH, Imberman SP, Thompson HW, Parks MM. Long-term study of accommodative esotropia. Transactions of the American Ophthalmological Society 2003;101:155-161.

Poster #49
Thursday, 9:55 am – 10:55 am

Horizontal Rectus Muscle Resections in the Elderly: Indications and Outcomes

Cody R. Richardson, MD; Miriam DiMenna, CO; Abigail Lepsch, MD; Mary E. Hoehn, MD; Natalie C. Kerr, MD

Hamilton Eye Intitute
Memphis, TN

Introduction: Lateral rectus resections have been advocated as treatment for divergence insufficiency esotropia, a common condition in the elderly. Our study evaluates the indications and outcomes of resection procedures for all types of horizontal strabismus in an elderly (>64 years) patient population.

Methods: Retrospective chart review of elderly patients undergoing a resection procedure for horizontal strabismus by two surgeons in an academic practice. Successful surgery was defined as post-operative distance deviation within 10 prism diopters of orthotropia.

Results: Fifty-one patients met inclusion criteria with mean age 72.2 years (range 65-87). The most common indication for resection procedure was divergence insufficiency esotropia (23.5%). Resection procedures were successful in 76.5% of cases. Adjustable sutures were used in 31 cases (60.8%), and adjustments were made in 67.7% of those cases. Surgery was successful in 77.4% of adjustable cases versus 75% in nonadjustable cases (p=0.74). Diplopia dropped from 68.6% to 35.3% post-operatively (p=0.01). Need for prism spectacles was reduced from 39.2% to 7.8% post-operatively (p=0.28). Re-operation occurred in 11.8% of patients.

Discussion: Overall, resection procedures were successful in this elderly population. Although outcomes were equivalent between adjustable and nonadjustable surgery, there is a selection bias for using adjustable sutures on cases with less predictable outcomes. Diplopia was significantly reduced in both groups. Reduction of prism spectacles trended toward significance. The re-operation rate was comparable to other adult populations.

Conclusion: Resection procedures successfully treat horizontal strabismus from a variety of causes in the elderly population. Need for re-operation is infrequent after resection procedures in this population.

References: 1. Mireskandari K, et al. Utility of adjustable sutures in primary surgery and reoperations. Ophthalmology. 2012 Mar; 119(3): 629-33.
2. Repka MX, Yu F, Coleman A. Strabismus among aged fee-for-service Medicare beneficiaries. J AAPOS. 2012 Dec; 16(6): 495-500.
3. Thacker NM, et al. Lateral rectus resections in divergence palsy: results of long-term follow-up. J AAPOS. 2005 Feb; 9(1): 7-11.

Poster #50
Thursday, 9:55 am – 10:55 am

Jensen's Procedure Combined with Adjustable Medial Rectus Recession to Treat Complete Sixth Nerve Palsy

Vu Thi Que Anh, MD; Do Quang Ngoc, MD; Tran Manh Hung, MD

Introduction: Patients with complete sixth nerve palsy have severe limitation of abduction, often leading to primary position esotropia that is associated with a compensatory head posture, reduced stereopsis, and diplopia. The purpose of this study is to present and eveluate the results of Jensen's procedure and medial rectus recession with adjustable suture to correct the esotropia in cases of complete sixth nerve palsy.

Methods: Prospective study of 35 patients with complete sixth nerve palsy who underwent Jensen's procedure associated with adjustable medial rectus recession in the affected eye. Binocular alignment, ocular motility, diplopia condition, abnormal head postion and complications are analyzed.

Results: In all cases, we found a varying degree of improvement at 1 month, 3 months, and 6 months postoperative. There was a significant reduction in the strabismus angle, increase in abduction of the affected eye. The results also shown the improvement of diplopia condition and abnormal head position. No specific complications occurred during or after surgery.

Discussion: Many patients with abduction limitation will develop tightness or contracture of the medial rectus muscle over time. This can limit the effectiveness of transposition procedure. Therefore, we routinely recessed the medial rectus muscle to reduce any potential abduction limitation. By making adjustable, we were able to fine-tune the horizontal alignment postoperative, an added benefit considering that a transposition procedure might have a less predictable result on horizontal alignment.

Conclusion: Jensen's procedure associated with adjustable medial rectus recession is safe and effective method for the management of patients with complete sixth nerve palsy.

References: 1. Foster RS. Vertical muscle transposition augmented with lateral fixation. JAAPOS. 1997; 1(1):20-30
2. Nishida Y, Inatomi A, Aoki Y, et al. A muscle transposition procedure for abducens palsy, in which the halves of the vertical rectus muscle bellies are sutured onto the sclera. Japan Journal of Ophthalmology. 2003;47(3):281-6.
3. Brit MT, Velez FG, Thacker N, et al. Partial rectus muscle-augmented transpositions in abduction deficiency. JAAPOS. 2003;7(5):325-32.

Poster #51
Thursday, 9:55 am – 10:55 am

The Relationship of Age and Other Baseline Factors to Outcome of Initial Surgery for Intermittent Exotropia

Michael X. Repka, MD, MBA; Danielle L. Chandler, MSPH; Jonathan M. Holmes, MD; Sean P. Donahue, MD, PhD; Paul H. Phillips, MD; Ann U. Stout, MD; Darren L. Hoover, MD; David K. Wallace, MD, MPH

Pediatric Eye Disease Investigator Group
Jaeb Center for Health Research, Tampa, Florida

Introduction: To determine whether age at surgery and other baseline factors were associated with suboptimal surgical outcome for intermittent exotropia (IXT).

Methods: Children 3 to <11 years of age with basic type IXT and at least 400 arcsec near stereoacuity were randomly assigned to bilateral lateral rectus muscle recessions (BLR) or unilateral lateral rectus recession with medial rectus resection (R&R). Masked examinations were performed every 6 months for 3 years postoperatively. Suboptimal surgical outcome was defined as exotropia of >/=10PD at distance or near by SPCT, constant esotropia of >/=6PD at distance or near by SPCT, or decrease in near stereoacuity of >2 octaves from enrollment, at any masked examination; or reoperation.

Results: Overall, the probability of a suboptimal surgical outcome by 3 years postoperatively was 28% (19 of 72) for children 3 to <5 years of age, compared with 50% (57 of 125) for children 5 to <11 years of age (adjusted hazard ratio = 2.00; 95% CI = 1.19 to 3.35). Other than age at surgery, no statistically significant associations were found between suboptimal outcome and any other baseline factor, including size of distance and near angle, distance and near control score, and near stereo level.(all P values > 0.30).

Discussion: Our analysis does not address timing of surgery, which would require randomly assigning young children to early vs. delayed surgery.

Conclusion: Over 3 years of follow-up, children with IXT undergoing surgery at 3 to <5 years of age have less frequent suboptimal surgical outcomes than children undergoing surgery at 5 to <11 years, a finding that deserves further study.

References: PEDIG. A Randomized Trial Comparing Bilateral Lateral Rectus Recession versus Unilateral Recess and Resect for Basic-Type Intermittent Exotropia. Ophthalmology 2018 Sep 3. pii: S0161-6420(18)31552-5. doi: 10.1016/epub

Poster #52
Thursday, 9:55 am – 10:55 am

Large Angle Exotropia and the Legend of the Surgical Dose-Response Curve

Lin Li, MD, PhD; Toshiaki Goseki, MD,PhD; Soh Youn Suh, MD; Stacy L. Pineles, MD; Sherwin J. Isenberg, MD; Joseph L. Demer, MD,PhD

Stein Eye Institute,David Geffen School of Medicine UCLA
100 Stein Plaza,Los Angeles, CA, 90095-7002

Introduction: Analyzing esotropia, Archer has challenged the surgical dose-response notion by showing that strabismus surgery effect is better predicted by pre-operative angle than by surgical dose in millimeters.We asked if the effect of three horizontal muscle surgery for large angle exotropia is better predicted by surgical dose, or by pre-operative exotropia angle, with special attention to cases where identical dose was performed for a range of pre-operative angles.

Methods: We reviewed records of 17 patients of average age 35±23 years with exotropia ≥30Δ who underwent three muscle surgery. Surgical effect was compared by linear regression with preoperative exotropia, and with total millimeters of recession plus resection or plication.

Results: Mean postoperative exotropia at distance was improved from 47±11Δ to 4±8Δ and 47±14Δto 4±7Δ at near. Linear regression showed that total surgical dose accounted for only 21% (R^2) of surgical effect, while pre-operative deviation accounted for 56%. For exotropia from 30-50Δ, 83% of patients were aligned to orthotropia at 10 weeks mean last follow-up by the same 18mm total surgical dose achieved by 7mm bilateral lateral rectus recession and 4mm medial rectus resection or plication.

Discussion: Similar to infantile esotropia, surgical effect for large angle exotropia does not depend strongly upon surgical dose, implicating other biological factors in the response. Typical published success rates may be achieved by performing the same surgery for all large angle exotropia angles.

Conclusion: Surgical success for large angle exotropia is attributable more to the biological response than to the amount of surgery performed.

References: Archer, S. M. Why strabismus surgery works: The legend of the dose-response curve. J. AAPOS 2018; 22: 1.e1-1.e6.

Poster #53
Thursday, 9:55 am – 10:55 am

Effect of Inferior Oblique Myectomy on Primary Position Horizontal Alignment in Patients with Exotropia

Christina Scelfo; Maan Alkharashi

Boston Children's Hospital
Boston, MA

Introduction: We aim to evaluate the surgical success and need for adjustment due to overcorrection in patients who undergo inferior oblique myectomy (IOM) combined with lateral rectus recession (LRc) for exotropia in the setting of inferior oblique overaction.

Methods: We conducted a retrospective chart review of patients with exotropia who underwent LRc using adjustable sutures alone versus LRc combined with IOM from January 2010 to present at our institution. Binocular alignment was recorded before and within one week of surgery. We evaluated post-operative alignment, surgical success (defined as distance alignment of </=10PD), and need for post-operative adjustment due to overcorrection.

Results: The chart review identified 48 patients. Twenty-four underwent LRc alone and 24 underwent LRc combined with IOM. Surgical success was significantly higher in the lateral rectus recession alone group (91.6%) compared to the IOM group (62.5%) (P=0.036). The need for post-operative adjustment due to overcorrection was also significantly higher in the IOM group (20.8%) compared to the LRc alone group (0%) (P=0.049).

Discussion: In this study, more patients needed adjustment for overcorrection when undergoing LRc combined with IOM compared with to LRc alone. Since the tertiary action of the inferior oblique is abduction, it is possible that in patients with inferior oblique overaction, weakening the inferior oblique surgically causes more esodeviation and overcorrection.

Conclusion: Surgical correction of exotropia and inferior oblique overaction with LRc combined with IOM may lead to overcorrection and increased need for post-operative adjustment.

References: Isaac CR, Chalita MR. Effect of combining oblique muscle weakening procedures with bimedial rectus recessions on the surgical correction of esotropia. J AAPOS. 2015;19(1):54-6.
Souza-Dias C. Horizontal effect of the surgical weakening of the oblique muscles. Arq Bras Oftalmol. 2011;74(3):180-3.
Stager DR, Parks MM. Inferior oblique weakening procedures. Effect on primary position horizontal alignment. Arch Ophthalmol. 1973;90(1):15-6.

Poster #54
Thursday, 9:55 am – 10:55 am

Results of Sensory Exotropia Surgery with and without Oblique Muscles Weakening

Andre Leite, MD; Bruna Ducca, MD; Simone Nakayama, MD; Deborah Stina, MD; Tomas Mendonca, MD

Federal University of Sao Paulo (UNIFESP)
Brazil

Introduction: In sensory exotropia, horizontal muscles surgery associated with oblique muscles weakening in the amblyopic eye could have a greater effect than horizontal muscles procedure alone (1, 2). The purpose of this study is to compare the results of unilateral surgery with and without oblique muscles weakening.

Methods: Thirty patients with a deviation larger than or equal to 30 prism-diopters (PD) were retrospectively divided into two groups: the weakening group (surgery of horizontal rectus and oblique muscles) and the control group (surgery of horizontal rectus muscles). The minimum follow-up period was six months.

Results: The mean surgical correction in the weakening group (46.61 PD) was statistically higher than in the control group (31.65 PD) (P = 0.017). The surgical success rate was 52.94% in the control group and 61.54% in the weakening group (P = 0.638). There was no relationship between the appearance of a new vertical deviation and the type of surgery performed (P = 0,657).

Discussion: The weakening of oblique muscles allows more correction and seems to avoid long-term recurrence in sensory exotropia. The surgical correction was statistically greater in the weakening group and there were no complications.

Conclusion: A prospective study with a larger number of patients and a longer postoperative follow-up would be important to evaluate the efficacy of this surgical option.

References: 1. Raab EL. Unilateral four-muscle surgery for large-angle exotropia. Ophthalmology 1979;86:1441-50.
2. Jampolsky A: Surgical management of exotropia. Am J Ophthalmol 1958;46:646-648.

Poster #55
Thursday, 9:55 am – 10:55 am

Prevalence and Natural History of Consecutive Exotropia in Botulinum Toxin Chemodenervation for Esotropia

Crystal S. Cheung, MD; Linda R. Dagi, MD; David G. Hunter, MD, PhD; Michael J. Wan, MD; Ankoor S. Shah, MD, PhD

Introduction: The purpose of this study is to report the prevalence and natural history of consecutive exotropia following botulinum toxin chemodenervation for esotropia.

Methods: Medical records of patients treated with botulinum toxin for infantile and acquired esotropia were retrospectively reviewed at two tertiary centers. Exclusion criteria included prior or concomitant strabismus surgery or < 6 months of follow-up. The primary outcome measure was defined as the prevalence of non-resolving consecutive exotropia at 6 months after treatment. Secondary outcomes measures were persistent consecutive exotropia at 18 months and prevalence of corrective procedures.

Results: Record review revealed 140 patients of whom 123 met inclusion criteria. Median onset of esotropia was 2.8 years (IQR2.8-5.7), and median age of treatment was 4.0 years (IQR2.5-7.5). Nine patients (7.3%) had non-resolving consecutive exotropia at 6 months. Of these 9, 7 had persistent consecutive exotropia at 18 months (77.8%), 1 spontaneously improved at 15 months, and 1 did not have 18-month follow-up. Moreover, 3 of the seven patients (42.8%) required additional corrective procedures, all performed after 18-month follow-up.

Discussion: The prevalence of non-resolving, consecutive exotropia following botulinum toxin is 7.3%, similar to a prior study (1). The natural history suggests that at least 77.8% of patients with consecutive exotropia will not spontaneously improve after 6 months.

Conclusion: This study implies that surgical intervention, which has been shown to be successful (2), should be considered earlier than previously reported for patients who develop consecutive exotropia following botulinum toxin for esotropia.

References: (1) Campomandes AG et al. Comparison of botulinum toxin with surgery as primary treatment for infantile esotropia J AAPOS 2010; 14:111-6.

(2) Tejedor J & Rodriguez JM. Management of non-resolving consecutive exotropia following Botulinum toxin treatment of childhood esotropia Arch ophthalmol 2007;125:1210-3.

Poster #56
Thursday, 9:55 am – 10:55 am

Acute Acquired Comitant Esotropia in Children: Is It a Neurological Disease?

Gad Dotan, MD; Yariv Keshet; Ronit Friling

Schneider Children's Medical Center of Israel
Petah Tikva, Israel

Introduction: Acute acquired comitant esotropia (AACE) is a relatively rare type of pediatric strabismus, often described as a possible presentation of intracranial pathology including a brain tumor. Therefore, many clinicians recommend performing a neurological evaluation and neuroimaging in these cases. However, the risk of having neurological disease is not clear since many of the cases previously presented had other neurological or ophthalmological abnormalities besides the esotropia including headache, vomiting, gait disturbances, nystagmus or papilledema. The purpose of this study is to analyze the incidence of neurological abnormalities in children presenting with AACE and otherwise normal neurological and ophthalmological evaluations.

Methods: A retrospective analysis of all children older than 4 years of age with AACE examined between 2014 - 2018 by one of the authors (GD). The main outcome measure was the presence of neurological disease. Children with duction deficits, incomitant esodeviations and hyperopia >2.00 diopters were excluded.

Results: Twenty children (11 males, mean age 9.8 +/- 4.1 years) with AACE were included in this study. Mean esodeviation was 29.5 +/- 14.8 (range, 10 -55) prism diopters. All had an otherwise normal ophthalmological evaluation without evidence of nystagmus, duction deficits or papilledema. None had other neurological symptoms or signs. Ninety-five percent (n=19) had brain neuroimaging, most commonly MRI (n=18), that were all read as normal.

Discussion: Pediatric AACE is usually not a manifestation of intracranial pathology, especially when other ophthalmic and neurological abnormalities are not present.

Conclusion: Decision to perform neuroimaging in children with AACE should consider other factors including care givers' preferences and availability for close monitoring.

References: 1. Hoyt CS, Good WV. Acute onset concomitant esotropia: when is it a sign of serious neurological disease? Br J Ophthalmol 1995; 79: 498-501.
2. Liu GT, Hertle RW, Quinn GE, Schaffer DB. Comitant esodeviation resulting from neurologic insult in children. J AAPOS 1997; 1: 143-146.
3. Lyons CJ, Tiffin PA, Oystreck D. Acute acquired comitant esotropia: a prospective study. Eye (Lond) 1999; 13 (Pt 5): 617-620.

Poster #57
Thursday, 9:55 am – 10:55 am

Ophthalmologic Disorders and Risk Factors in Children with Autism Spectrum Disorder (ASD)

Melinda Y. Chang, MD; Nandini Gandhi, MD; Mary O'Hara, MD

University of California, Davis
Sacramento, CA

Introduction: Autism spectrum disorder (ASD) is increasingly prevalent, estimated to occur in 1.68% of children in the United States. Little is known about the risk factors and types of ophthalmologic disorders in this population.

Methods: We conducted a retrospective chart review of all children (0-17 years old) with an ICD diagnosis of ASD seen at a single university over a 10-year period (2007-2017). In patients evaluated at the university eye clinic, demographic data, birth history, co-morbidities, and ophthalmologic findings were recorded. Multiple logistic regression was used to identify risk factors for ophthalmologic disorders.

Results: 2,555 children with ASD were seen at the university during this time period, and 380 (15%) were evaluated in the ophthalmology clinic. Eye exam revealed an ophthalmic diagnosis in 71% of children, of which the most common were significant refractive error (42%), strabismus (32%), and amblyopia (22%). Optic neuropathy occurred in 14 (4%) children. Cerebral palsy (CP) was a significant risk factor for refractive error (OR 3.22, p=0.016), strabismus (OR 3.59, p=0.012), amblyopia (OR 3.49, p=0.0097), and optic neuropathy (OR 14.0, p=0.0009).

Discussion: Ophthalmic disorders occurred in 71% of children with ASD, and the rates of significant refractive error, amblyopia, strabismus, and optic neuropathy exceeded those of the general pediatric population. ASD and CP may have additive risk for the aforementioned disorders.

Conclusion: Children with ASD may be at increased risk for ophthalmologic disorders. Prospective studies are necessary to further characterize this association. Pediatric ophthalmology referral should be considered in children with ASD.

References: Baio J, Wiggins L, Christensen DL, et al. Prevalence of Autism Spectrum Disorder Among Children Aged 8 Years - Autism and Developmental Disabilities Monitoring Network, 11 Sites, United States, 2014. MMWR Surveill Summ 2018; 67:1-23.
Ikeda J, Davitt BV, Ultmann M, Maxim R, Cruz OA. Brief report: incidence of ophthalmologic disorders in children with autism. J Autism Dev Disord 2013; 43:1447-51.

Poster #58
Thursday, 9:55 am – 10:55 am

Ocular Findings in Children with Headache

Lisa Y. Lin, BS; Wei Pan, MS; Gui-Shuang Ying, PhD; Gil Binenbaum, MD, MSCE

Children's Hospital of Philadelphia
Philadelphia, PA

Introduction: Children with headache are commonly evaluated by ophthalmologists. We determined the prevalence of ocular findings that suggest an ocular cause for headache or occult neurological disease, among children with headache.

Methods: Retrospective cross-sectional study of children with headache, undergoing complete eye examination, with or without cycloplegic refraction, over a 4-year period.

Results: Of 1,878 children (mean age 10 years, range 2-18; 1,632 with cycloplegic refraction), 492 (26.1%) had one or more ocular findings that could cause headache or be indicative of intracranial disease: refractive issue significant enough to possibly cause asthenopia (342; 18.2% overall, 21% of those with cycloplegic refraction), strabismus (83, 4.4%), optic disc swelling (51, 2.8%), uveitis (6, 0.3%), extra-ocular inflammation (5, 0.3%), glaucoma (2, 0.1%), and other (5, 0.3%). Evaluation of disc swelling revealed pseudopapilledema (25), idiopathic intracranial hypertension (15), meningitis (2), shunt malfunction (2), and 1 each with brain tumor, cerebritis, chiari-malformation, CNS vasculitis, traumatic venous thrombosis, subdural hematoma. Short (<1 month) duration was associated with presence of ocular cause for headache, but headache frequency, headache characteristics, photophobia, nausea/vomiting, or visual aura/changes were not. Nausea/vomiting, visual changes/aura, and morning headache were associated with disc swelling ($p<0.02$).

Discussion: Generally, the presence or absence of coincident visual, ocular, or systemic symptoms are not reliable predictors of ocular pathology in children with headache; though some features may suggest the presence of optic disc swelling.

Conclusion: A full ophthalmologic examination, including cycloplegic refraction, is indicated in the diagnostic workup of children with headache, as up to a quarter of children may have significant findings.

References: Linet MS, Stewart WF, Celentano DD, Ziegler D, Sprecher M. An epidemiologic study of headache among adolescents and young adults. JAMA 1989;261:2211-6.

Poster #59
Thursday, 9:55 am – 10:55 am

Clinical Implications of ERG Monitoring for Vigabatrin Toxicity

Benjamin G. Jastrzembski; Jeff Locke; Michael Wan

Hospital for Sick Children / University of Toronto
Toronto, Ontario, Canada

Introduction: Monitoring for retinal toxicity with electroretinography (ERG) in children on vigabatrin for infantile spasms is a well-established practice.1, 2 However, the cost-effectiveness of ERG screening and the effect on clinical decision-making has not been determined.

Methods: All patients who underwent an ERG for vigabatrin screening from 2015-2018 were included. 30 Hz flicker amplitudes and complete ERG results were recorded and analyzed. Adjustments to clinical management due to ERG results were identified on chart review. Cost estimates were based on hospital and billing data.

Results: 67 patients received screening ERGs for vigabatrin toxicity during the study period. There were a total of 147 ERGs (median of 2 per patient) and a median length of treatment of 7 months. Three patients were identified as suspicious for retinal toxicity, but none met established criteria for evidence of toxicity.1 In the cases identified as suspicious for toxicity, the ERG results did not change clinical management. The cost for an ERG was $1,466 in the operating room and $599 in the outpatient clinic under sedation. The total estimated cost of testing was $114,962 or $1,716 per patient.

Discussion: ERG monitoring of children on short duration vigabatrin treatment did not change clinical management, was expensive, and required sedation or anesthesia.

Conclusion: ERG evidence of retinal toxicity is rare when vigabatrin treatment duration is short.3 ERG monitoring may be most useful when vigabatrin treatment may be prolonged or when treatment decisions will be based on the presence or absence of retinal toxicity.

References: 1. Westall CA, Wright T, Cortese F. Vigabatrin retinal toxicity in children with infantile spasms. 2014;7.
2. Sergott RC, Wheless JW, Smith MC, Westall CA, Kardon RH, Arnold A, et al. Evidence-based Review of Recommendations for Visual Function Testing in Patients Treated with Vigabatrin. Neuro-Ophthalmology. 2010 Feb;34(1):20–35.
3. Pellock JM, Hrachovy R, Shinnar S, Baram TZ, Bettis D, Dlugos DJ, et al. Infantile spasms: A U.S. consensus report: Infantile Spasms. Epilepsia. 2010 Oct;51(10):2175–89.

Poster #60
Thursday, 9:55 am – 10:55 am

Longitudinal Change of Buried Optic Disc Drusen in Children

Hyun Joo Kee, MD; Se Joon Woo, MD; Jeong-Min Hwang, MD

Seoul National University Hospital
Seoul, Korea

Introduction: Buried optic disc drusen (ODD) or peripapillary hyperreflective ovoid mass-like lesions (PHOMS) are clinically important due to the difficult differentiation from the papilledema. The purpose of this study was to investigate how ODD change over time.

Methods: Forty children (50% male) </= 17 years diagnosed as having buried ODD using funduscopy and OCT with follow-up for 12 months or longer were included in this study. Temporal change of ODD on fundus photography and OCT as well as refractive errors, height of ODD, horizontal to vertical disc diameter ratio and relative halo index were evaluated.

Results: ODD was present in both eyes (23 children), right eye (11), and left eye (6). Relative halo index minimally increased by +0.02 in average. Mean ODD height increased from 551.12 to 572.42 µm. Eleven (27.5%) out of 40 children showed a significant change in halo around the optic disc, of which association with initial ODD height and myopic progression. However, horizontal to vertical disc diameter ratio was not different. None of the buried ODD became visible by fundoscopy during the mean follow-up periods of 47.6 months. In one patient, we observed the formation of a de novo ODD that were aggregated by small fragments of subretinal deposits nasal to the optic disc.

Discussion: We presented the serial results of funduscopy as well as OCT findings of ODD in Asian children.

Conclusion: Part of buried ODD showed enlargement and distinctiveness during the follow-up period. The temporal change was associated with the size of ODD and the myopic progression.

References: 1, Lee KM, Woo SJ, Hwang JM. Differentiation of optic nerve head drusen and optic disc edema with spectral-domain optical coherence tomography. Ophthalmology. 2011;118(5):971-7.
2. Lee KM, Woo SJ, Hwang JM. Morphologic characteristics of optic nerve head drusen on spectral-domain optical coherence tomography. Am J Ophthalmol. 2013;155(6):1139-1147.
3. Lee KM, Woo SJ, Hwang JM. Differentiation between optic disc drusen and optic disc oedema using fundus photography. Acta Ophthalmol. 2017 Jun;95(4):e329-e335.
4. Lee KM, Woo SJ, Hwang JM. Factors associated with visual field defects of optic disc drusen. PLoS One. 2018 Apr 30;13(4):e0196001.
5. Lee KM, Woo SJ, Hwang JM. Peripapillary Hyperreflective Ovoid Mass-LikeStructures: Is It Optic Disc Drusen or Not? J Neuroophthalmol. 2018 Jun 12.

Poster #61
Thursday, 9:55 am – 10:55 am

Test-Retest Reliability of Goldmann Perimetry in Children with NF-1 Associated Optic Pathway Glioma

Sarah Whitecross, MMedSci, OC(C), CO; Bilal Al Wattar, MB, ChB; Nicole Ullrich, MD, PhD; Gena Heidary, MD, PhD

Boston Children's Hospital
Boston, MA

Introduction: Neurofibromatosis type 1 (NF-1) associated optic pathway gliomas (OPGs) may cause profound loss of vision and visual field (VF). Many children undergo formal VF testing to monitor for signs of tumor progression. The purpose of this study is to determine the test-retest reliability and variability of testing using Goldmann perimetry in children with NF-1-associated OPGs in an effort to provide evidence-based guidelines for tumor progression.

Methods: Children between 4 and 18 years with NF-1 and an OPG were enrolled in this prospective, cross-sectional study. A single perimetrist performed Goldmann perimetry using targets III4e and I4e which was repeated within the visit. Mean visual field areas were digitized and calculated using Adobe Photoshop CS3 for analysis.

Results: Fourteen (71% male) patients participated. Mean age at enrollment was 12 years (range 6.6 to 17.3) and 3 (21%) participants had a VF defect. Mean total planimetric area was 166.37cm^2 for III4e targets and 127.66 cm^2 for I4e targets. There was significant correlation between tests for each isopter and eye. The variability of testing was found to have a maximum range of 8.13% decrease in area to 10.25% increase in area for the III4e target and 10.37% decrease in area to 13.01% increase in area for the I4e isopter and was not correlated with the participant's age.

Discussion: Goldmann perimetry testing in children with NF-1 associated OPGs is feasible and shows good test-retest reliability.

Conclusion: Goldmann perimetry is important for evaluating VF dysfunction in children with NF-1 associated OPGs, and quantitative studies defining the variability of testing are relevant for monitoring tumor progression.

References: 1. Patel DE, Cumberland PM, Walters BC, Russell-Eggitt I, Cortina-Borja M, Rahi JS. Study of Optimal Perimetric Testing in Children (OPTIC): Feasibility, reliability and repeatability of perimetry in children. PLoS ONE 2015; 10(6): 1-12.
2. Quinn GE, Fea AM, Minguini N. Visual fields in 4 to 10 year old children using Goldmann and double-arc perimeters. J Pediatr Ophthalmol Strabismus 1991; 28; 314-319.
3. Zahid S, Peeler C, Khan N, Davis J, Mahmood M, Heckenlively JR, Jayasundera T. Digital quantification of Goldmann visual fields (GVFs) as a means for genotype-phenotype comparisons and detection of progression in retinal degenerations. Adv Exp Med Biol, 2014; 801:131-137.

Poster #62
Thursday, 9:55 am – 10:55 am

Conjunctival Nevi in Children: Clinical and Anterior Segment Optical Coherence Tomography Features

Manca Tekavcic Pompe, Dr; Špela Markelj; Lavric Groznik Alenka

University Eye Clinic
Ljubljana, Slovenia

Introduction: Melanocytic conjunctival nevus is the most common pediatric conjunctival tumor. Nevus usually becomes visible in the first to the second decade. It can vary in colour, size, presence of intrinsic cysts and vascularity. Absence of feeder vessel and presence of intrinsic cysts is usually consistent with benign lesion. Malignant transformation is less than 1% and surgical removal is performed for cosmetic reason or suspected malignancy. The aim of the study was to describe the anterior segment optical coherence tomography (AS-OCT) characteristics of conjunctival nevus.

Methods: Prospective interventional case series. Eighteen patients with conjunctival nevus were evaluated clinically with slit-lamp and conjunctival lesions were imaged with AS-OCT. Histopathology results of excised lesions were collected.

Results: The mean patients age was 10.3 years (range 6-16). All lesions were optically solid. The mean nevus thickness was 0.47 Â± 0.16 mm with mean basal diameter 3.94 Â± 1.18 mm. Dome shaped configuration was noticed in 14 cases (77.8 %). Nevus margins were seen in all patients (100 %). Posterior shadowing was present in 14 eyes (77.8 %). Histopathology confirmed compound nevus in 17 (94.4 %) and combined in 1 case (5.6 %). Intrinsic cysts were noticed clinically in 7 (38.9 %), on AS-OCT in 10 patients (55.5 %) on and on histopathology examination in 9 (50 %).

Discussion: AS-OCT helps in visualizing the structure of the nevus and could detect intrinsic cysts better than slit-lamp examination.

Conclusion: AS-OCT has proven to be an important non-invasive tool in determining characteristics of conjunctival nevi in children.

References:

Poster #63
Thursday, 9:55 am – 10:55 am

Prevalence and Clinical Features of Orbital Vascular Anomalies in Children

Laura A. Torrado, MD; Gregory J. Griepentrog, MD; Brian G. Mohney, MD

Mayo Clinic
Rochester, Minnesota

Introduction: While vascular anomalies have been reported to occur in up to 1% of children, there are no population-based studies describing the prevalence of orbital vascular anomalies. The purpose of this study was to report the birth prevalence, demographics, and ocular sequelae of orbital vascular anomalies diagnosed in children over a 50-year period.

Methods: The medical records of all children (<19 years) diagnosed with a post-septal orbital vascular anomaly from January 1, 1966, through December 31, 2015, were retrospectively reviewed.

Results: A total of 109 children were diagnosed with an orbital vascular anomaly, including 25 from an isolated county in Minnesota, yielding a birth prevalence of 1 in 4305 births. The median age at diagnosis was 1.2 (0 to 17.9) years and 67 (61.5%) were female. There were 55 (50.5%) vascular malformations [50 (91%) low-flow lymphatic malformations, 3 (5.5%) high-flow arteriovenous malformations, and 2 (3.5%) low flow venous malformations] and 54 (49.5%) vascular tumors [53 (98%) orbital hemangiomas and 1 (2%) case of kaposiform hemangioendothelioma]. During a mean follow-up of 5.95 years (range 0 to 27.7) years, amblyopia was diagnosed in 46 (43.4%) patients and strabismus in 44 (42.3%) patients.

Discussion: This study reports the previously unknown birth prevalence of pediatric orbital vascular anomalies as approximately 1 in 4300 births.

Conclusion: Hemangiomas and low-flow lymphatic malformations comprised more than 90% of the orbital vascular anomalies in this cohort with significant ocular sequelae, including amblyopia and strabismus, occurring commonly.

References: 1. Stacey AW, Gemmete JJ, Kahana A. Management of Orbital and Periocular Vascular Anomalies. Ophthal Plast Reconstr Surg 2015;31:427-436.
2. Rootman J. Vascular malformations of the orbit: hemodynamic concepts. Orbit 2003;127:22:103-20.
3. Harris GJ. Orbital vascular malformations: a consensus statement on terminology and its clinical implications. Orbital Society. Am J Ophthalmol 1999;127:453-5.

Poster #64
Thursday, 9:55 am – 10:55 am

Effect of Oral Propranolol in Astigmatism-Induced Orbital Haemangioma

Nora Aldohayan, MD; Yasser Al-Thnayan, MD

PRINCE SULTAN MEDICAL MILITARY CITY
SAUDIA ARABIA, RIYADH

Introduction: Capillary haemangiomas are the most common orbital tumor in infancy, with a course of rapid proliferation followed by spontaneous regression (1). It may cause astigmatism or amblyopia reaching up to 60% of the cases (2). We report 2 cases with amblyogenic orbital haemangioma that has been treated with oral propranolol with remarkable response.

Methods: We reviewed 7 patients with orbital capillary haemangioma that presented to our clinic between 2012-2018, Out of which, 2 cases displayed amblyogenic astigmatism with refraction +0.50-7.00 x 170 of the right eye, and +0.5 -7.50 x 160 of the right eye, of an 11-months old female, and a 2-months old male, consecutively . Oral propranolol was started with dose of 0.3mg/kg/day TID then gradually increased. Refraction was recorded after initiating propranolol.

Results: The first case showed refraction of +2.00 -2.50 x 180 7 months after starting treatment, while the second case showed refraction of +4.00 -4.50 x 70 after 9 days of starting treatment, and 1-month follow-up displayed +3.00 -2.50 D x 135. Adverse events were not encountered.

Discussion: Oral propranolol has decreased the cylindric power in both cases with 64.29% decrease in the first case in the course of 7 months, and 66.67% for the second case, in 1 month, however propranolol demonstrated a rapid improvement in after only 9 days of starting the treatment reaching to -4.50 DC down from -7.50 DC with over 35 % drop in cylindric power

Conclusion: Oral propranolol decreases cylindric power significantly to non-amblyogenic levels in orbital haemangioma in a short duration varying from 1-7 months.

References: 1-Thoumazet F, Leaute-Labreze C, Colin J, Mortemousque B. Efficacy of systemic propranolol for severe infantile haemangioma of the orbit and eyelid: a case study of eight patients. Br. J. Ophthalmol. 2012; 96: 370-4.
2- Fay A, Nguyen J, Jakobiec FA,Meyer-Junghaenel L,WanerM. Propranolol for isolated orbital infantile haemangioma. Arch Ophthalmol 2010; 128: 256-258.

Poster #65
Thursday, 9:55 am – 10:55 am

The Use of 3-D Reconstruction Technology in the Treatment of Severe Bilateral Ocular and Facial Trauma from Dog Bite

Catherine S. Choi, MD; Alison Callahan, MD; Andrew Scott, MD

Tufts Medical Center
Boston, MA

Introduction: Dog bites affect 4.5 million Americans per year and account for up to 1% of emergency room visits in the United States. In young children, dog bite injuries typically affect the head and neck, but the protective blink reflex makes direct trauma to the globe uncommon. We report a case of a 17-month-old girl who sustained severe facial trauma and bilateral globe injuries from a dog bite. Surgical repair was guided by 3-D technology for orbital reconstruction.

Methods: A 17-month-old girl sustained severe dog bite trauma to her face and presented with a large scleral rupture of the right eye. She also had multiple full-thickness right eyelid lacerations causing transection of the right levator muscle, and complete luxation of the left globe caused by crushing nasal bone injuries displacing fragments of bone into the left orbit.

Results: One week after acute surgical repair, the pediatric otolaryngology team performed a complex reconstruction of the patient's nasal and orbital defects using 3-D reconstructive imaging and printing models.

Discussion: 3-D modeling tools are useful in the preoperative planning of complex craniofacial defects and help to decrease the cost and time of surgery. They can also be instrumental in accurately positioning and placing any reconstructive tissues or implants, as seen in our case.

Conclusion: Globe injuries secondary to dog bite trauma are uncommon. We present a rare case of a child who sustained bilateral globe injuries from a severe dog bite and underwent surgical repair that was guided by 3-D reconstructive technology.

References: 1. Weiss HB, Friedman DI, Coben JH. Incidence of dog bite injuries treated in emergency departments. JAMA. 1998;279(1):51. doi:10.1001/jama.279.1.51.
2. Erickson BP, Feng PW, Liao SD, et al. Dog bite injuries of the eye and ocular adnexa. Orbit. Doi:10.1080/01676830.2018.1470190.
3. Nyberg EL, Farris AL, Hung BP, et al. 3D-Printing Technologies for Craniofacial Rehabilitation, Reconstruction, and Regeneration. Ann Biomed Eng. 2017 Jan; 45(101: 45-57. doi:10.1007/s10439-016-1668-5.

Poster #66
Thursday, 9:55 am – 10:55 am

Quality of Life and Visual Perception in Children and Young Adults with Anophthalmia and Microphthalmia Treated with Ocular Prosthesis

Marita Andersson Gronlund, MD, PhD[1,2]; Beatrice Casslén[1]; Ylva Jugard[3]; Rezhna Taha Najim[1]; Marie Odersjo[4]; Alexandra Topa[5]

[1]Institute of Neuroscience and Physiology, Department of Clinical neuroscience, Sahlgrenska Academy at the University of Gothenburg, Gothenburg, Sweden
[2]Department of Ophthalmology, Sahlgrenska University Hospital, Mölndal, Sweden.
[3]Department of Ophthalmology, Södra Älvsborg Hospital, Borås, Sweden.
[4]Department of Otolaryngology, Sahlgrenska University Hospital, Gothenburg, Sweden.
[5]Department of Clinical Genetics, Sahlgrenska University Hospital, Gothenburg, Sweden.

Introduction: The aim was to evaluate health-related quality of life (HRQoL), vision-related (VR)QoL and visual perceptual problems (VPPs) among anophthalmia (A) and microphthalmia (M) patients treated with ocular prosthesis.

Methods: 17 individuals (mean age 9.0 years; range 1.7-32.8) with unilateral A/M participated. Four validated instruments measuring HR- and VR-QoL were used: 1) PedsQL, consisting of physical and psychosocial (emotional, social and school functioning) self-report (>=5yrs) and parent-proxy (2-18 yrs); 2) CVFQ (<=7yrs); 3) EYEQ (>=8yrs); 4) VFQ-25 (>=21yrs). VPPs were assessed by history taking.

Results: A/M patients and their parents scored low in HR-QoL (PedsQL total score: 60.9; 69.6) compared with controls (83.0; 87.61) ($p<0.0001$; respectively). No difference between children and parents were found, however, parents trended to underestimate their children's emotional state. A/M children having subnormal visual acuity (VA) (ft<=20/32; LogMAR>=0.20), scored lower in school functioning compared with normal sighted A/M children; ($p=0.026$). CVFQ and EYEQ showed no difference in VR-QoL regarding A/M children compared with controls or children having subnormal VA or not. 8/12 A/M children exhibited VPPs in one or more areas compared with 4/118 controls ($p<0.0001$).

Discussion: A/M individuals have poor HR-QoL and increased VPPs. No difference in QoL was found between children and parents even though the children trended to score lower in emotional well-being. Individuals with A/M having subnormal vision rated significant less capability in school functioning.

Conclusion: These neglected problems elucidate the necessity of thorough examination, individual assessment followed by appropriate treatment and support concerning children diagnosed with A/M treated with ocular prosthesis.

References: 1.Slavotinek AM. Eye development genes and known syndromes. Mol Genet Metab 2011:104;448-56.
2. Dahlmann-Noor A, Tailor V, Abou-Rayyah Y, et al. Functional vision and quality of life in children with microphthalmia/anophthalmia/coloboma-a cross-sectional study. J AAPOS 2018:22;281-85.

Poster #67
Thursday, 9:55 am – 10:55 am

Outcome of Primary Probing for Congenital Nasolacrimal Duct Obstruction in Older Children

Margaret M. Reynolds, MD; Katharine Liegel, MD; Gregg T. Lueder, MD

Washington University/Saint Louis Children's Hospital
Saint Louis, Missouri

Introduction: Previous reports have suggested that outcomes of nasolacrimal duct (NLD) probing may be decreased in older children. The purpose of this study was to report outcomes of NLD probing in children four years of age and older.

Methods: The records of all patients 4 years and older with uncomplicated congenital NLD obstruction who underwent surgery from 1997 through 2015 were retrospectively reviewed. In all patients, simple membranous obstruction was present at the distal duct and was relieved with the passage of the probes. Children with Trisomy 21, trauma, other lacrimal passage anomalies (punctual/canalicular stenosis), and craniofacial abnormalities were excluded. Successful outcome was determined by resolution of epiphora and periocular crusting.

Results: Eighteen patients ranging from 4 to 8 years of age with membranous nasolacrimal duct (NLD) obstruction were treated. Sixteen of 18 (88.9%) patients had good outcomes following NLD probing. Two patients had persistent symptoms that resolved following balloon dilation and stent placement.

Discussion: This study found that the success rate of probing in older patients with simple membranous NLD obstruction was comparable to that of younger patients.

Conclusion: NLD probing alone is a good treatment option for older children with simple membranous NLD obstruction. Additional procedures such as balloon catheter dilation or stent placement are not needed at the time of initial probing.

References: Katowitz JA, Welsh MG. Timing of initial probing and irrigation in congenital nasolacrimal duct obstruction. Ophthalmology. 1987;94:698-705.
Kushner BJ. The management of nasolacrimal duct obstruction in children between 18 months and 4 years old. J AAPOS. 1998;2:57-60.
Robb RM. Success rates of nasolacrimal duct probing at time intervals after 1 year of age. Ophthalmology. 1998;105:1307-9.

Poster #68
Thursday, 9:55 am – 10:55 am

Nasolacrimal Duct Obstruction and the Development of Anisometropia and Amblyopia

Archana A. Nair, MD,MS; Joyce Khandji, MD; Aryeh Lustig; Milan Ranka, MD

New York University
New York

Introduction: Nasolacrimal duct obstruction (NLDO) is an infrequent congenital finding occurring in 5 to 15%(1,2) of newborns. Prior studies have both refuted and supported the association between NLDO and amblyopia(3). This study aims to assess the demographics of patients with NLDO, which is not clearly described in the literature, and further assess the association of amblyopia and anisometropia in patients with NLDO.

Methods: Patients with NLDO seen between 2004 and 2016 at a single clinical center were retrospectively analyzed. Demographic data, age of diagnosis, laterality, presenting symptoms, refractive error, anisometropia (>/=1 D), and amblyopia diagnosis were collected. All statistical analysis was conducted using Stata.

Results: 809 patients with NLDO were identified. Average age of diagnosis was 18.2 months (SD 14.1, range 0-128), 49.69% were female, 40.5% had bilateral NLDO, and 83.81% were Caucasian. 5.19% developed amblyopia. Anisometropia was present in 3.58% of patients at the time of diagnosis. Anisometropia was associated with an increased risk of amblyopia development (15.5% vs. 4.7%, p = 0.00). There was no difference in development of amblyopia in unilateral vs. bilateral disease (4.4% vs. 6.4%, p=0.2).

Discussion: Amblyopia is seen in 2-4%(1) of children in North America. Although development of amblyopia is not increased in unilateral vs. bilateral disease, this study suggests that patients with NLDO are at a higher risk of amblyopia.

Conclusion: Amblyopia occurs at higher rates in patients with NLDO compared with the general population. Therefore, patients with NLDO should be screened for anisometropia at the initial visit and patients should be counseled about the increased risk of amblyopia.

References: 1. Hered, Robert et al. Basic and clinical science course. Section 6: Pediatric Ophthalmology and Strabismus. American Academy of Ophthalmology, San Francisco. 2018.
2. Chalmers, R., Griffiths, P.G.Is congenital nasolacrimal duct obstruction a risk factor for the development of amblyopia? British Orthoptic Journal. 1996; 53: 29-30.
3. Kipp MA, Kipp MA, Struthers W. Anisometropia and amblyopia in nasolacrimal duct obstruction. Journal of AAPOS. 2013; 17:235-238. https://doi.org/10.1016/j.jaapos.2012.11.022

Poster #69
Thursday, 9:55 am – 10:55 am

Predictive Value of Intraocular Lens Power Calculation Formulae in Children.

Asmaa M. Shuaib, MD; Abdelrahman M. Elhhusseiny, MSc; Dina H. Hassanein, MD; Rasha H. Zedan, MD; Hala M. Elhilali, MD

Abo El Rish Hospital
Cairo University- Egypt

Introduction: Intraocular lens (IOL) power calculation is a challenging task in children.

Methods: Retrospective review was done for the data of patients who had primary or secondary IOL implantation in Abo El Rish Hospital from January 2016 to June 2018. The Absolute prediction error (APE) was calculated for SRK-II, SRK-T, Holladay and Hoffer-Q using the patient's axial length (AXL), K-readings, implanted IOL power and refraction performed 1-2 months postoperatively.

Results: The study included 235 patients with mean age of 4.7±3.09 years.

In patients with AXL</=19mm; the percentage of eyes with APE within 0.5D was (6.7%, 46.7%, 33.3% and 13.3%) and the percentage of eyes with APE > 2D was (33.3%, 40%, 40% and 46.7%) for the SRK-II, SRKT, Holladay and Hoffer-Q respectively. The SPK-T was significantly better wheras Hoffer-Q was significantly worse than other formulae (P</=0.035) and (P</=0.047) respectively.

In patients with AXL19-25mm; the percentage of eyes with APE within 0.5D was (30.5%, 34%, 31.5% and 29.1%) and the percentage of eyes with APE > 2D was (22.2%, 21.2%, 21.2% and 25.1%) for the SRK-II, SRKT, Holladay and Hoffer-Q respectively. The SRK-T was significantly better whereas Hoffer-Q was significantly worse than other formulae (P<0.001) and (P=0.002) respectively.

In patients with AXL>/=25mm there was no statistically significant difference between all formulas.

Discussion: These results are consistent with those reported by the reviewed literature.1,2

Conclusion: The SRK-T was the most predictable formula and the Hoffer-Q was the least predictable one in IOL power calculation in children.

References: 1-Kekunnaya R, Gupta A, Sachdeva V, Rao HL, Vaddavalli PK & Om Prakash V. Accuracy of intraocular lens power calculation formulae in children less than two years. Am J Ophthalmol. 2012; 154(1):13-19.
2- Vanderveen DK, Trived RH, Nizam A, Lynn MJ & Lambert SR. Predictability of Intraocular Lens Power Calculation Formulae in Infantile Eyes With Unilateral Congenital Cataract: Results from the Infant Aphakia Treatment Study. Am J Ophthalmol. 2013; 156(6): 1252-1260.

Poster #70
Thursday, 9:55 am – 10:55 am

Digital Biometry in Children Undergoing Cataract Surgery in Vitrectomised Eyes

Sumita S. Agarkar, Dr; Swathi Mailankody

Medical Research Foundation
Chennai , India

Introduction: To report the accuracy of biometry in children undergoing cataract surgery in vitrectomised eyes using SRK-II formula

Methods: A retrospective review of medical records of children undergoing cataract surgery between year 2008 to 2017 with a prior history of pars plana vitrectomy was done. Biometry was performed using Ocuscan Rxp (Alcon)and keratometry was done using a handheld keratometer iOL power calculation was done under general anaesthesia in uncooperative children Adjustment in speed was made in silicon oil filled eyes .The main outcome variable studied was Absolute prediction error (APE). Absolute Prediction Error (APE) was calculated as absolute difference between target refraction and postoperative refraction obtained at 6 weeks.

Results: 92 eyes(90 patients) were included in the study. Mean age at surgery was 12.04±3.33 years. Mean axial length was 24.85±1.94 mm. Mean APE using SRK -II formula was 1.29±1.12 for the entire group. However 35% of the eyes had APE between 0 and 0.5. APE was affected by axial length (p=0.007)

Discussion: IOL power calculation remains challenging in children specially in younger children Various studies over the years have reported mean prediction error involving several different formulae. Kekunnaya et al reported mean APE of 2.27 with SRK 2 There is no such data available for Vitrectomised eyes . Children in this study were older as well as had longer axial lengths compared to that in litreture

Conclusion: Prediction error using SRK-II formula in vitrectomized pediatric eyes is comparable to that in non-vitrectomized eyes as reported in litreture

References: 1-Kekunnaya et al Accuracy of intra ocular lens power calculation formulae in children less than 2 years:AJO 2012 jul;154(1):13-19
2- NihalaniB ,VanderVeenDK Comparison of intraocular lens power calculation formulae in pediatric eyes Ophthalmology2010;117:1493-99

Poster #71
Thursday, 9:55 am – 10:55 am

Practice Patterns in the Surgical Management of Pediatric Traumatic Cataracts

Angela Y. Zhu, MD; Courtney L. Kraus, MD

Johns Hopkins Wilmer Eye Institute
Baltimore, MD

Introduction: Pediatric cataracts are a leading cause of treatable childhood blindness, with 12-41% due to trauma and up to 51% associated amblyopia. Multiple perioperative issues remain controversial, including timing of cataract surgery with globe injuries, intraocular lens (IOL) implantation, and postoperative therapy. Our purpose was to facilitate development of standardized guidelines for management of pediatric traumatic cataract patients by assessing current ophthalmologists' practice patterns.

Methods: A cross-sectional, observational study of current practices pertaining to surgical management of pediatric traumatic cataracts was performed by electronically sending a 24-question survey to pediatric ophthalmologists. Preferences for preoperative evaluation, surgical timing and techniques, and postoperative management were analyzed.

Results: Of the 56 respondents, 62.5% practice in academic settings. Of the 49 (87.5%) performing pediatric ruptured globe repair, 41.7% would perform simultaneous cataract extraction if anterior capsular violation exists; only 4.1% would do so without capsular violation. A majority (50.9%) would remove visually significant cataracts within 4 weeks for amblyogenic-aged patients; 63.6% would wait longer outside amblyogenic range. Preferences for IOL target calculation and selection, primary posterior capsulotomy, and timing of amblyopia therapy differ.

Discussion: Individual management practices regarding pediatric traumatic cataracts vary depending on associated globe injuries and patient age. Trends exist in surgical planning, intraoperative techniques, and visual rehabilitation methods, but no single decision achieved complete unanimity.

Conclusion: No consensus exists on the management of pediatric traumatic cataracts. Therefore, further investigation into optimal timing and extent of surgical intervention, refractive correction, and postoperative care is necessary prior to developing evidence-based guidelines for enhancing visual outcomes in this population.

References: 1. Kinori M, Tomkins-Netzer O, Wygnanski-Jaffe T, et al. Traumatic pediatric cataract in southern Ethiopia-results of 49 cases. J AAPOS 2013;17:512-515.
2. Yardley AM, Ali A, Najm-Tehrani N, et al. Refractive and visual outcomes after surgery for pediatric traumatic cataract. J Cataract Refract Surg 2018;44:85-90.

Poster #72
Thursday, 9:55 am – 10:55 am

Prognostic Factors associated with Poor Visual Outcome of Traumatic Pediatric Cataract: A 10 Years Retrospective Review

Thanidha Vitayavisavasakul, MD; Phanthipha Wongwai, MD; Warachaya Phanphruk, MD; Sirinya Suwannaraj, MD

Khonkaen university
Thailand

Introduction: Traumatic cataract causes significant blindness in children, particularly in developing countries. The purpose of this study is to evaluate causes and factors associated with poor visual outcome of traumatic cataract in children.

Methods: Retrospective chart reviewed of all patients age ≤ 18 years whose diagnosed traumatic cataract from 2007-2016 at Srinagarind Hospital, a tertiary referral center of northeast of Thailand.

Results: Eighty-four eyes from 84 consecutive patients were reviewed. Mean age at diagnosis was 9 ± 4.7 years (range 1-18). Male was predominantly affected (77.4 %). Mean presenting visual acuity was 2.25 ± 0.5 logMAR. A majority of patients had penetrating injuries (63.1 %), which houseware sharp objects (14.3 %) and firecrackers (13.1 %) were the two leading causes. Associated injuries included corneal perforation (69.1 %), vitreous hemorrhage (22.3 %) and retinal tear (16.7 %). Mean final visual acuity after cataract surgery significantly improved to 1.34 ± 1.02 logMAR ($p < 0.001$). Blindness and low vision (<0.5 logMAR) were found totally 69.1 % which significantly associated with presenting visual acuity < 0.5 logMAR ($p < 0.001$), retinal tear ($p = 0.006$) and vitreous hemorrhage ($p = 0.029$).

Discussion: Easily reach out the houseware sharp objects and access to firecrackers reflects the unawareness of household safety and inappropriate law enforcement. Child friendly environments should be applied and selling of firecrackers to children should be strictly controlled.

Conclusion: More than two-third of children with traumatic cataract are end up with low vision and blindness. Health education and awareness of family, society and government are essential tools to prevent.

References: Maida JM, Mathers K, Alley CL. Pediatric ophthalmology in the developing world. Current Opinion in Ophthalmology. 2008;19(5):403-408.

Gilbert C, Foster A. Childhood blindness in the context of VISION 2020--the right to sight. Bull World Health Organ. 2001; 79:227-32.

Gilbert C, Muhit M. Eye conditions and blindness in children: Priorities for research, programs, and policy with a focus on childhood cataract. Indian Journal of Ophthalmology. 2012;60(5):451.

Poster #73
Thursday, 9:55 am – 10:55 am

Referral Basis for Congenital and Juvenile Cataracts

Laura C. Huang, MD; Scott Lambert, MD

Byers Eye Institute, Department of Ophthalmology, Stanford University
Palo Alto, CA 94303

Introduction: It is recommended that newborns with visually significant cataracts undergo cataract surgery by 6-8 weeks of age [1]. We sought to determine the referral basis and timing of referrals for young children with cataracts to a tertiary-care pediatric ophthalmology practice.

Methods: A retrospective chart review was conducted for children age 3 years or younger with a congenital or juvenile cataract. The referral provider (pediatrician, pediatric ophthalmologist, or parents) and the amount of time before the first examination with a pediatric cataract surgeon were evaluated.

Results: A total of 48 patients were included. Average age at presentation was 9 months with 18% of patients younger than 2 months. Referrals were initiated most commonly by pediatric ophthalmologists (75%) followed by pediatricians (16%) and parents (8%). Patients had been previously examined by at least one other ophthalmologist in 79% of cases. Patients referred by a pediatrician waited an average of 3.7 weeks prior to evaluation with a pediatric cataract surgeon compared to 2.1 weeks when referred by a pediatric ophthalmologist.

Discussion: Fewer than 20% of patients with congenital or juvenile cataracts were referred for cataract surgery before 8 weeks of age. A significant percentage of patients received two or more eye examinations prior to referral for surgical management and wait times between referring providers averaged 2.9 weeks.

Conclusion: The process of referring children with cataracts to a pediatric cataract surgeon may result in a delay in cataract surgery. Protocols should be instituted to treat these referrals as urgent to avoid unnecessary delays before surgery is performed.

References: Lambert SR, Lynn MJ, Hartmann EE, et al. Comparison of contact lens and intraocular lens correction of monocular aphakia during infancy: a randomized clinical trial of HOTV optotype acuity at age 4.5 years and clinical findings at age 5 years. JAMA Ophthalmol. 2014;132(6):676-682.

Poster #74
Thursday, 9:55 am – 10:55 am

Is There Any Role for Endoilluminator in Pediatric Cataract Surgery? - Beginner's Perspective

Abhilasha A. Parkhe MS, FPOS; Jyoti Matalia, FICO, DO, DNB; Sumitha M. Muthu, MS; Pooja Ghalla, DO, FPOS; Pratibha Panmand, DO, DNB

Narayana Nethralaya Superspeciality Eye Hospital
Bangalore, India

Introduction: To compare the visualization of posterior capsule (PC) during posterior capsulorhexis using direct microscope illumination and oblique external illumination using endoilluminator, also to compare completeness of anterior vitrectomy (AV) in hands of a novice pediatric surgeon using microscope illumination and using endoilluminator.

Methods: In this prospective observational study, 20 children with cataract (2months to 16years) underwent cataract surgery with primary posterior capsulotomy (PPC) with AV +/- PCIOL implantation. Only when the visualilsation of the structures was poor and the resident was unable to visualize the capsule/ vitreous in direct microscope light, endoilluminator light was used to complete the procedure. All cases were assessed for size and regularity of the PPC and the completeness of AV at the end of the procedure by the expert surgeon.

Results: Of the 20cases operated, endoilluminator was used in 17cases (85%) at different stages of the surgery. 6(35%) of the17 cases required the use of an endoilluminator to visualize the initial nick made in PC for PPC, in10 cases (58.8%) to view the vitreous strands and complete AV and in 2cases (11.7%) to identify anterior capsular opening. In 3cases (15%) the resident was able complete the procedure without using endoilluminator.

Discussion: Pediatric cataract surgery is a challenge to the novice surgeon. Endoilluminator provides better visibility and ensures complete and adequate AV thus preventing complications.

Conclusion: Endoilluminator is a simple tool to aid in visualization of transparent structures like PC and vitreous which may be difficult for a resident in pediatric ophthalmology in the earlier period of the training.||

References: 1 Nishimura A, Kobayashi A, Segawa Y, Sugiyama K. Endoillumination- assisted cataract surgery in a patient with corneal opacity. J Cataract Refract Surg. 2003;29(12):2277-80
2 Matalia J, Anaspure H, Shetty BK, Matalia H. Intraoperative usefulness and postoperative results of the endoilluminator for performing primary posterior capsulectomy and anterior vitrectomy during pediatric cataract surgery. Eye (Lond) 2014;28(8):1008-1013.
3 Matalia J, Rajput V, Matalia H, Shetty BK. Endoilluminator-assisted pediatric cataract surgery with hazy cornea. Indian J Ophthalmol. 2018;66(8):1198-1200.

Poster #75
Thursday, 9:55 am – 10:55 am

Spectacle Adherence Among Four-Year-Old Children in the Infant Aphakia Treatment Study

Scott R. Lambert, MD; Lindreth DuBois, Med; George Cotsonis, MA; E. Eugenie Hartmann, PhD; Carolyn Drews-Botsch, PhD

Stanford University School of Medicine
Stanford, CA

Introduction: Most children who undergo unilateral cataract surgery during infancy have reduced vision in their treated eye. It is important that these children wear protective eye wear to reduce their risk of injuring their good eye.

Methods: The Infant Aphakia Treatment Study is a multicenter clinical trial that randomized 114 children to contact lens correction or intraocular lens implantation following unilateral cataract surgery during infancy. As a secondary outcome, we assessed spectacle adherence with impact resistant lenses using one week diaries completed annually and retrospective telephone interviews conducted every 3 months to age 5 years. All data from telephone interviews and diaries completed between ages 4 to 5 years were averaged to determine spectacle adherence. Visual acuity was assessed by a traveling examiner at age 4.5 years.

Results: Children with 20/40 or better vision in their treated eye were more likely to wear spectacles ≥80% of their waking hours than children with vision worse than 20/40 (66% vs 42%, p=0.034). Spectacle adherence did not correlate with gender, type of healthcare insurance or the refractive error in the treated or fellow eye, but was associated with adherence to prescribed patching. Seven patients with 20/200 or worse vision in their treated eye reported <10% spectacle adherence.

Discussion: These results confirm that it is possible to achieve high levels of spectacle adherence among 4-year-old children after unilateral cataract surgery during infancy.

Conclusion: Children with vision worse than 20/40 in their worse eye, who needed eye protection the most, had the worst adherence.

References: 1. Protective eyewear for young athletes. American Academy of Pediatrics Committee on Sports Medicine and Fitness and American Academy of Ophthalmology Committee on Eye Safety and Sports Ophthalmology. Pediatrics. 1996;98:311-313.
2. Drews C, Celano, M., Cotsonis, G., Hartmann, E.E., Lambert, S.R. The relationship between occlusion therapy and optotype visual acuity at 4 Â½ years using data from a randomized clinical trial, the Infant Aphakia Treatment Study. JAMA Ophthalmol. 2016;134:863-869
3. Matter KC, Sinclair SA, Xiang H. Use of protective eyewear in U.S. children: results from the National Health Interview Survey. Ophthalmic Epidemiol. 2007;14:37-43.

Poster #76
Thursday, 9:55 am – 10:55 am

Long Term Outcomes of Secondary Intraocular Lens Implantation in Children

Bharti R. Nihalani-Gangwani, MD; Deborah K. VanderVeen, MD

Boston Children's Hospital
Boston, MA

Introduction: To report long term outcomes of secondary intraocular lens (IOL) implantation in pediatric eyes|

Methods: Retrospective case review of pediatric patients with secondary IOL implantation between Jan 1999 to Sept 2018 for childhood aphakia. The patients had in-the-bag (ITB) or sulcus IOL. Single piece acrylic IOL was used for ITB and 3-piece for sulcus IOL. Sutured IOLs were excluded. We evaluated visual acuity outcomes and rate of complications at the last followup visit.

Results: 106 eyes of 70 patients had secondary IOL implantation, with mean followup of 5.4 + 3.8 years. Mean age at primary surgery was 1.0 year; mean age at secondary IOL implantation was 8.0 + 5.7 years. 62 eyes (58.5%) had ITB and 44 (41.5%) eyes had sulcus IOL. 46 eyes (43.4%) had visual acuity > 20/40 at last followup. 16/106 eyes (15%) had glaucoma. Eyes that developed glaucoma had early primary surgery (mean, 0.3 years, $p < 0.001$, significant), and were more likely to have sulcus implantation(10/16, (62.5%, $p=0.1$, not significant). IOP was controlled medically in all eyes except one, which required 2 trabeculectomies. 4 additional eyes have ocular hypertension, and are being monitored closely with no treatment. 2 eyes have mild decentration that is noted after pupillary dilation. 1 eye required IOL exchange after subluxation of sulcus IOL.

Discussion: Sulcus IOL is not a risk factor and does not adversely affect the outcomes of secondary IOL in children. |

Conclusion: Secondary IOL implantation shows satisfactory visual acuity outcomes and low complication rate. Glaucoma is the main complication that requires close monitoring.

References: 1. Nihalani BR, VanderVeen DK. Secondary intraocular lens implantation after pediatric aphakia. J AAPOS 2011;15:435-40
2. Trivedi RH, Wilson ME Jr, Ficciani J. Secondary intraocular lens implantation for pediatric|aphakia. J AAPOS 2005;9:346-52
3. Awad AH, Mulllaney PB, Al-Hamad H et al. Secondary posterior chamber intraocular lens implantation in children. J AAPOS 1998;2:269-74.

Poster #77
Thursday, 9:55 am – 10:55 am

Does Secondary Intraocular Lens Implantation Cause or Worsen Glaucoma in Children?

Peter J. Ness, MD; Colette Jackson; Thomas L. Offerle; Rupal H. Trivedi; M. Edward Wilson

Medical University of South Carolina
USA

Introduction: Onset or worsening of glaucoma following secondary IOL implantation is a concern for patients after surgery for congenital cataract. Our goal was to compare intraocular pressure (IOP) control before and after secondary intraocular lens (IOL) implantation in children.

Methods: This was a retrospective chart review of consecutive pediatric patients who underwent secondary IOL implantation between 2000 and 2018. This study was verified as IRB exempt by the IRB. We analyzed IOP and glaucoma medications pre-operatively and 2-12 months after surgery.

Results: A total of 250 eyes underwent secondary IOL implantation during this period. 74 of these eyes qualified to be included in this study (we are continuing data collection and expect this number to increase significantly). Median age at the time of secondary IOL implantation was 6.83 years. Mean preoperative IOP was 16.72 mmHg, compared to the mean postoperative IOP of 17.35 mmHg (P=0.331, paired T-test). Of the 74 eyes, 63 (85.1%) required the same number of glaucoma medications after surgery as before surgery, 8 (10.8%) required more medications, and 3 (4.1%) required fewer medications (P = 0.058, Wilcoxon signed rank test). No eyes required glaucoma surgery in this follow-up period.

Discussion: The vast majority of patients do not have any worsening of IOP control after the initial healing period following secondary IOL implantation. Approximately 11% required additional topical medications but none required surgery.

Conclusion: Secondary IOL implantation carries a relatively low risk of causing or worsening glaucoma in children, but patients should be followed to prevent uncontrolled IOP.

References: 1. Trivedi RH, Boden JH, Mickler C, Wilson ME. Intraocular pressure elevation during early postoperative period after secondary intraocular lens implantation in children and adolescents. J Cataract Refract Surg. 2012;38(9):1633-6.

Poster #78
Thursday, 9:55 am – 10:55 am

Changes in Intraocular Pressure and Anterior Chamber Angle after Congenital Cataract Extraction

Jylan Gouda; Abdelrahman Elhusseiny; Reham H. Tomairek; Dina Elfayoumi; Ahmed Awadein; Ghada Gawdat; Hala Elhilali

Cairo University Children's Hospital
Cairo- Egypt

Introduction: The Abouelreesh Pediatric Cataract Database (APCD) is an electronic database started on January 2016 to record data of pediatric cataract cases performed in Cairo University Children's Hospital with minimal data loss.

Methods: Demographic and clinical characteristics, including IOP and anterior chamber angle (ACA), of children =< 5 years who had surgery for congenital cataract and completed 1 year follow up were studied.

Results: A total of 131 patients (206 eyes) completed 1 year (mean age = 13.3 ± 15.8 months, 73 males, 56%) of whom 56 patients (86 eyes) completed 2 years follow up. IOP elevation >= 18 mmHg occurred in 20 patients (23 eyes = 11%) in year 1 and in another 9 patients (11 eyes = 13%) in year 2. Risk factors for IOP elevation were higher central corneal thickness (P = 0.01) in year 1, and age of surgery =< 2 months (P = 0.01) and aphakia (P = 0.05) in Year 2. Corneal diameter, axial length, surgical approach, and cataract type were not associated with higher risk of elevated IOP. In those with preoperative open ACA, angle narrowing occurred in 48% during year 1 and in another 9% during year 2. Postoperative ACA closure was associated with elevated IOP in 12% in the year 1 and in another 2% in year 2.

Discussion: Children may continue to develop IOP elevation and angle changes for at least 2 years after surgery.

Conclusion: Continuous monitoring of the IOP and the ACA is mandatory after pediatric cataract surgery.

References: 1-Trivedi RH, Wilson ME, Golub RL. Incidence and risk factors for glaucoma after pediatric cataract surgery with and without intraocular lens implantation. J AAPOS. 2006;10(2):117-123.
2-Watts P, Abdolell M, Levin a V. Complications in infants undergoing surgery for congenital cataract in the first 12 weeks of life: Is early surgery better? J AAPOS. 2003;7(April):81-85.
3-Beck AD, Freedman SF, Lynn MJ, Bothun E, Neely DE, Lambert SR. Glaucoma-related adverse events in the infant aphakia treatment study: 1-year results. Arch Ophthalmol. 2012;130(3):300-305.

Poster #79
Thursday, 9:55 am – 10:55 am

Unexpected Returns to the Operating Room within 3 Months After Pediatric Cataract-Related Intraocular Surgery: Indications and Risk Factors

Colette M. Jackson, MD; Peter Ness, MD; Matthew Bickford; Rupal H. Trivedi; M. Edward Wilson

Medical University of South Carolina
USA

Introduction: To evaluate the indications and associated risk factors for unexpected returns to the operating room (OR) within 90 days following pediatric cataract-related surgery.

Methods: This was a retrospective chart review of consecutive patients undergoing either cataract extraction or secondary IOL implantation.

Results: 1393 qualifying medical charts were reviewed. A total of 48 unexpected reoperations occurred in 44 patients for a reoperation rate of 3.4%. The most common indications for reoperation were lens cortex re-proliferation (18/48 cases), elevated IOP (10/48), vitreous wick to wound (6/48), and inflammatory pupillary membrane (5/48). Risk factors for unexpected return to the OR included history of traumatic cataract (relative risk 2.55) or age less than one year at time of first surgery (relative risk 3.02). In the absence of these risk factors, reoperation rate was 1.1%.

Discussion: The complications of pediatric cataract surgery have been well-researched1; however their incidence in the immediate postoperative period has not. Since returns to the OR are often used as a measure of quality of care, it is important to establish baseline frequencies segregated among subtypes within the pediatric cataract population and to establish which of these are modifiable with improved technique. When discussing pediatric cataract-related surgery with parents, it would be beneficial to be able to quantify the risk of such complications.

Conclusion: Unexpected return to the OR after pediatric cataract surgery is uncommon, but when it does occur, it is more common in the setting of trauma or surgery performed before the age of one.

References: Whitman, Vanderveen. Complications of Pediatric Cataract Surgery. Semin Ophthalmol. 2014 Sep-Nov;29(5-6):414-20

Poster #80
Thursday, 9:55 am – 10:55 am

Clinical Experience in an Ocular Genetics Tertiary Care Clinic

Robert S. Lowery, MD; John Dehnel; Sami Uwaydat, MD; G. Bradley Schaefer, MD

University of Arkansas for Medical Sciences
Little Rock, AR

Introduction: The Ocular Genetics Clinic at the University of Arkansas for Medical Sciences (UAMS) began in 2009 and utilizes the expertise of combined genetics and ophthalmic teams to better diagnose patients with genetic diseases.

Methods: A chart review of patients seen in the Ocular Genetics Clinic, was conducted. The top diagnoses and rates of genetic testing confirmation were compiled, in addition to frequency of testing and why testing was not accomplished.

Results: 305 patients presented to the Ocular Genetics Clinic. 54% of patients who were evaluated went on to have genetic testing. Of those who did not, approximately 50% declined testing due to (lacking) insurance coverage. The following is a list of the most commonly suspected diseases: retinal dystrophy (57 suspected cases, 33 tested, 11 confirmed), retinitis pigmentosa (55 suspected cases, 35 tested, 13 confirmed), ocular/oculocutaneous albinism (25 suspected, 13 tested, and 6 confirmed), and Stargardt disease (13 suspected, 6 tested, and 5 confirmed).

Discussion: The correlation of clinically suspicious diagnosis and lab based diagnosis is poor, often with less than half of the tested patients being found to have the suspected diagnosis, with the largest barrier to testing being insurance. The highest rate of correlation in our patient population could be found in macular dystrophy.

Conclusion: An ocular genetics evaluation of patients with suspected hereditary disease is a good way to establish a firm diagnosis in patients with suspected hereditary eye conditions, when testing can be completed. Among common diseases, macular dystrophy appears to have the highest rate of lab confirmation, in our series.

References: 1. D'Andrea E, Marzuillo C, Pelone F, De Vito C, Villari P. Genetic testing and economic evaluations: a systematic review of the literature. Epidemiol Prev. 2015 Jul-Aug;39(4 Suppl 1):45-50.
2. Zaneveld J, Siddiqui S, Li H, Wang X, Wang H, Wang K, Li H, Ren H, Lopez I, Dorfman A, Khan A, Wang F, Salvo J, Gelowani V, Li Y, Sui R, Koenekoop R, Chen R. Comprehensive analysis of patients with Stargardt macular dystrophy reveals new genotype-phenotype correlations and unexpected diagnostic revisions. Genet Med. 2015 Apr;17(4):262-70.
3. Marino MJ. Lessons learned from family history in ocular genetics. Curr Opin Ophthalmol. 2015 Jul;26(5):341-5.

Poster #81
Thursday, 9:55 am – 10:55 am

Novel Variant in SLC38A8 Gene Segregating with Foveal Hypoplasia in an Autosomal Recessive South Asian Family

Zia Chaudhuri, MS, FRCS (Glasg), PhD; Jibin John, PhD; Anirban Mukhopadhyay, MSc; Navneesh Yadav, MSc; BK Thelma, PhD

Department of Ophthalmology, Lady Hardinge Medical College, University of Delhi, New Delhi, India and Department of Genetics, University of Delhi South Campus, New Delhi, India
New Delhi, India

Introduction: Mutations in SLC38A8 gene has been reported to be causal for foveal hypoplasia (FH), optic-nerve decussation defects and anterior segment dysgenesis (FHONDA) syndrome. [1-3] We report a novel mutation in SLC38A8 gene in a large two-generation non-consanguineous presumptively autosomal recessive (AR) south Asian family presenting with FH, nystagmus, exotropia (XT) and low vision (LV) in the fifth and seventh of seven siblings.

Methods: Both parents of these seven siblings in this informative family were deceased. Whole exome sequencing (WES) was performed on four of seven siblings [two affected and two unaffected] using Agilent V5 + UTR on an Illumina platform and the data analysed.

Results: WES based variant analysis and bio-informatic statistics demonstrated a homozygous stop-gain mutation in SLC38A8 gene in the affected siblings, confirmed by Sanger sequencing. Optical coherence tomography (OCT) and fundus fluorescein angiography (FFA) confirmed FH in them. Unaffected siblings had normal foveal contour on OCT but were heterozygous for the mutation.

Discussion: Mutations in SLC38A8 gene resulting in the FHONDA syndrome is rare (about twenty cases reported previously globally). [1-3] Its causal role towards FH has been functionally validated in the medaka fish (Oryzias latipes). [2] Heterozygous variants in asymptomatic siblings (parental phenotypes not available) may be considered as an indirect evidence of the disease-causing nature (FH)/functional relevance of this variant in a homozygous state in the absence of functional validation.

Conclusion: WES is a powerful discovery genomic tool which identified a putatively causal, novel homozygous variant in SLC38A8 gene in two siblings of south Asian ancestry with FH.

References: 1. Poulter JA, et al. Recessive mutations in SLC38A8 cause foveal hypoplasia and optic nerve misrouting without albinism. Am J Human Genetics 2013; 93 (6): 1143-50
2. Perez Y, et al. Isolated foveal hypoplasia with secondary nystagmus and low vision is associated with a homozygous SLC38A8 mutation. Eu J Human Genetics 2014; 22(5): 703 - 6
3. Al-Araimi M, et al. A new recessively inherited disorder composed of FH, optic nerve decussation defects and anterior segment dysgenesis maps to chromosome 16q23.3-24.1. Mol Vis 2013; 19: 2165-72

Poster #82
Thursday, 9:55 am – 10:55 am

Connective Tissue Disorders: A Prospective Comparison of Ophthalmic Findings of Marfan Syndrome versus Loeys-Dietz Syndrome

Amgad A. Eldib, MBCHB; Soroosh Behshad, MD; Natalie Weil, MD; Irene Maumenee, MD

Emory Eye Center
Atlanta, Georgia

Introduction: To compare ophthalmic and systemic findings in patients with confirmed genetic diagnosis of Loeys-Dietz Syndrome (LDS) and Marfan Syndrome (MFS) with the intent of identifying distinguishing characteristics

Methods: We conducted a prospective study examining eyes of patients with connective tissue disorders at the 2017 Marfan Symposium.

Results: 52 patients were examined with genetic confirmation of 7 LDS patients and 19 MFS. The mean age of patients with MFS and LDS was 28(3-70) and 26 (10-38), respectively. There was no significant difference in axial length, myopia, or keratometry between the groups. Abnormal topography was found in 53.5% of MFS eyes, 48.5% of which were found to have kerataconus (KCN). In LDS patients, abnormal topography was found in 50% of eyes, of which 75% were found to have KCN. History of retinal detachment was present in 8.9% and lens dislocation in 20% of MFS patients. None of the LDS patients had retinal detachment or lens dislocation. History of aortic aneurysm was present in both groups; 31% of MFS and 28.6% of LDS.

Discussion: When compared to patients with MFS, LDS patients are less likely to have retinal detachment or lens dislocation, however both groups have a high incidence of KCN.

Conclusion: Based on this small study, we conclude that patients with LDS may have differentiating clinical features, however further clinical research is needed. Currently, genetic testing remains the most reliable method to differentiate these conditions.

References: 1. Kinori M et al, Biometry Characteristics in Adults and Children with Marfan Syndrome: From the Marfan Eye Consortium of Chicago, AJO 2017; 177: 144-149
2. Busch C et al, Ocular Findings in Loeys-Dietz Syndrome, Br J Ophthalmol, 2018; 102(8): 1036-1040

Poster #83
Thursday, 9:55 am – 10:55 am

Indirect Ophthalmoscopy Without an Indirect

Kartik S. Kumar, MD

Introduction: Purpose: To describe a novel technique for indirect ophthalmoscopy using surgical loupes with an attached light and condensing lens.

Methods: Using surgical loupes with an attached light and condensing lens, one can perform a fundus exam.

Results: Excellent view of the fundus can be obtained with surgical loupes with an attached headlight

Discussion: This is a novel use for loupes and can be very useful in the operating room. One can use this technique to do a fundus exam after strabismus surgery, or with a sterile condensing lens, one can look for ocular torsion during surgery without having to change headgear.

Conclusion: Either in the operating room or in clinic, surgical loupes with attached light to perform a reasonable fundus exam.

References: None

Poster #84
Thursday, 9:55 am – 10:55 am

Electroretinography Using RETeval ERG System in Children with Diabetes Mellitus

Chenhao Yang; Yan Jia

Children's Hospital of Fudan University
Shanghai, China

Introduction: To evaluate the value of the RETeval device, using flicker electroretinography (ERG) in children with diabetes mellitus (DM).

Methods: We recorded full-field flicker ERGs with this device from 50 normal eyes and 100 eyes in children with DM in Children's Hospital of Shanghai.

Results: The implicit time in eyes with DM was prolonged than that of normal eyes (P = 0.047). Even though the amplitude in eyes with DM was lower than the amplitude in normal eyes, the difference was not significant (P = 0.564).

Discussion: The results demonstrated that the difference about the implicit time of the flicker ERGs between the normal eyes and eyes with no DR was significant. When the course of the disease extending, the implicit times were prolonged. Early diabetes causes deficits in the rod pathway leading to decreased light-evoked rod bipolar cell inhibition and increased rod pathway output that provide a basis for the development of early diabetic visual deficits.

Conclusion: Early screen of ERG was an useful index, which should be carried out in diabetes patients, especially in children with long course (>/=5 yrs.).

References: 1. Kato K, Kondo, M, Sugimoto, M, et al. Effect of pupil size on flicker ERGs recorded with RETeval system: New mydriasis-free full-field ERG system. Invest Ophthalmol Vis Sci 2015;56:3684-90.
2. Maa AY, Feuer WJ, Davis CQ et al. A novel device for accurate and efficient testing for vision-threatening diabetic retinopathy. J Diabetes Complications 2016;30:524-32.
3. Moore-Dotson JM, Beckman JJ, Mazade RE, et al . Early Retinal Neuronal Dysfunction in Diabetic Mice: Reduced Light-Evoked Inhibition Increases Rod Pathway Signaling. Invest Ophthalmol Vis Sci 2016;57:1418-30.

Poster #85
Thursday, 9:55 am – 10:55 am

Characteristics of Optical Coherence Tomography Angiography (OCT-A) in Pediatric Renal Disease Population

Aparna Ramasubramanian, MD; Sidharth Puri, MD

University of Louisville Department of Ophthalmology
Louisville, KY

Introduction: To examine the retinal vascular changes using optical coherence tomography angiography (OCT-A) in pediatric patients with renal disease

Methods: This was a prospective, cross-sectional study that included eight eyes from 4 subjects with renal disease (non-diabetic subjects with chronic kidney disease, dialysis, or s/p transplant) and fourteen eyes from 7 age-matched healthy control subjects. All subjects underwent a comprehensive dilated eye exam and acquisition of OCT-A 3x3mm enface scans using Zeiss Cirrus Angioplex. The 3x3mm enface OCT-A scans were used to analyze the foveal avascular zone (FAZ) area and parafoveal capillary density between renal subjects and control subjects.

Results: The average BCVA in the renal group was 0.1 LogMAR and 0.0 LogMAR in the control group. The renal subjects' mean superficial FAZ (renal: 0.19 ± 0.05 vs control: 0.14 ± 0.03; p=0.01), and deep FAZ (renal: 0.35 ± 0.06 vs control: 0.24 ± 0.02; p=0.02) were significantly larger than control FAZ. The parafoveal capillary density was significantly less in the superficial (renal: 39.3 ± 5.06 vs control: 45.4 ± 5.43; p= 0.02) than the deep (renal: 20.51 ± 8.43 vs control: 22.7 ± 5.53; p=0.31) capillary plexi.

Discussion: Our study suggests that renal disease may result in subtle vascular changes as evident on OCT-A, specifically in superficial and deep FAZ and superficial parafoveal capillary density. While visual acuity may be preserved in these patients, these changes on OCT-A may warrant long-term follow-up to ensure preservation of vision.

Conclusion: Our findings suggest that OCT-A may serve an adjunct role in monitoring systemic renal disease.

References: 1. Bao S, Huang W, Liang Y et al. Retinal Vessel Diameter and Chronic Kidney Disease in Rural China A Cross-Sectional Study . Medicine (Baltimore). 2015 Dec; 94(49)
2. Emre, S., Öztürkeri, A., Ulusoy, M. O., & Cankurtaran, C. (2016). Evaluation of the acute effect of haemodialysis on retina and optic nerve with optical coherence tomography. Saudi Journal of Ophthalmology, 30(4), 233–235.
3. Chang, I. B., Lee, J. H., & Kim, J. S. (2017). CHANGES IN CHOROIDAL THICKNESS IN AND OUTSIDE THE MACULA AFTER HEMODIALYSIS IN PATIENTS WITH END-STAGE RENAL DISEASE. Retina (Philadelphia, Pa.), 37(5), 896–905.

Poster #86
Thursday, 9:55 am – 10:55 am

Incidence of Mitogen-Activated Protein Kinase Inhibitor-Associated Retinopathy in Pediatric Pateints

Lauren M. Imbornoni, MD; Scott Oliver, MD; Jennifer Jung, MD; Robert Enzenauer, MD; Jasleen K. Singh, MD; Rebecca Sands Braverman, MD; Nicholas Foreman, MD; Molly Hemenway, NP; Emily McCourt, MD

University of Colorado Denver/Children's Hospital Colorado
Aurora, Colorado

Introduction: Mitogen-activated protein kinase (MEK) inhibition has been effective in clinical trials pediatric low grade gliomas and plexiform neurobibromas. A class effect of MEK inhibitors is MEK inhibitor-associated retinopathy (MEKAR), a subretinal fluid accumulation that is seen in up to 90% of adults. Only two cases of MEKAR have been reported in children. We obtained optical coherence tomography (OCT) macula images of pediatric patients on MEK inhibitors to evaluate for the presence of MEKAR.

Methods: Prospectively followed pediatric patients with OCT macula while on treatment with trametinib.

Results: Seventeen patients, ages 3 to 18, were included. Ten had neurofibromatosis 1 related tumors. Four had non-neurofibromatosis gliomas and two had other intracranial tumors. Each patient had between 1 and 4 OCT scans performed between 1 day and 921 days of treatment. One patient developed MEKAR in both eyes, identified on OCT 4.5 months after starting trametinib for a thalamic glioma. The patient was asymptomatic, but had two lines of visual acuity loss in one eye. Due to excellent tumor response, it was decided to continue the trametinib. The MEKAR persisted on repeat OCT one month later with stable visual acuity.

Discussion: The incidence of MEKAR in our cohort was one out of seventeen patients (5.9%). MEKAR may be asymptomatic in children. If MEKAR develops, the risks of stopping treatment must be weighted against the risks of retinopathy.

Conclusion: Further research is needed to determine screening protocols for MEKAR and management of MEKAR in children.

References: Francis JH, Habib LA, Abramson DH, et al. Clinical and morphologic characteristics of MEK inhibitor-associated retinopathy. Ophthalmology. 2017;124:1788-1798.
Avery RA, Trimboll-Heldler C, Kilburn LB. Separation of outer retinal layers secondary to selumetinib. J AAPOS. 2016;20(3):268-271.
Stjepanovic N, Velazquez-Martin JP, Bedard PL. Ocular toxicities of MEK inhibitors and other targeted therapies. Annals of Oncology. 2016;27:998-1005.

Poster #87
Thursday, 9:55 am – 10:55 am

Outcomes of Subretinal Delivery of Voretigene Neparvovec for Leber Congenital Amaurosis: The CHLA Experience

Aaron Nagiel, MD, PhD; Thomas C. Lee, MD

Children's Hospital Los Angeles
Los Angeles, CA

Introduction: Voretigene neparvovec is an AAV2-based gene replacement therapy for RPE65-mediated retinal dystrophies recently approved by the Food and Drug Administration based on positive Phase 3 trial results.1 Visual and anatomic outcomes of patients treated with voretigene neparvovec outside of the clinical trials have not been reported.

Methods: Retrospective case series of Leber congenital amaurosis (LCA) patients treated with subretinal voretigene neparvovec at Children's Hospital Los Angeles.

Results: As of September 2018, three LCA patients ages 44, 10, and 5 years of age have undergone bilateral gene therapy surgery with voretigene neparvovec. Best-corrected Snellen visual acuities were hand motions OU (44-year-old), 20/100 OD and 20/80 OS (10-year-old), and 20/150 OU (5-year-old). All three patients had significantly diminished or absent visual function in dim lighting. Intraoperative optical coherence tomography (OCT) provided real-time feedback during the subretinal delivery. Following treatment all three patients had significantly improved visual function in the dark, especially the pediatric patients. Visual acuities did not appear to improve significantly. By the end of 2018, 6 additional pediatric patients including a 3-year-old and one adult patient are scheduled to be treated at our center.

Discussion: Treatment with voretigene neparvovec results in significant subjective improvements in visual function especially in dim lighting conditions. Long-term data on visual outcomes and surgical complications in the post-approval period may guide the design of future gene therapy trials.

Conclusion: Voretigene neparvovec is an exciting first-in-class treatment for a previously untreatable retinal degeneration.

References: 1. Russell S, Bennett J, Wellman JA, Chung DC, Yu Z-F, Tillman A, et al. Efficacy and safety of voretigene neparvovec (AAV2-hRPE65v2) in patients with RPE65-mediated inherited retinal dystrophy: a randomised, controlled, open-label, phase 3 trial. Lancet. 2017 Aug 26;390(10097):849-60.

Poster #88
Thursday, 9:55 am – 10:55 am

Clinical Profile and Treatment Outcomes Following Laser Monotherapy and Combination Therapy with Bevacizumab in Paediatric Coats' Disease (PCD)

Vinod Sharma, MBBS, MS, DNB, FRCSEd, FRCOphth; Bhamy Hariprasad Shenoy, MBBS, S FICO, FRCOphth; Jane Ashworth, BMCh, FRCOphth, PhD; William Newman, MB,BS,FRCS (Glasg), FRCOphth, LL.M (Medical Law); Susmito Biswas, BSc Hons, MBBS, FRCOphth

Manchester Royal Eye Hospital
Manchester, United Kingdom

Introduction: Paediatric Coats Disease profile and treatment outcomes with anti-VEGF haven't been studied well. Hence, aim of this study was to describe clinical profile and treatment outcomes following laser monotherapy and combined therapy in management of PCD.

Methods: Retrospective interventional case series involving patients with Coats' disease and age at presentation <15 years. Patients underwent fluorescein angiography guided repetitive green diode laser ablation or combination treatment with laser and intravitreal bevacizumab. Main outcome measures were visual acuity (VA), anatomic success and globe salvage rate at last follow-up.

Results: Thirty eyes of 28 patients were included in the study. Mean age at presentation was 6.88±3.7 years. Mean duration of follow-up was 61.3±30.2 months (Range 12-124 months). At presentation, 9 eyes were stage 2A, 15 were stage 2B, 3 were stage 3B and 1 eye was stage 4. Laser treatment was performed in 11 eyes and 17 eyes underwent combined therapy. Over the follow-up period, VA improved in 39%, stabilised in 43% and worsened in 18% eyes. All eyes had attached retina without any treatment related complications and no eye was phthisical or enucleated. Globe salvage rate was 100%.

Discussion: Our study demonstrates wide variability in presentation of PCD. Earlier age, lower stage and good VA at presentation were associated with good anatomic and functional outcomes. The study benefits from being large series of PCD with longest mean follow-up.

Conclusion: PCD varies greatly in clinical presentation and severity. Early detection of the disease and prompt treatment results in good functional and anatomic outcomes and globe salvage rates.

References: 1.Shields JA, Shields CL, Honavar SG, et al. Classification and management of Coats disease: the 2000 Proctor Lecture. Am J Ophthalmol. 2001;131(5):572-583
2.Shields JA, Shields CL, Honavar SG, Demirci H. Clinical variations and complications of Coats disease in 150 cases: the 2000 Sanford Gifford Memorial Lecture. Am J Ophthalmol. 2001;131(5):561-571
3.Ray R, Baranano DE, Hubbard GB. Treatment of Coats' disease with intravitreal bevacizumab. Br J Ophthalmol. 2013;97(3):272-277

Poster #89
Thursday, 9:55 am – 10:55 am

Ocular Injuries in Pediatric Abusive Head Trauma

Rebecca S. Weiss, MD; Sabine Khan, MD; Afshin Parsikia, MD, MPH; Joyce N. Mbekeani, MD, FRCS, FRCOphth

Introduction: Pediatric abusive head trauma (AHT) is defined as injury to the skull or intracranial contents from intentional blunt force or violent shaking of children ≤5 years old. We sought to evaluate ocular injuries in children admitted with AHT.

Methods: Children ages ≤5 years admitted with AHT were identified from the 2008-2014 National Trauma Data Bank using ICD-9CM codes. Tabulated data was analyzed using student's t, chi-squared and regression analysis with SPSS software. Significance was set at $p<0.05$.

Results: 18,562 (5.3%) of 351,732 children admitted after assault had AHT. 2,550 (13.7%) had associated ocular injuries. 58.7% were female. The mean (SD) age was 6 (1) months. 85.7% were ≤1 year old. Common head injuries were: subdural hemorrhage (SDH) (72.8%), subarachnoid hemorrhage (22.9%), and cranial vault fractures (20.9%). Common ocular injuries included: contusion of eye/adnexa (73.7%), retinal edema (59.3%), ruptured globe (8.5%), superficial injury (7.1%), retinal hemorrhage (5.3%) and optic neuropathy (4.9%). Children ≤1 year had the greatest odds of retinal hemorrhage (OR=2.44, 95% CI=1.23-4.84; p=0.008), retinal edema (OR=1.26, 95% CI=1.01-1.57; p=0.043), and SDH (OR=1.55, 95% CI=1.22-1.96; p<0.001). For all ages, SDH occurred more frequently with retinal edema compared to other ocular injuries (OR=2.25; 95% CI=1.88-2.68; p<0.001). 42.8% of children had an injury severity score of >24 (very severe), and the mortality rate was 19.2%.

Discussion: The most common head injury associated with ocular injury was SDH, which often occurred with retinal edema. Both frequently occurred in the youngest age group.

Conclusion: Types of ocular injury varied with age and type of AHT.

References: 1. National Center for Injury Prevention and Control of the Centers for Disease Control and Prevention, Pediatric abusive head trauma: recommended definitions for public health surveillance and research. April 2012. https://www.cdc.gov/violenceprevention/pdf/PedHeadTrauma-a.pdf. Accessed September 5, 2018.
2. P Watts. Child maltreatment guideline working party of the Royal College of Ophthalmologists UK. Abusive head trauma and the eye in infancy. Eye (Lond) 2013 Oct; 27(10):1227-1229.
3. Morgan LA, Fouzdar Jain S, Svec A, et al. Clinical comparison of ocular and systemic findings in diagnosed cases of abusive and non-abusive head trauma. Clinical Ophthalmology (Auckland, NZ). 2018; 12:1505-1510.

Poster #90
Thursday, 9:55 am – 10:55 am

Rationale, Design, and Subject Characteristics of the Postnatal Growth and Retinopathy of Prematurity Validation Study (G-ROP-2)

Lauren A. Tomlinson; Gui-shuang Ying; Yinxi Yu; Gil Binenbaum; on behalf of the G-ROP Study Group

The Children's Hospital of Philadelphia
Philadelphia, PA

Introduction: The Postnatal Growth and ROP Study (G-ROP-1) retrospectively studied 7,483 premature infants to develop a postnatal-weight-gain ROP predictive model with high statistical power. Modified screening criteria with 100% sensitivity for type 1 ROP were successfully developed, but they required validation before clinical use. Here we describe the design of the prospective G-ROP validation study (G-ROP-2) and compare infant and ROP characteristics between the two study cohorts.

Methods: The G-ROP-2 Validation Study enrolled consecutive infants undergoing ROP examinations at 41 hospitals in the U.S. and Canada from 2015-2017, including 25 G-ROP-1 hospitals for temporal validation and 16 new hospitals for external validation. Certified coordinators submitted data to a secure, web-based database. Data included ROP examination findings and treatments, daily weight measurements, daily oxygen supplementation, medical events, and demographics. Data quality was monitored with system validation rules, data audits, and discrepancy algorithms.

Results: Of 4,388 screened infants, 3,980 had a known ROP outcome and were considered evaluable (median birth weight 1072g(350-2190), gestational age 28 weeks(22-38)). 1,642 (41.3%) infants developed ROP, 219(5.5%) type-1, 264(6.6%) type-2. 256(6.4%) were treated. Demographics and ROP rates were similar to G-ROP-1 (43.1% ROP, 6.1% type-1, 6.3% type-2).

Discussion: Despite potential neonatal care changes, such as oxygen-saturation targets, ROP rates and severity remained similar between 2006-12 and 2015-17.

Conclusion: The G-ROP studies represent two large, diverse cohorts of infants screened for ROP over more than a decade. The G-ROP-2 validation dataset, and the combined studies cohorts provide high statistical power for evaluating growth-based models that might improve the efficiency of ROP screening.

References: 1. Binenbaum G, Tomlinson L, on behalf of the G-ROP Study Group: Postnatal Growth and Retinopathy of Prematurity Study: Rationale, Design, and Subject Characteristics. Ophthalm Epidem 24(1): 36-47, Feb 2017.
2. Binenbaum G, Bell EF, Donohue P, Quinn G, Shaffer J, Tomlinson LA, Ying GS; on behalf of the G-ROP Study Group. Development of Modified Screening Criteria for Retinopathy of Prematurity: Primary Results From the Postnatal Growth and Retinopathy of Prematurity Study. JAMA Ophthalmol. 2018 Sep 1;136(9):1034-1040.

Poster #91
Thursday, 9:55 am – 10:55 am

Comparing Left and Right Eyes in Retinopathy of Prematurity with and without Patent Ductus Arteriosus

Aaron M. Skelton, MD; Mary O'Hara, MD

UC Davis Eye Center
Sacramento, CA

Introduction: Retinopathy of Prematurity (ROP) severity and degree of myopia was compared in right vs. left eyes. The presence of a Patent Ductus Arteriosus (PDA) was also investigated to see if it increased the likelihood of asymmetric disease or myopia.

Methods: All patients with ROP in a University practice seen between 01/2008 and 01/2017 were evaluated via retrospective chart review. Inclusion criteria were documented zone/stage of ROP, documented cycloplegic refraction, and absence of other ocular comorbidities. Severity of ROP was divided into 3 groups: A) Retinal detachment + Type 1 ROP, B) Type 2 ROP, C) ROP less severe than Type 2 ROP. The presence or absence of a PDA was recorded.

Results: Of 251 total patients, 238 had symmetric ROP, 5 had worse disease OD and 8 had worse disease OS ($p = 0.392$). Degree of myopia was symmetric (OD +1.044 vs. OS +0.978, $p=0.186$).
In patients with PDAs (n=101), 93 had symmetric disease, 4 had worse disease OD, 4 had worse disease OS ($p=0.261$). Degree of myopia was symmetric (OD +0.858 vs. OS +0.814, $p=0.351$).

Discussion: There is not a statistically significant difference in severity of ROP or myopia when comparing right and left eyes. Although there may be differences in oxygenation in the right and left carotid circulations in the context of a PDA, the presence of a PDA did not have an effect on the symmetry of ROP or myopia.

Conclusion: Both eyes are at equal risk of ROP and secondary myopia, even in the context of a PDA

References: Shah PK, Prabhu V, Karandikar SS, Ranjan R, Narendran V, Kalpana N. Retinopathy of prematurity: Past, present and future. World Journal of Clinical Pediatrics. 2016;5(1):35-46. doi:10.5409/wjcp.v5.i1.35.
Yoon HY, Baek WK, Moon YS. Influence of Patent Ductus Arteriosus and Its Treatment on Retinopathy of Prematurity. J Korean Ophthalmol Soc. 2013 May;54(5):728-735. Korean.
Quinn GE, Dobson V, Davitt BV, Wallace DK, Hardy RJ, Tung B, Lai D, Good WV; Progresssion of myopia and high myopia in the Early Treatment for Retinopathy of Prematurity study: findings at 4 to 6 years of age. J AAPOS. 2013 Apr;17(2):124-8. doi: 10.1016/j.jaapos.2012.10.025.

Poster #92
Thursday, 9:55 am – 10:55 am

Characteristics of High Risk Infants That Do Not Develop Retinopathy of Prematurity

Alyssa Spiller; Pamela Donohue; Yinxi Yu; Gui-shuang Ying; Lauren A. Tomlinson; Gil Binenbaum;
on behalf of the G-ROP Study Group

The Children's Hospital of Philadelphia
Philadelphia, PA

Introduction: The great majority of very early gestational-age(GA) infants develop retinopathy of prematurity (ROP). We identified characteristics that distinguish those relatively few extremely premature infants that do not develop ROP.

Methods: Secondary analysis of G-ROP-1 Study data, a retrospective study of infants undergoing ROP examinations at 29 North-American hospitals. Infants with GA=22-25 weeks and birth-weight (BW)</=900g were included. Demographic, growth, medical, surgical, and nutritional characteristics, in the first six postnatal weeks, were evaluated as risk factors for not developing ROP.

Results: Of 1378 extremely premature infants, 128(9.2%) did not develop ROP. The proportion increased with GA: 2.5%(GA=22-23), 5.1%(GA=24), 15.6%(GA=25). In multivariable analysis, each of the following six factors independently decreased the chance of not developing ROP (i.e., increased risk of having ROP): caucasian-race; delivery-room-intubation; serum platelet level<100,000, 75-100% of days on supplemental-oxygen, sepsis, and surgery. The chance of not developing ROP decreased with increasing number of risk factors: 27%, zero factors present; 9%, 3 risk factors present; and 0%, 6 factors present ($p<0.001$). Weight gain was not independently associated with not developing or developing ROP.

Discussion: For extremely premature infants, postnatal weight gain does not carry the same prognostic information for ROP that it does for older GA infants.

Conclusion: Risk of not developing ROP increases with increasing GA, even among the narrow range of gestational ages 22-25 weeks. In addition, infants have an increasingly greater chance of not having ROP, the fewer of the six identified risk factors are present during the first six weeks of postnatal life.

References:

Poster #93
Thursday, 9:55 am – 10:55 am

Music Therapy May Decrease Apnea Associated with Retinopathy of Prematurity Exams

Susan M. Bakouros; John Evered; Kristin Rarey

PeaceHealth Southwest Medical Center
Vancouver, WA

Introduction: Many premature newborns need to be screened for retinopathy of prematurity (ROP). During and after ROP screening exams, newborns are at high risk for apnea, bradycardia and desaturation (ABD). NICU music therapy (NICU MT), has been shown to improve physiologic stability, including heart rate and oxygen saturations.

Methods: A NICU music therapist provided procedural support during ROP screening exams (n = 46) done with digital retinal imaging (DRI), to determine if NICU MT might help decrease screening-related ABD.

Results: For all 46 DRI exams, the mean number of ABD events in the 24 hour period before the DRI exams was 0.54, and in the 24 hour period following the exam, the mean number of ABD events was 0.41 ($p = 0.35$, 95% confidence interval = -0.15-0.41). Following ROP screening with NICU-MT, no infants had escalation of respiratory support, serious infection, or feeding interruption.

Discussion: This is the first study to evaluate the ability of NICU MT to decrease procedure-related ABD events in premature infants. It is also the first study of NICU MT during ROP screening. We found no increase, and a trend towards decrease, in post-procedure ABD when NICU MT was used during the ROP exam.

Conclusion: Our findings suggest that NICU MT during ROP screening exams using DRI is safe and may be associated with a decrease in post-procedure ABD events, consistent with other findings in the literature showing that NICU MT may decrease pain and improve physiologic stability in preterm infants.

References: Kim SJ, Port AD, Swan R, Campbell JP, Chan RVP, Chiang MF. Retinopathy of prematurity: a review of risk factors and their clinical significance. Surv Ophthalmol. 2018.
Loewy J, Stewart K, Dassler AM, Telsey A, Homel P. The effects of music therapy on vital signs, feeding, and sleep in premature infants. Pediatrics. 2013;131(5):902-918.
Samra HA, McGrath JM. Pain management during retinopathy of prematurity eye examinations: a systematic review. Adv Neonatal Care. 2009;9(3):99-110.

Poster #94
Thursday, 9:55 am – 10:55 am

Socioeconomics of Retinopathy of Prematurity Screening and Treatment in the United States

Shagun Bhatia[1], Lance Siegel[2], Rebecca Braverman[3], Robert Enzenauer[3], David Granet[1], Shira L. Robbins[1]

[1]Ratner Children's Eye Center of the Shiley Eye Institute, University of California San Diego
[2]Children's Eye institute, Upland, CA
[3]University of Colorado School of Medicine, Department of Ophthalmology

Introduction: Retinopathy of prematurity (ROP) screening, an integral part of pediatric ophthalmology, is time consuming and resource intensive. The purpose of this study is to evaluate the socioeconomics of ROP screening and treatment amongst pediatric ophthalmologists in the United States (US).

Methods: An online survey was distributed to pediatric ophthalmologists in the US. Survey results were compiled and responses were de-identified and analyzed.

Results: A total of 97 responses were collected. Almost half of respondents worked in private practice settings. Over 75% of respondents had a formal contract to perform ROP care, but only 23% had the assistance of an attorney to negotiate their contract. Just over half of respondents felt adequately compensated for their services. The amount of time spent performing screenings and coordinating care varied greatly with about half of respondents spending more than 2 hours per week of administrative time coordinating ROP services. Most respondents enlisted both the hospital and their office staff to coordinate follow-up outpatient care.

Discussion: When compared to data from previous studies, it appears that more pediatric ophthalmologists are obtaining contracts for their services[1-2]. Despite a larger percentage of pediatric ophthalmologists having contracts, the long term risks and liability remain. Many expend large amounts of time tracking patients and coordinating outpatient care.

Conclusion: Our survey highlights that despite increased contractual agreements, concerns for under-compensation, time usage and large liability persist. This calls into question the sustainability of current models for providing ROP services for this vision threatening disease in a most vulnerable population.

References: 1) Braverman RS, Enzenauer RW. Socioeconomics of retinopathy of prematurity in-hospital care. Arch Ophthalmol. 2010 Aug;128(8):1055-8.
2) Braverman RS, Enzenauer RW. Socioeconomics of retinopathy of prematurity care in the United States. Am Orthopt J. 2013;63:92-6.

Poster #95
Thursday, 9:55 am – 10:55 am

Impact of Higher Target Oxygen Saturation Levels on Postnatal Weight Gain as a Predictor for Retinopathy of Prematurity

Carolyn Wu, MD; Deborah K. VanderVeen, MD

Boston Children's Hospital
Boston, MA

Introduction: The weight, insulin-like growth factor, neonatal, retinopathy of prematurity algorithm (WINROP) predicts severe ROP based on postnatal weight gain and has been validated in several studies. Oxygen supplementation is a well-known risk factor for ROP. In our NICU, target oxygen saturation levels were increased in 2014 which may affect the validity of WINROP.[1]

Methods: WINROP's ability to identify severe ROP in infants <32 weeks gestational age born January 1, 2014 - December 31, 2017 was analyzed and compared to a cohort of infants from the same institution born October 21, 2005 - December 12, 2008.[2] Severe ROP included ROP requiring treatment, type 1 ROP, and type 2 ROP. Target oxygen saturation levels were 90 - 95% in this study versus 85 - 93% in the earlier study.

Results: 352 infants were included. Thirty-three infants (9.4%) developed severe ROP with 20 (5.7%) requiring treatment. All infants with severe ROP were identified with the WINROP alarm. In the earlier cohort of 318 infants, 28 infants (8.9%) developed severe ROP with 13 (4.1%) requiring treatment.[2] With the higher target oxygen saturation levels, there was an increase in zone 1 ROP in infants with severe ROP (33.3% vs. 17.8%, respectively); though this did not reach statistical significance.

Discussion: Higher target oxygen saturation levels have resulted in a slight increase in severe ROP and ROP requiring treatment. The incidence of zone 1 ROP has almost doubled.

Conclusion: WINROP identified all infants at risk for severe ROP even with increased target oxygen saturation levels.

References:

[1]Lundgren P, Härd AL, Wilde A, Löfqvist C, Smith LEH, Hellström A. Implementing higher oxygen saturation targets reduced the impact of poor weight gain as a predictor for retinopathy of prematurity. Acta Paediatr 2018;107:767-773.
[2]Wu C, VanderVeen DK, Hellstörm A, Löfqvist C, Smith LEH. Longitudinal postnatal weight measurements for the prediction of retinopathy of prematurity. Arch Ophthal 2010; 128: 443 – 447

Poster #96
Thursday, 9:55 am – 10:55 am

Pattern of Retinopathy of Prematurity Cases from Differing Oxygen Level Changes in a Tertiary Referral Centre in Malaysia over Two Different Periods - A Middle-Income Country

May May Choo, MBBS, FRCS; John Grigg, MD, FRANZCO; Nurliza Khaliddin, MBBS, FRCS;
Frank Martin, AM, MBBS, FRANZCO, FRACS

University of Malaya and University of Sydney
Malaysia / Sydney

Introduction: To study trend in retinopathy of premature(ROP) in a tertiary-referral centre in Malaysia during a 16-year period (2002-2017). The aim was to detect any difference in the type of ROP based on different oxygen limits practised by neonatologists in the hospital.

Methods: Data from infants who underwent ROP screening were retrospectively analysed. The dataset was divided into two cohorts: Epoch1(2002-2009) and Epoch2(2010 - 2017). This enabled the comparison of birth parameter and incidence of ROP and risk factors

Results: Between 1 Jan 2002 to 31 Dec 2017, 651 infants completed acute ROP screening. Epoch 1(2002-2009), n=307 and Epoch 2(2010-2017), n=344. During Epoch1, oxygen restriction between 89-94% were strictly enforced. In Epoch2, a higher level of oxygen was introduced to improve survival, oxygen being kept 89%-99%. The incidence of ROP for the two epochs were 30.6% and 29.4% respectively (p=0.73). The cases that required treatment were reduced significantly, being 14.3% vs 5.9% (p=0.0005). Severe cases were similar in number.

Discussion: High oxygen exposure is the main cause of ROP-associated blindness. However, STOP-ROP found benefits in increased oxygen (up to 99%) for ROP cases with plus. Furthermore HOPE-ROP cases did better compared to STOP-ROP cases in ROP outcome. This was also seen in this cohort. The number of cases that required treatment were reduced substantially. BOOST-II trial results reported increase in severe ROP cases which was not evident in this cohort.

Conclusion: Incidence of ROP was similar but the number of cases requiring treatment was reduced 3-fold with higher oxygen exposure.

References: 1. The STOP-ROP Multicenter Study Group. Supplemental therapeutic oxygen for prethreshold retinopathy of prematurity (STOP-ROP), a randomized, controlled trial. I: Primary outcomes. Pediatrics.2000 Feb;105(2):295-310.
2. McGregor ML, Bremer DL, Cole C, McClead RE, Phelps DL, Fellows RR, Oden N (HOPE-ROP Multicenter Group). Retinopathy of Prematurity outcome in infants with prethreshold retinopathy of prematurity and oxygen saturation >94% in room air: The high oxygen percentage in retinopathy of prematurity study. Pediatrics; Sept 2002 110(3): doi:10.1542/peds.110.3.540
3. The BOOST II United Kingdom, Australia, and New Zealand Collaborative Groups. Oxygen saturation and outcomes in preterm infants. N Engl J Med 2013;368:2094-2104.DOI:10.1056/NEJMoa1302298

Poster #97
Thursday, 9:55 am – 10:55 am

Dome-Shaped Macula in Infants Screened for Retinopathy of Prematurity as seen by Handheld Spectral-Domain Optical Coherence Tomography

Alex T. Legocki, MD; Yasman Moshiri, BS; Emily M. Zepeda, MD; Thomas B. Gillette, MD; Ayesha Shariff, MD; Laura H. Grant, MD; Leona Ding, MS; Kristina Tarczy-Hornoch, MD, DPhil; Michelle T. Cabrera, MD

University of Washington and Seattle Children's Hospital
Seattle, Washington

Introduction: Dome-shaped macula was originally defined as a convexity of the macula in the setting of a posterior staphyloma, and is associated with high myopia and vision loss in adults. This morphology has never been described in the pediatric population.

Methods: This is a prospective, observational study of premature infants screened for retinopathy of prematurity (ROP) between June 2015 and June 2017 with 9-month follow up. Handheld spectral domain optical coherence tomography (SD-OCT) imaging was performed in addition to indirect ophthalmoscopy. Two trained graders identified retinal convexity on two sides of the fovea. A third trained grader mediated disagreements.

Results: This study included 39 infants (49% male, mean gestational age 28.0 weeks, mean birth weight 963.3 grams). Agreement between OCT graders was 95.8% (kappa=0.94). In total, 24/39 (62%) had dome-shaped macula in at least one eye (13 both eyes, 5 right eye only, and 6 left eye only). Comparing 18/39 (46.2%) right eyes with dome-shaped macula to those without, a lower birth weight (860g vs. 1052g; P=0.03) and a borderline lower gestational age (P=0.09) and best-corrected visual acuity at 9 months (P=0.07) were seen, as well as a borderline association with the presence of ROP (P=0.06). No associations with sex, race, OCT-determined cystoid macular edema, epiretinal membrane, vitreous bands, punctate opacities, ROP severity, or cycloplegic spherical equivalence at 9 months were seen.

Discussion: Future investigations are necessary to demonstrate long-term impact of dome-shaped macula on vision and emmetropization.

Conclusion: Dome-shaped macula is an incidental handheld SD-OCT finding with high prevalence among premature infants, especially those with lower birth weight.

References: 1. Hellstrom, A., L.E. Smith, and O. Dammann, Retinopathy of prematurity. Lancet, 2013. 382(9902): p. 1445-57.
2. Gaucher, D., A. Erginay, A. Lecleire-Collet, B. Haouchine, M. Puech, S.Y. Cohen, et al., Dome-shaped macula in eyes with myopic posterior staphyloma. Am J Ophthalmol, 2008. 145(5): p. 909-14.
3. Imamura, Y., T. Iida, I. Maruko, S.A. Zweifel, and R.F. Spaide, Enhanced depth imaging optical coherence tomography of the sclera in dome-shaped macula. Am J Ophthalmol, 2011. 151(2): p. 297-302.

Poster #98
Thursday, 9:55 am – 10:55 am

Longitudinal Analysis of Retinal Vascular Characteristics in Narrow-Field Retinal Images of Infants Being Screened for Retinopathy of Prematurity: A Quantitative Approach

Jagger C. Koerner, MD; Gloria J. Hong, BA; Marguerite C. Weinert, MD; Sharon F. Freedman, MD; David K. Wallace, MD; Wayne J. Riggins, MD; Keith J. Gallaher, MD; Grace S. Prakalapakorn, MD, MPH

Duke Eye Center
2351 Erwin Rd, Durham, NC 27705

Introduction: While the decision to treat retinopathy of prematurity (ROP) usually depends on the presence of plus disease, its diagnosis is subjective even among experts.1 ROPtool, a semi-automated computer program that objectively measures vascular characteristics in retinal images, can accurately identify plus disease in narrow-field images.2 The purpose of this study is to use ROPtool to analyze narrow-field retinal images to quantitatively describe longitudinal changes in retinal vascular characteristics in infants screened for ROP.

Methods: In this retrospective study, we used ROPtool to analyze 2 blood vessels per quadrant in sequential narrow-field retinal images of right eyes of infants screened and imaged for ROP. We compared the following ROPtool indices over time (weeks) between infants treated versus not treated for ROP: tortuosity index (TI), combination dilation/tortuosity indices: sum of adjusted indices (SAI) and tortuosity-weighted plus (TWP). Analyses were performed using the highest blood vessel and quadrant, and overall eye values.

Results: Using ROPtool, we analyzed images from 330 imaging sessions (81 infants; 6(7.4%) treated; average imaging sessions/infant=4.1; 300(90.9%) had 3-4 analyzable quadrants). TI, SAI, and TWP values were higher for treated versus untreated infants at all three analysis levels($p<0.05$ for PMA=32-35 and 37 weeks). At the eye-level, SAI values were higher for treated versus untreated babies for PMA=31-37 weeks($p<0.05$).

Discussion: ROPtool analysis of longitudinally-acquired narrow-field images showed higher tortuosity and combined tortuosity/dilation indices for infants ultimately requiring ROP treatment.

Conclusion: Objective analysis of posterior pole vascular characteristics over time may help identify infants whose ROP will ultimately reach treatment severity.

References: 1Chiang MF, Jiang L, Gelman R, Du YE, Flynn JT. Interexpert agreement of plus disease diagnosis in retinopathy of prematurity. Arch Ophthalmol. 2007 Jul;125(7):875-80.

Poster #99
Thursday, 9:55 am – 10:55 am

Progression from Pre-Plus Disease to Plus Disease in the G-ROP Study

Ryan S. McGuire; Gui-shuang Ying; Gil Binenbaum; on behalf of the G-ROP Study Group

The Children's Hospital of Philadelphia
Philadelphia, PA

Introduction: Limited data are available describing progression of pre-plus changes to plus disease in retinopathy of prematurity (ROP). We sought to determine the rate and characteristics of eyes that progress from pre-plus to plus.

Methods: Secondary analysis of retrospective G-ROP-1 data from infants undergoing ROP examinations at 29 North-American hospitals between 2006-2012. Outcomes included proportion of eyes progressing from pre-plus to plus, based upon clinical assessment by examining ophthalmologists; days between pre-plus and plus diagnoses; and ROP stage at time of plus diagnosis. Stratified analyses by stage/zone and postmenstrual-age (PMA) at first pre-plus diagnosis were performed.

Results: 946 eyes of 512 infants were diagnosed with pre-plus. 286(30.2%) eyes progressed to plus disease, or 338(35.7%) assuming progression for eyes treated at pre-plus whose fellow eye had plus. Progression rates by stage/zone were 21% St-0; 33% St-1/Zn-I; 43% St-2/Zn-I; 28% St-1/Zn-II; 32% St-2/Zn-II; 29% St-3/Zn-II. Progression rates by PMA at first pre-plus were 5.7% PMA<33; 31.7% PMA 33-40; 34% PMA>40. Mean days to progression were 12-14 days for St-1/Zn-II, St-2/Zn-I, and St-2/Zn-II; 125/159(79%) of these eyes had progessed to stage 3 at time of plus diagnosis. Mean days to progression for St-3/Zn-II was 7.3 days (range 1-35).

Discussion: Although pre-plus and plus diagnoses were not based upon photographic assessment, these data represent the real-life determinations being used by clinicians to make treatment decisions.

Conclusion: Approximately one-third of eyes with pre-plus vascular changes progress to plus disease. The large majority of these eyes will develop stage 3 ROP by the time plus disease develops.

References: 1. Binenbaum G, Tomlinson L, on behalf of the G-ROP Study Group: Postnatal Growth and Retinopathy of Prematurity Study: Rationale, Design, and Subject Characteristics. Ophthalm Epidem 24(1): 36-47, Feb 2017.

Poster #100
Thursday, 9:55 am – 10:55 am

Treatment of Retinopathy of Prematurity with Intravitreal Bevacizumab in Infants Weighing 500 Grams or Less at Birth

Elise L. Timtim; Colleen Peyton, PT, DPT, PCS; Michael Blair, MD; Sarah M. Hilkert Rodriguez, MD, MPH

The University of Chicago
Chicago, IL

Introduction: The ETROP Study evaluated ocular findings among infants under 500g who received laser. The purpose of our study was to describe ocular and medical findings among infants with birth weights <500g with type 1 ROP who instead received treatment with intravitreal bevacizumab (IVB) after the publication of BEAT-ROP.

Methods: Retrospective chart reviews identified 30 infants with birth weights <500g. Primary ocular outcome measures were structural and refractive outcomes. Developmental outcomes included cerebral palsy (CP) and other developmental delays.

Results: Twenty-three infants (77%) survived to the initial ROP exam, with majority female (71%) and black (71%) infants. Overall, 9 (39%) developed Type 1 ROP, of which 2 received laser before BEAT-ROP and 7 received primary IVB. Delayed laser treatment completion was recommended for all primary IVB patients and completed by 6/7. The remaining one patient agreed to q3month dilated exams. There were no retinal detachments or unfavorable structural outcomes. Mean spherical equivalent was +0.5 diopters (range -0.5 to +2.25). Two patients developed strabismus, and no patient had nystagmus. The rate of CP among infants who received IVB compared to no treatment or laser was not significantly different (1/7 vs. 3/11, p=0.485). Abnormal general movements, a predictor of developmental delay, were also similar (2/6 vs. 3/7, p=0.587).

Discussion: Compared to the ETROP cohort, fewer infants in this study developed ROP requiring treatment (39% versus 54%), which may be related to the high proportion of female and black infants. All infants demonstrated favorable ocular responses to IVB. There were no obvious adverse effects of IVB on neurodevelopmental outcomes.

Conclusion: IVB is a reasonable treatment option for extremely small infants.

References: 1.) Wheeler DT, Dobson V, Chiang MF, et al. Retinopathy of Prematurity in Infants Weighing Less Than 500 Grams at Birth Enrolled in the Early Treatment for Retinopathy of Prematurity Study. Ophthalmology. 2011;118(6):1145-1151. doi.org/10.1016/j.ophtha.2010.09.031.
2.) Mintz-Hittner HA, Kennedy KA, Chuang AZ. Efficacy of Intravitreal Bevacizumab for Stage 3+ Retinopathy of Prematurity. New England Journal of Medicine. 2011;364(7):603-615. doi.org/10.1056/NEJMoa1007374.
3.) Peyton C, Einspieler C. General Movements: A Behavioral Biomarker of Later Motor and Cognitive Dysfunction in NICU Graduates. Pediatric Annals. 2018;47(4):e159-e164. doi.org/10.3928/19382359-20180325-01.
4.) Garcia Gonzalez, J. M., Snyder, L., Blair, M., Rohr, A., Shapiro, M., & Greenwald, M. (2018). PROPHYLACTIC PERIPHERAL LASER AND FLUORESCEIN ANGIOGRAPHY AFTER BEVACIZUMAB FOR RETINOPATHY OF PREMATURITY. Retina (Philadelphia, Pa.), 38(4), 764–772. https://doi.org/10.1097/IAE.0000000000001581

Poster #101
Saturday, 9:55 am – 10:55 am

Abnormal Red Reflex: Etiologies in a Pediatric Ophthalmology Population

Sophie Y. Lin, BA; Kimberly G. Yen, MD; Huirong Zhu, PhD; Madhuri Chilakapati, MD

Baylor College of Medicine
Houston, TX

Introduction: To delineate the types of ocular pathology found in children who present with abnormal red reflex.

Methods: Retrospective search of electronic medical record for new patients with chief complaint 'abnormal red reflex' or 'leukocoria' was performed for March 2013 to March 2018 in a tertiary care pediatric ophthalmology clinic.

Results: Out of 198 identified patients, 44 were excluded due to inaccurate coding. Abnormal red reflex was most often referred by pediatricians (96.8%), followed by parents (2.1%) and other (1.1%). Most common finding was a normal exam (62.34%), followed by refractive error (20.13%), unilateral cataract (7.79%), corneal abnormality (3.25%), strabismus (1.95%), retinal abnormality (1.95%), iris abnormality (1.30%), and unilateral retinoblastoma (1.30%). Of the patients with refractive error, 87% had anisometropia and 13% had bilateral astigmatism. Of the patients with anisometropia, median amount of anisometropia was 1.75D for astigmatism (range: +1.25 to +3.00), +2.88 for hyperopia (range: +1.25 to +4.00), and -6.75 for myopia (range: -1.00 to -19.25). Amblyopia was diagnosed in 84% of patients with refractive error and 83% of patients with cataract.

Discussion: Pediatricians are key in the detection of abnormal red reflex. Although retinoblastoma is a common concern when patients are referred, other visually significant etiologies are frequently found.

Conclusion: Education of pediatricians on detecting abnormal red reflex is critical, so common conditions are not missed. In addition, serious pathologies may occur, making timely referral to an ophthalmologist essential to ensure prompt diagnosis and treatment.

References: 1. Tamura M, Teixeira L. Leukocoria and the red reflex test. Einstein 2009; 7: 376-382.
2. Balmer A, Munier F. Differential diagnosis of leukocoria and strabismus, first presenting signs of retinoblastoma. Clin Ophthalmol 2007; 1: 431-439.

Poster #102
Saturday, 9:55 am – 10:55 am

Accuracy of the Red Reflex Test to Detect Unequal Refractive Error

Aldo Vagge, MD, PhD; Kara C. LaMattina; Leonard B. Nelson

Wills Eye Hospital
Philadelphia, PA, USA

Introduction: Anisometropia is a significant cause of amblyopia, and may be difficult to detect in the absence of strabismus. We sought to determine the accuracy of the red reflex test in the detection of anisometropia.

Methods: Prospective, single-masked study which included new patients under the age of 18 who had not undergone pharmacologic pupillary dilation. A fellow who was masked to all clinical information illuminated both eyes with a direct ophthalmoscope in a darkened room from a distance of one meter, assessing whether the red reflex between the two eyes was symmetric or asymmetric. The patient was then cyclopleged and refraction was performed by an attending pediatric ophthalmologist. Exclusion criteria included the presence of strabismus, anisocoria, prior intraocular surgery, media opacity, leukocoria, and nystagmus. Sensitivity was compared to a null hypothesized value of 50% using a one-sided binomial test.

Results: Ninety-two patients with a mean age of 7.3 years (range 3 months - 16 years) were enrolled in the study. Anisometropia greater than 1.5 diopters in spherical equivalent (4 patients, range -10.625 to -2.625) or cylinder (3 patients, range 1.75 to 2.25) was accurately detected by red reflex testing in each case.

Discussion: Education of pediatricians on evaluating the red reflex in terms of both brightness and also symmetry of pupillary crescents may increase their detection of anisometropia.

Conclusion: The red reflex test can be an accurate screening tool to detect anisometropia when performed by an ophthalmologist and pediatrician as well.

References: 1. Tongue AC, Cibis GW. Bruckner test. Ophthalmology. 1981;88(10):1041-4.
2. Kothari MT. Can the Bruckner test be used as a rapid screening test to detect significant refractive errors in children? Indian J Ophthalmol. 2007;55(3):213-5.
3. Jain P, Kothari MT, Gode V. The opportunistic screening of refractive errors in school-going children by pediatrician using enhanced Bruckner test. Indian J Ophthalmol. 2016;64(10):733-6.

Poster #103
Saturday, 9:55 am – 10:55 am

Objective Measurement of Visual Acuity by Optokinetic Nystagmus Suppression

Anja Palmowski-Wolfe; Noémie Schwob, pract. med.

University Eye Hospital Basel, University of Basel
Basel, Switzerland

Introduction: The optokinetic nystagmus (OKN) response (induction/suppression) correlates with subjective visual acuity (VA) in adults but has not been studied extensively in school-aged children. We investigated the correlation between subjective and objective VA as elicited with a new computerized OKN suppression test ('SpeedWheel') in adults and school-aged children.

Methods: 15 children (6 - 12 years) and 27 adults with refractive errors, amblyopia, cataract, age-related macular degeneration and thyroid associated orbitopathy underwent testing of subjective VA with E- and Landolt C-symbols (Freiburg Acuity and Contrast Test (FrACT)) and objective VA (SpeedWheel) on a LCD screen. Statistical analysis: linear regression, Spearman correlation and Bland-Altman plots.

Results: Mean difference against the mean was -0.01 when SpeedWheel was compared to Landolt C, but -0.15 when compared to E-symbols. Overall, SpeedWheel correlated very strongly to FrACT ('E': $r= 0.85$; $p: < 0.001$; Landolt C: $r= 0.81$; $p: < 0.001$). This also held true in children ('E': $r= 0.74$; $p < 0.003$; Landolt C: $r= 0.69$; $p < 0.005$).

Discussion: In ocular disease, SpeedWheel appears to underestimate subjective VA. In 2 patients with loss of vision of unknown origin, subjective VA was lower than SpeedWheel VA. This is in agreement with the findings of Fukai et al. and could indicate aggravation or malingering. Çetinkaya et al. found no correlation between OKN induction and subjective VA in 52 children. Thus OKN suppression rather than induction may be a better objective acuity test.

Conclusion: SpeedWheel can assess visual acuity in in adults as well as in school aged children.

References: Bach, M., The Freiburg Visual Acuity test--automatic measurement of visual acuity. Optom Vis Sci, 1996. 73(1): p. 49-53.

Fukai, S., T. Hayakawa, and J. Tsutsui, Objective visual acuity testing by optokinetic nystagmus suppression. Jpn J Ophthalmol, 1990. 34(2): p. 239-44.

Cetinkaya, A., et al., Relationship between optokinetic nystagmus response and recognition visual acuity. Eye (Lond), 2008. 22(1): p. 77-81.

Poster #104
Saturday, 9:55 am – 10:55 am

A Device for the Assessment of Both Visual Acuity and Strabismus to Identify Amblyopic Risk Factors in Preverbal and Verbal Children – Pilot Study

Daphna Mezad Koursh, MD; Amir Rosenblatt, MD, MPH; Idit Kainan, MD; Chaim Stolovitch, MD

Ophthalmology Department, Tel Aviv Sourasky Medical Center; Tel Aviv University
Tel Aviv, Israel

Introduction: Instrument based vision screening for high refractive error and amblyopia is recommended for infants and children aged 1-3 years by the AAPOS[1]. Eye-N-JOY (ENJ) is a novel device (Patent no. US 9,844,317 B2), including a tablet, infrared camera, LCD glasses and cloud-based software. While child is watching images on the tablet screen, camera sensors track the child's eye movements as they respond to optical stimulation. The device provides a “pass” or “refer” result. The study assessed the accuracy of the ENJ device in identifying low vision or the presence of amblyopia risk factors in children

Methods: Prospective, single-center, comparison study. Children aged 1.5 to 6 years undergoing a full standard Pediatric Ophthalmology examination including visual acuity, alignment and cycloplegic refraction were also examined by the ENJ. Pediatric Ophthalmologists and Technician operating the ENJ were blinded to each other's findings.

Results: 51 children aged 1.5 to 6 were included. The ENJ evaluated VA by Teller in all 51 children, while Ophthalmologists were able to measure VA in 42 (82.3%) of children only (9 were evaluated by CSM method). The gold standard exam revealed: Mean visual acuity of 0.13 LogMAR (~20/27 Snellen). 3 children had strabismus, 4 children had anisometropia (> 1D). Overall agreement regarding pathological VA was 92.16%. Overall agreement regarding Strabismus was 72.54%.

Discussion: This is the first report of ENJ device vision screening. Compliance of patients was excellent.

Conclusion: The ENJ is designed to evaluate both visual acuity and misalignment. Further research is underway to evaluate the accuracy of this device.

References:

Poster #105
Saturday, 9:55 am – 10:55 am

Performance of a Photoscreener with Novel C.R. Infrared Wand Strabismus Estimation Compared to Another Screening Device and Comprehensive Examination

Stephanie L. Arnold, OMS II; Andrew W. Arnold, OMS II; Jacob H. Sprano, OMS IV; Robert W. Arnold, MD

Alaska Children's EYE & Strabismus
Anchorage, Alaska

Introduction: The 2WIN photoscreener (Adaptica, Padova, Italy)1 has a new function, Corneal Reflex (C.R.) utilizing a visible-light occluder transmitting infrared flash so phorias and intermittent tropias can be estimated.

Methods: In a prospective IRB study, pediatric eye patients had pre-cycloplegia 2WIN photoscreening compared with Retinomax and cycloplegic refraction. The (C.R) infrared occlusion wand was compared to prism cover test.

Results: Of 436 patients age 0.3 to 66 years: 172 were preschool, 245 school-age and 19 adults. 25% had developmental delays. For astigmatism patients (> 1 diopter), axis was within 10° of exam in 74% with 2WIN and 78% with Retinomax. In astigmatism patients, 2WIN was within 1 diopter cylinder power in 81% of 2WIN refractions compared to 85% with Retinomax. For hyperopic (> 1D) patients the 2WIN gave spherical equivalent 1.17±1.02 D and Retinomax 2.21±2.46 D compared to cycloplegic refractions +3.55±1.88 D. The C.R. strabismus horizontal deviation (y) was related to prism cover (x) with a strong correlation $y = 0.73x – 1.5$, $R2 = 0,65$, $p<0.01$. For 182 children (64% with 2003 refractive and strabismic risk factors), 2WIN refraction screen achieved sensitivity, specificity and PPV of 59%, 86% and 88% while adding C.R. improved to 69%, 88% and 91%.

Discussion: 2WIN provided valid estimates of astigmatic power and axis and hyperopia compared to Retinomax in delayed and normal children and adults. The new C.R. strabismus function reliably estimated prism cover test in horizontal and vertical deviations.

Conclusion: C.R. wand with 2WIN is useful for community pediatric screening and strabismus clinic.

References: 1. Kirk S, Armitage MD, Dunn S, Arnold RW: Calibration and Validation of the 2WIN Photoscreener Compared to the PlusoptiX S12 and the SPOT. J Pediatr Ophthalmol Strabismus 2014, 51(5):1-4.

Poster #106
Saturday, 9:55 am – 10:55 am

Performance of a Screening Game on Children and Adults with and without Binocular Suppression

Kyle A. Smith, OD, MA; Andrew W. Arnold, OMS II; Stephanie L. Arnold, OMS II; Jacob H. Sprano, OMS IV; Robert W. Arnold, MD

Alaska Children's EYE & Strabismus
Anchorage, Alaska

Introduction: A rapid screening version of the PDI Check near vision game on the autostereoscopic barrier screen of the Nintendo 3DS aims to quickly estimate monocular visual acuity, stereopsis and deuteranopia without the need for occluder or goggles. We try to find ocular suppression since the dynamic acuity optotypes are presented with binocular rivalry.

Methods: In an IRB approved prospective study, adult and pediatric eye patients had conventional clinical methods (Rosenbaum acuity, Titmus Fly, Worth 4-Dot, Ishihara) compared with PDI Check version 0.2.5 with respect to visual parameters and time.

Results: Of 78 children and adults (aged 5-62, mean 17), 12 had suppression. PDI check (x) estimated Titus (y) by y=0.61x-8, R2=0.64 and screened poor stereo (<200 sec arc) with sensitivity 90% and specificity 85%. PDI check green cone (x) estimated Ishihara missed by y=0.01x2-0.38x+4, R2=0.52 with a value of 60% yielding 80% sensitivity and 99% specificity for deuteranopia. When PDI acuity in one eye lagged chart acuity by -.8 logMAR, deep binocular suppression was screened with 67% sensitivity and 96% specificity. The time to completely screen with PDI was 111±43 seconds compared to 238±73 seconds for conventional. 87% preferred the game.

Discussion: The quick screening version of PDI Check correlates well with stereo and color and can help discern normal acuity and binocular suppression saving about 2±1 minutes per exam.

Conclusion: Eye technicians, pediatricians and researchers could benefit when PDI rapidly screens near vision without patches and goggles.

References:

Poster #107
Saturday, 9:55 am – 10:55 am

Cycloplegic Refractive Error and Amblyopia Risk Factors Found After Photo-Screening

Mariana A. Flores Pimentel, MD; Megan X. Law, MD; Alejandra G. De Alba Campomanes, MD, MPH

University of California San Francisco
San Francisco, California, USA

Introduction: Instrument-based vision screening has been endorsed for routine identification of amblyopia risk factors in children. GoCheckKids® is a smartphone photoscreening device that was adopted as the main screening method in our institution in 2017. We investigated the referral rates, positive predictive value and the correlation between cycloplegic refractive error and photorefraction results for the 3 possible fail categories.

Methods: Retrospective chart review of children <48 months that followed up in the pediatric ophthalmology clinic after a failed vision screening between February 2017 and August 2018.

Results: Of 80 children (mean age 26 months) that received a cycloplegic refraction, 17 (21%) met 2013 AAPOS ARF criteria. The main reason for referral was hyperopia+anisometropia (43/80) followed by hyperopia (12/80). 75% of children sent for 'anisometropia' (threshold >0.70D) did not meet any criteria; 11% of those sent for 'hyperopia' (threshold >1.24D) met hyperopia or astigmatism thresholds. 0/13 of 'myopia' referrals (threshold -2.00D) were positive for myopia. 50% met ARF criteria for a condition different than the instrument identified.

Discussion: The positive predictive value of GoCheckKids® was 21% for amblyopia risk factors. The most common fail reason was anisometropia and/or hyperopia but most children were found to have astigmatism. GoCheckKids® does not include 'astigmatism' as a fail criterion because of the use of a single-axis flash; thresholds for this instrument may need to be refined for age, prevalence of astigmatism and single-flash axis method having to encompass both sphere and 'with-the-rule' astigmatism detection.

Conclusion: As new vision screening devices penetrate the market it is important to independently evaluate their performance in clinical practice.

References: 1. Peterseim MMW, Rhodes RS, Patel RN, Wilson E, Edmondson LE, Logan SA, Cheeseman EW, Shortridge E, Trivedi RH. Effectiveness of the GoCheck Kids Vision Screener in Detecting Amblyopia Risk Factors. Am J Ophthalmol 2018; 187: 87-91. 2. Arnold RW, Armitage MD. Performance of Four New Photoscreeners on Pediatric Patients with High-Risk Amblyopia. J Pediatr Ophthalmol Strabismus 2014; 51 (1): 46-52.
3. Arnold RW, O'Neil JW, Cooper KL, Silbert DI, Donahue SP. Evaluation of a smartphone photoscreening app to detect refractive amblyopia risk factors in children aged 1-6 years. Clinical Ophthalmology 2018: 12: 1533-37.

Poster #108
Saturday, 9:55 am – 10:55 am

A Novel Objective Visual Acuity Screener for Preschool Children

Ben Thompson, PhD; Shuan Dai, MD; Paul Harris, OD; Christine Nearchou, OD; Mehrdad Sangi, PhD; Jason Turuwhenua, PhD; Eileen Birch, PhD; On behalf of the OKN-VA Study Group

University of Waterloo
Ontario, Canada

Introduction: We report initial evaluation of a novel OKN-based preschool visual acuity (VA) screener, including comparison with E-ETDRS VA measurement in adults and sensitivity and specificity for detecting monocular visual impairment in preschool children.

Methods: 60 children (3-6 years) and 10 adults participated. Vanishing optotypes (a central bright circle with diameter defined as logMAR stroke width and an outer dark annulus) were monocularly viewed while drifting left or right on a gray background. For children, test trials were interspersed within an animated video. Our prototype (Objective Acuity Ltd.) displayed the stimuli and video-recorded OKN for offline analysis using semi-automated algorithms1,2.

Results: The objective VA screener had sensitivity of 0.82 and specificity of 0.88 for detecting visual impairment (ATS-HOTV >0.7 logMAR) in children. Positive likelihood ratio was 6.5 (95% CI: 2.9-14.5); i.e., the probability of a positive test result was 6.5 times more likely if visual impairment was present vs absent. Objective measurement of VA in adults was positively correlated with automated ETDRS measurement (R^2 = 0.83). After adjusting OKN VA measurement for a 0.13 logMAR bias, the 95% CI for VA measurement by the two methods was 0.24 logMAR (2.4 lines), similar to ETDRS test-retest reliability.

Discussion: Promising results with our current preschool screening prototype justifies further refinement and automation of the technique.

Conclusion: OKN induction and measurement has the potential to provide an objective VA screening test for preschool children and non-verbal patients who are unable to comply with chart-based VA tests.

References: 1. Sangi M, Thompson B, Turuwhenua J. An Optokinetic Nystagmus Detection Method for Use With Young Children. IEEE J Transl Eng Health Med 2015; 3:1600110.
2. Turuwhenua J, Yu TY, Mazharullah Z, Thompson B. A method for detecting optokinetic nystagmus based on the optic flow of the limbus. Vision Res. 2014; 103:75-82.

Poster #109
Saturday, 9:55 am – 10:55 am

The Effect of Delay in Obtaining an Eye Exam After a Failed Vision Screening

Anne M. Langguth, MD; Nicholas B. Dimenstein; Scott A. Larson, MD

The University of Iowa Department of Ophthalmology and Visual Sciences
Iowa City, Iowa

Introduction: This study examines the impact of the elapsed time to first eye exam after a failed photoscreen on vision outcomes amongst pre-school children from a well-established vision screening program.

Methods: Analysis of records of all children over a 13-year period who failed a photoscreen by the Iowa KidSight program and were subsequently seen at the University of Iowa.

Results: Of the 320 subjects included, the average time between the screening and their first eye exam was 5.5 months. Amongst those with amblyopia, the average elapsed time between screening and eye exam for those who attained normal vision was 5.1 months (95%CI 3.9-6.2 months), which was significantly shorter than for those who did not obtain normal vision (8.5 months, 95%CI 5.5-11.4 months, p=0.0004). The average time to first exam of subjects 0-2 years compared to those 3 years or older (p=0.279) was not significantly different, nor was the time different in those with strabismus compared with those without strabismus (p=0.2352).

Discussion: A shorter time to first exam following a failed vision photoscreen was associated with a significantly higher likelihood of attaining normal vision in this group of children. Various other clinical factors including gender, age, and the presence of strabismus or amblyopia at time of first exam did not show significant differences in elapsed time.

Conclusion: This study suggests that delaying the time to first ophthalmologic exam following a failed vision screen adversely affects the chance of attaining normal vision. This provides evidence for enhancing referral networks and assisting families in accessing appropriate resources following a failed vision photoscreen.

References: US Preventative Services Task Force. Vision Screening in Children Aged 6 months to 5 years: US Preventative Services Task Force Recommendation Statement. Journal of the American Medical Association. 2017;318(9):836-844.
Practical Community Photoscreening in Very Young Children. Pediatrics. 2013;131(3):764-769.

Poster #110
Saturday, 9:55 am – 10:55 am

Prevalence of Amblyopia in Bulgaria: Does the Lack of a Screening Program Affect the Statistics

Stela P. Dikova, MD, PhD; Stefan A. Dragoev, MD; Violeta S. Chernodrinska, MD, PhD, Prof

Medical University - Sofia
Sofia, Bulgaria

Introduction: The purpose of the study is to establish the prevalence of amblyopia in children, aged 4 to 10 years, in Bulgaria and to define the distribution of the main types of amblyopia.

Methods: A complete ophthalmological examination was performed on 3540 children, in 12 cities in Bulgaria. Amblyopia was defined as reduction of the BCVA for near and far under 40/60 on one or on both eyes in the absence of any pathology of the eye, excluding a pathology leading to stimulus deprivation amblyopia, and in the presence of an amblyogenic factor.

Results: 4,94% of the children were diagnosed with amblyopia: strabismic and combined amblyopia - 0,25%, anisometropic - 2,66%, isoametropic - 1,81% and deprivation - 0,22%. For 54,9% of the children it was the first ophthalmological examination (mean age 6,9): in the SouthEast region - 70,7%, contrary to the NorthWest region - 47,9%, where a number of charity screening programs were conducted in the past decade.

Discussion: The fact that the greater part (4,5%) of the amblyopia is due to uncorrected refractive errors (anisometropia and isoametropia) is alarming. This could be explained with the lack of a vision screening program, as the strabismus is easily seen by the parents and they seek an ophthalmologist, contrary to the refractive errors, which could remain undetected by the parents.

Conclusion: The prevalence of amblyopia in the country (4,94%) is more than the expected, based on data from other authors. The lack of a national vision screening program in Bulgaria might be the main reason along with the insufficient number of pediatric ophthalmologists and the lack of awareness among the parents.

References: 1. Hassan Hashemi MD, Reza Pakzad MSc, Abbasali Yekta PhD, Parinaz Bostamzad MD, Mohamadreza Aghamirsalim MD, Sara Sardari MSc, Mehrnaz Valadkhan MSc, Mojgan Pakbin MSc, Samira Heydarian PhD & Mehdi Khabazkhoob PhD (2018) Global and regional estimates of prevalence of amblyopia: A systematic review and meta-analysis, Strabismus, DOI: 10.1080/09273972.2018.1500618

Poster #111
Saturday, 9:55 am – 10:55 am

Exploiting Principles of Timing-Dependent Plasticity to Treat Amblyopia

Eric D. Gaier, MD, PhD; Daniel Montgomery; Arnold Heynen, PhD; Mark F. Bear, PhD

Boston Children's Hospital, Massachusetts Institute of Technology
Boston, MA

Introduction: Amblyopia imparts a delay in visually evoked potential (VEP) latency through the affected eye that neutralizes with successful treatment.1,2 Based on principles of timing-dependent synaptic plasticity, a delay in signals reaching the visual cortex promotes depression of synaptic efficacy.3 Along this line, we hypothesize that a temporal advantage imparted through the amblyopic eye could be used to promote recovery. To this goal, we tested whether temporal phase offset training (TPOT) could shift ocular dominance.

Methods: We used a well-established model of visual cortical plasticity in juvenile mice, who have a contralateral-dominant representation of each eye in binocular visual cortex. Measuring VEPs in layer 4 of primary visual cortex in awake, head-fixed mice, we selectively presented stimuli to each eye with a temporal offset.

Results: In adolescent mice (P32, N=9), ipsilateral-leading TPOT (33 ms offset) strengthened VEPs elicited through the inherently weaker ipsilateral eye, whereas contralateral eye responses were unchanged. This resulted in a reduction in the contralateral/ipsilateral ratio toward binocularity. Varying the TPOT interval confirmed 33 ms as the optimal offset for TPOT. Use of a multipolar, laminar probe revealed that TPOT induced the largest effect in cortical layer 2/3.

Discussion: TPOT is sufficient to induce eye-specific potentiation in primary visual cortex to shift ocular dominance. Future experiments are planned to elucidate the characteristics, mechanism and clinical applicability of TPOT in the context of visual cortical neuroplasticity and amblyopia.

Conclusion: Modulation of interocular temporal phase is a novel potential target in the treatment of amblyopia.

References: 1. Parisi V, Scarale ME, Balducci N, Fresina M, Campos EC. Electrophysiological detection of delayed postretinal neural conduction in human amblyopia. Invest Ophthalmol Vis Sci. 2010;51(10):5041-5048.
2. Kelly JP, Tarczy-Hornoch K, Herlihy E, Weiss AH. Occlusion therapy improves phase-alignment of the cortical response in amblyopia. Vision Res. 2015;114:142-150.
3. Smith GB, Heynen AJ, Bear MF. Bidirectional synaptic mechanisms of ocular dominance plasticity in visual cortex. Philos Trans R Soc Lond B Biol Sci. 2009;364(1515):357-367.

Poster #112
Saturday, 9:55 am – 10:55 am

A Retrospective Study to Analyse Results of Continuous Fulltime/Total Occlusion in Cases of Unilateral Severe Refractory Amblyopia

Nikhil V. Rishikeshi, DO,FPOS; Tejaswini Kirpekar

H.V.DESAI EYE HOSPITAL, PUNE, MAHARASHTRA, INDIA
H.V.DESAI EYE HOSPITAL, HADAPSAR, PUNE, MAHARASHTRA, INDIA

Introduction: A retrospective study that showed that increasing intensity of patching the sound eye to 24 hours a day improved vision in refractory cases of severe, unilateral amblyopia after conventional methods of patching failed to show improvement.

Methods: Perfectly prescribed glasses used before starting occlusion, after cycloplegic retinoscopy. Any change in refraction prescribed with previous conventional occlusion therapy for 4 weeks and re-evaluated before starting continuous full time occlusion. Continuous occlusion was given for a period of 6 weeks. In case of no improvement after 6 weeks patching was discontinued. In case of visual improvement at the end of 6 weeks, full time patching was continued for another 6 weeks with 2 weekly follow ups and then gradually weaned off.

Results: 60 subjects- 28 males recruited in 3 months . Treated for 3 months (2 cycles of 6 weeks continuous total patching maximum) and then shifted back to conventional occlusion therapy.Age range- 3 to 15 years.78 % had improved distance Logmar vision and near vision.Analysis by the SPSS Software showed a statistically significant reduction in the severe amblyopia in 78 %.

Discussion: patients with unilateral severe amblyopia, refractory to all conventional methods of occlusion therapy showed a remarkable improvement in visual acuity by the said treatment. None of them showed deterioration of vision in the sound eye.

Conclusion: Continuous, full-time occlusion definitely improves visual acuity in unilateral, severe amblyopia.

References: 1.Irfani I, Feriyanto F, Oktarima P, Kartasasmita A. Visual Acuity Improvement in Continuous vs Divided Occlusion in Anisometropic Amblyopia. Open Ophthalmol J. 2018 Feb 14;12:1-6.

2.Yazdani N, Sadeghi R, Momeni-Moghaddam H, Zarifmahmoudi L, Ehsaei A, Barrett BT. Part-time versus full-time occlusion therapy for treatment of amblyopia: A meta-analysis. J Curr Ophthalmol. 2017 Mar 6;29(2):76-84

3.Longmuir S, Pfeifer W, Scott W, Olson R. Effect of occlusion amblyopia after prescribed full-time occlusion on long-term visual acuity outcomes. J Pediatr Ophthalmol Strabismus. 2013 Mar-Apr;50(2):94-101.

Poster #113
Saturday, 9:55 am – 10:55 am

The Use of Occlusive Contact Lenses after Failure of Conventional Treatment of Amblyopia- Revisited

Patrick Watts, FRCOphth; Mohammad S. Abu-Ain, FRCOphth

University Hospital Wales, UK
Wales, UK

Introduction: Amblyopia is most commonly treated with patches or atropinization of the sound eye. The purpose of this study was to evaluate the usefulness and assess the risks associated with occlusive contact lenses (OCL) use to treat resistant amblyopia in children who failed the conventional amblyopia treatment with patching and atropinization.

Methods: This was a retrospective case series of all children treated with an occlusive contact lens in the sound eye over an 8-year period. Data was collected on the age, gender, type of amblyopia, previous treatment received and its duration. The compliance, tolerance and adverse effects of OCL were recorded.

Results: There were 12 patients with 10 male. The mean age at the time of OCL use was 47.3 months (range 26-86 months). Anisometropic amblyopia was present in 1, combined anisometropia and strabismus was present in 3, strabismic amblyopia in 5, and stimulus deprivation amblyopia in 3. All patients had conventional patching for a mean period of 14 months, followed by atropinization in 9 patients for a mean period of 4 months. The mean duration of OCL use ranged from 2 week to 6 months. There were 9 patients with visual improvement (70%). The mean improvement seen was 0.4 Log MAR.

Discussion: There was no occlusion amblyopia. Four patients had conjunctivitis; one had a peripheral corneal abrasion.

Conclusion: The use of OCL is useful adjunct in the treatment of amblyopia that is not responding to conventional treatment. The side affect profile is acceptable but patients require close monitoring.

References: 1. Eustis HS & Chamberlain D. Treatment for Amblyopia: Results Using Occlusive Contact Lens. J Pediatr Ophthalmol Strabismus 1996;33:319-322
2. Collins RS, McChesney ME, McCluer CA, Schatz MP. Occlusion properties of prosthetic contact lenses for the treatment of Amblyopia. J AAPOS. 2008; 12: 565-568
3. Joslin CE, Mcmahon TT, Kaufman LM. The effectiveness of occluder contact lenses in improving occlusion compliance in patients that have failed Traditional Occlusion. Optom & Vis Sci 2002; 79:376-380

Poster #114
Saturday, 9:55 am – 10:55 am

Evaluation of Part-time Occlusion Compliance for the Treatment of Amblyopia

Victoria Sattarova, MSc; Reecha S. Bahl, MD

Children's Hospital of Michigan, Kresge Eye Institute, Wayne State University School of Medicine
Detroit, Michigan

Introduction: Amblyopia is the most prevalent condition affecting visual acuity in children. If left untreated, it leads to permanent visual impairment with negative consequences on quality of life [1]. Current standard of care is dominant eye occlusion. This study aimed to evaluate the adherence to occlusion, and determine parameters leading to non-compliance.

Methods: A retrospective analysis was performed of patients age 0-17 years treated for amblyopia with occlusion therapy from 1/2013-12/2016. Data were collected on demographic information, prescribed course of treatment, reported hours of treatment, and barriers to compliance.

Results: Of the 217 patients retained through follow up, compliance rates were as follows: 30.9% excellent, 15.2% good, 20.3% fair, 18.4% poor, and 15.2% none. Patient demographics included 35.9% Caucasian, 33.2% African American races. Patients without follow up were significantly older than those with follow up ($p<0.05$). Higher number of follow up visits, fewer prescribed patching hours, white race, and patients undergoing strabismus surgery each correlated with better compliance ($p<0.05$).

Discussion: Adherence to patching in our patient population is lower than that reported in other studies [2], [3]. Additionally, the patient demographics in our study are unique in that we have a nearly equal race representation of Caucasian and African American patients. It is important to consider and address contributing factors such as number of follow ups, age, prescribed hours, race, and history of surgery to achieve improved outcomes.

Conclusion: Using our findings on compliance and patient demographics, we can specifically target these groups and implement interventions to improve patient outcomes and quality of care.

References: [1] Carlton J, Kaltenthaler E. Amblyopia and quality of life: a systematic review. Eye (Lond). 2011;25(4):403-413.

[2] Rutstein RP QG, Lazar EL, Beck RW, Bonsall DJ, Cotter SA, Crouch ER, III, Holmes JM, BM, Hoover DL, Leske DA, Lorenzana IJ, Repka MX, Suh DW. A Randomized Trial Comparing Bangerter Filters and Patching for the Treatment of Moderate Amblyopia in Children. Ophthalmology. 2010;117(5):998-1004.e1006.

[3] Wallace DK, and Pediatric Eye Disease Investigator Group. A randomized trial to evaluate 2 hours of daily patching for strabismic and anisometropic amblyopia in children. Ophthalmology. 2006;113(6):904-912.

Poster #115
Saturday, 9:55 am – 10:55 am

Comparative Evaluation of Binocular Visual Stimulation Versus Occlusion Therapy in Children with Anisometropic Amblyopia

Shayeri S. Roy, MBBS; Rohit R. Saxena, MD; Pradeep P. Sharma, MD; Swati S. Phuljhele, MD

DR. RAJENDRA PRASAD INSTITUTE FOR OPHTHALMIC SCIENCES, AIIMS
NEW DELHI, INDIA

Introduction: Dichoptic video games based amblyopia therapy is a newer treatment modality. The aim is to compare smart phone based dichoptic video game with occlusion therapy in children with anisometropic amblyopia.

Methods: 55 children aged between 5-15 years having anisometropic amblyopia were included and randomised into two groups. Group 1(n=27) played dichoptic video game for 2 hours/day and group 2(n=28) received standard occlusion therapy of 6 hours/day. All patients were evaluated for BCVA, near vision, contrast sensitivity and near and distant stereoacuity at baseline, 1, 2 and 3 months.

Results: Mean distant BCVA at baseline was 0.70 logMAR in group 1 and 0.73 logMAR in group 2, which improved to 0.49 in group 1 and 0.52 in group 2 (p value <0.001 for both). Similarly, mean near vision at baseline was 0.81logMAR and 0.82logMAR respectively, which improved to 0.62 logMAR and 0.58 logMAR respectively(p<0.001 for both). Difference of BCVA between both groups were non-significant at baseline(p=0.13) and at three months(p=0.15). Contrast sensitivity was 1.38 and 1.41 respectively, which improved to 1.6 and 1.73(p<0.001 for both). Near stereoacuity by TNO test improved significantly in group 1 only (p=0.006), whereas distant stereoacuity did not improve in either groups.

Discussion: Both groups showed significant improvement in BCVA, near vision and contrast sensitivity, whereas, near stereoacuity improved significantly only in group 1.

Conclusion: Dichoptic video games appear promising as a treatment for anisometropic amblyopia.

References: Hess RF, Mansouri B, Thompson B. A binocular approach to treating amblyopia: antisuppression therapy. Optom Vis Sci. 2010 Sep;87(9):697-704.
Li SL, Jost RM, Morale SE, Stager DR, Dao L, Stager D, Birch EE. A binocular iPad treatment for amblyopic children. Eye (Lond). 2014 Oct;28(10):1246-1253.

Poster #116
Saturday, 9:55 am – 10:55 am

Amblyopic Eye Accommodative Response in Children with Binocular Treatment

Reed M. Jost, MS; Jeffrey S. Hunter, MD; Lori Dao, MD; Cynthia L. Beauchamp, MD; Joel N. Leffler, MD; Becky Luu, OD; Eileen E. Birch, PhD

Retina Foundation of the Southwest
Dallas, Texas, USA

Introduction: While amblyopia treatment is effective in improving visual acuity of most amblyopic children, some fail to respond and many are left with residual amblyopia. It has been suggested that treatment that enhances retinal image quality (e.g., bifocals to compensate for an amblyopic eye's reduced accommodation) may increase the magnitude of visual acuity improvement achieved with amblyopia treatment.[1,2] Here, we prospectively assess the relationship of amblyopic eye accommodative response and visual acuity improvement with binocular amblyopia treatment.

Methods: Amblyopic eye accommodative response to a letter chart at 33cm (3.00 D) was prospectively evaluated in 139 children (age 4-16y, mean 8.6y, 99 amblyopic, 25 non-amblyopic strabismus and/or anisometropia, 15 normal) using the Grand Seiko Autorefractor WAM-5500 while fellow eye is occluded. Accommodative response was adjusted for their habitual spectacle correction. Best-corrected visual acuity (BCVA) was assessed at baseline and post binocular amblyopia treatment (n=44).

Results: Poorer accommodative response was related to poorer amblyopic eye BCVA for all children ($p<0.00001$) and amblyopic children alone ($p=0.015$). Amblyopic children whose accommodative response was within the normal range (≥1.00 D; n=15) were no more likely than children with poor accommodative response (<1.00D; n=29) to respond to binocular amblyopia treatment by improving ≥0.1 logMAR in BCVA ($p=1.00$, mean improvement 0.12 logMAR). Risk ratio for poor accommodative response at baseline was not significant [RR=1.03 (95%CI: 0.30-3.57)].

Discussion: Amblyopic eye accommodative response at baseline was not associated with effectiveness of binocular amblyopia treatment.

Conclusion: Amblyopic children with poor accommodation respond to binocular amblyopia treatment as well as children with good accommodation.

References: 1. Manh V; Chen AM; Tarczy-Hornoch K; Cotter SA; Candy TR. 'Accommodative performance of children with unilateral amblyopia.' Invest Ophthalmol Vis Sci. 2015;56:1193-1207.
2. Chen AM; Manh V; Candy TR. 'Longitudinal evaluation of accommodation during treatment for unilateral amblyopia.' Invest Ophthalmol Vis Sci. 2018;59:2187-2196.

Poster #117
Saturday, 9:55 am – 10:55 am

Effect of an Integrated Perceptual Learning Game on Visual Functions of Children with Amblyopia

Yoon H. Lee, MD; Marcello Maniglia, PhD; Federico Velez, MD; Joseph L. Demer, MD, PhD; Aaron Seitz, PhD; Stacy Pineles, MD, MS

1. Stein Eye Institute, David Geffen School of Medicine, University of California Los Angeles 2 Department of Psychology, University of California Riverside 3 Department of Ophthalmology, Duke University School of Medicine 4 Doheny Eye Institute 5 Department of Neurology, David Geffen School of Medicine, University of California Los Angeles
1. Los Angeles, California 2. Riverside, California 3. Durham, North Carolina 4. Los Angeles, California 5. Los Angeles, California

Introduction: Current amblyopia treatment may occasionally be associated with poor compliance and failure to improve. This study investigates a treatment utilizing a perceptual learning (PL) video game, in which players click targets presented at varying spatial frequencies and orientations.

Methods: Subjects with amblyopia whose visual acuity (VA) did not improve with 6-weeks of patching, were randomized to: (1)monocular PL 20 min/day (played with non-amblyopic eye patched, n=8), (2)binocular PL 20 min/day (polarized lens/screen to promote binocularity, n=7), or (3)patching only (n=10) 2 hours/day. VA, low contrast acuity (LCA) and reading speed (RS) were measured before and after 8 weeks of treatment and analyzed by amblyopia subtype.

Results: Twenty-five subjects (age 8-18, type: strabismic (11), anisometropic (10), mixed (4)) were included. VA in all groups significantly improved post-treatment, but the improvement in VA, LCA, and RS was statistically similar in all 3 treatment groups. In strabismic amblyopes only (n=11), RS improved significantly more with PL than patching by 113 wpm for monocular (p=0.026) and 93 wpm for binocular PL (p=0.047). However, when all types of amblyopia were included, improvement in RS did not differ significantly according to treatment method.

Discussion: There was a similar improvement in VA and LCA in all subjects, regardless of treatment group. Subgroup analysis revealed that children with strabismic amblyopia had significantly more improvement in amblyopic eye RS after playing PL games compared to patching but this was not seen overall.

Conclusion: A PL game, whether played monocularly or binocularly improves VA or LCA similarly to patching.

References: 1. Liu XY, Zhang T, Jia YL, Wang NL, Yu C. The therapeutic impact of perceptual learning on juvenile amblyopia with or without previous patching treatment. Investig Ophthalmol Vis Sci. 2011;52(3):1531-1538. doi:10.1167/iovs.10-6355
2. Deveau J, Ozer DJ, Seitz AR. Improved vision and on-field performance in baseball through perceptual learning. Curr Biol. 2014;24(4):R146-R147. doi:10.1016/j.cub.2014.01.004

Poster #118
Saturday, 9:55 am – 10:55 am

Correlation of Patching Compliance with Visual Outcomes in Unilateral Aphakia

Jonathan A. Go, BBA; Huirong Zhu, PhD; Kimberly G. Yen, MD

Texas Children's Hospital
Houston, Texas

Introduction: The purpose of this study is to analyze the correlation between patching compliance with visual outcome in pediatric patients with amblyopia due to unilateral aphakia following cataract surgery.

Methods: Pediatric patients with unilateral cataract surgery and resulting aphakia between January 2003 and October 2015 prior to age 1 at a large pediatric hospital were included. Patients without visual acuity (VA) using Snellen or HOTV at most recent visit were excluded.

Results: 43 patients met criteria. Patching compliance was assessed based on the recommendation that patients patch 50% of waking hours. Patients who reported >/=67% compliance in patching before ages 2-3 years (p=0.025) and >/=56% compliance in patching before age 4 years (p=0.047) had a statistically significant improvement in VA. There was a statistically significant difference in reported patching compliance in patients with VA >/=20/40 compared to those with VA between 20/40-20/200 and VA </=20/200 (p=0.017). No significance between VA and gender, distance from hospital, race, or language was found.

Discussion: Compliance with patching >/=67% of recommended patching time before ages 2 and 3 years and >/=56% of recommended time before age 4 appears to be associated with better visual outcomes. This suggests that compliance prior to age 2 and 3 results in better visual outcomes. Our data suggests that individual patient compliance does not significantly vary over time. Demographic disparities can be overcome with good patient education.

Conclusion: Ophthalmologists should emphasize patching compliance at an early age and patient education for unilaterally aphakic pediatric patients.

References: Drews-Botsch CD, Celano M, Kruger S, Hartmann EE, for the Infant Aphakia Treatment Study. Adherence to Occlusion Therapy in the First Six Months of Follow-Up and Visual Acuity among Participants in the Infant Aphakia Treatment Study (IATS). Investigative Ophthalmology & Visual Science. 2012;53(7):3368-3375. doi:10.1167/iovs.11-8457.

Drews-Botsch CD, Hartmann EE, Celano M, for the Infant Aphakia Treatment Study Group. Predictors of adherence to occlusion therapy three months after cataract extraction in the Infant Aphakia Treatment Study. Journal of Aapos. 2012;16(2):150-155. doi:10.1016/j.jaapos.2011.12.149.

Lambert SR, Plager DA, Lynn M, Wilson ME. Visual Outcome Following the Reduction or Cessation of Patching Therapy After Early Unilateral Cataract Surgery. Archives of Ophthalmology. 2008;126(8):1071-1074. doi:10.1001/archopht.126.8.1071.

Poster #119
Saturday, 9:55 am – 10:55 am

Clinical Outcomes of Pediatric Uveitis in Patients in an Amblyogenic Age Range

Rebecca F. Neustein, MD; Steven Yeh, MD; Phoebe D. Lenhart, MD

Emory Eye Center
1365 Clifton Road, Building B, Atlanta GA 30322

Introduction: Children with uveitis are at risk of vision loss from their inflammatory disease as well as from resultant amblyopia.[1,2] Purpose: to evaluate visual outcomes, uveitic activity, and amblyopia prevalence in pediatric uveitis patients lacking other amblyogenic diagnoses.

Methods: Review of children diagnosed with uveitis (ages 0-9 years), treated at XXX, with >/=2 follow-up visits. Amblyopia was diagnosed if recorded in pediatric ophthalmology charts; uveitis activity was standardly graded.[3] Primary study outcome was Snellen-equivalent logmar visual acuity (VA) at last follow-up. Secondary outcomes included: uveitic pathologies/activity, and treatment for uveitis and amblyopia. Mann-Whitney tests assessed difference in VA between uveitic pathology subgroups.

Results: Included were 25 eyes (14 children). Median[range] age at uveitis diagnosis and mean(+/-SD) follow-up were 4.6 [3.9-5.1] and 3.6Â±3.4 years, respectively. Median VA in worse-seeing eyes was 20/80[20/30-20/200]. Presence of CME at last follow-up was associated with lower VA in the worse-seeing eye (20/140 vs. 20/50, p=0.04). The following were not statistically associated with VA: band keratopathy, posterior synechiae, uveitic activity (median uveitis flares/year=1.61[1.02-2.89]. Amblyopia was diagnosed in 8(57%) children, with mean patching duration 22mos; median age at uveitis diagnosis in amblyopic vs. non-amblyopic children was similar (4.66[4.25-5.8] vs. 4.25[2.83-7.42] years, p=0.613).

Discussion: Young children with uveitis maintained fair VA (median 20/80) in their worse-affected eyes. Presence of CME, but not uveitic activity, was associated with reduced VA. Amblyopia was diagnosed in 57%, but younger age at uveitis diagnosis was not predictive of amblyopia.

Conclusion: Amblyopia occurs commonly in young children with uveitis, requiring teamwork among eye care providers for prompt diagnosis and treatment.

References: 1. Holland GN, Stiehm ER. Special considerations in the evaluation and management of uveitis in children. Am J Ophthalmol. 2003;135(6):867-878.
2. Smith JA, Mackensen F, Sen HN, et al. Epidemiology and course of disease in childhood uveitis. Ophthalmology. 2009;116(8):1544-1551, 1551.e1541.
3. Jabs DA, Nussenblatt RB, Rosenbaum JT. Standardization of uveitis nomenclature for reporting clinical data. Results of the First International Workshop. Am J Ophthalmol. 2005;140(3):509-516.

Poster #120
Saturday, 9:55 am – 10:55 am

Effect of Enchroma Filter on Color Vision Screening using Ishihara and Farnsworth D-15 Color Vision Charts

Brandon Clair, MD; Vineela Varikuti, PhD, MBA; Charles Zhang, BS; Andrew Reynolds, MD

Ross Eye Institute, State University of New York at Buffalo
Buffalo, NY

Introduction: The prevalence of color vision deficiency (CVD) is about 0.5% in females and 8% in males.1 Although there is no cure for CVD, specially filtered glasses are purported to improve color contrast.2,3 One recent development is the Enchroma filter that stated to enhance color perception.4 We aim to study the effect of Enchroma filter on color vision screening (CVS) using Ishihara and Farnsworth D-15 color vision charts.

Methods: Records of 38 eyes of 19 patients with CVD were reviewed. Subjective response to with and without filter were evaluated using Ishihara and Farnsworth charts. The overall error scores were analyzed. Patients response to filter was assessed using survey questions.

Results: The mean error scores of no filter compared to Enchroma were significantly different using Ishihara (0.88±0.17 vs 0.85±0.19, P=0.017) and Farnsworth (2.82±0.19 vs 2.55±0.19, P=0.009). The filter reduced error scores in 16 eyes (Ishihara) and 24 eyes (Farnsworth). When tested with Farnsworth, 10 eyes improved from moderate to mild protan and 10 eyes improved from moderate to mild deutan. When tested with Ishihara, 11 eyes improved from moderate to mild deutan. 10 of 19 patients responded that with Enchroma filter the colors appeared brighter, enhanced contrast of the object and improved their color vision.

Discussion: Filters modify the wavelength transmission of participants and significantly reduce error scores using Ishihara and Farnsworth tests. Protans and deutans showed improvement using Farnsworth while Ishihara improved CVS only in deutans.

Conclusion: Enchroma filter significantly enhance color vision screening using Ishihara and Farnsworth D-15 charts.

References: 1. Birch J. Worldwide prevalence of red-green color deficiency. Journal of the Optical Society of America A. 2012;29(3):313-320.
2. Paulson HM. The X-Chrom Lens for Correction of Color Deficiency. Military Medicine. 1980;145(8):557-560.
3. Schlanger JL. The JLS lens: an aid for patients with color vision problems. Optometry & Vision Science. 1985;62(2):149-151.
4. Porter B. What is color? Enchroma glasses, neuroscience, and the mystery of color. Published September 11, 2016.

Poster #121
Saturday, 9:55 am – 10:55 am

Single Red Maddox Rod: An Easier Way To Determine Subjective Torsion

Monte I. Stavis, MD

Pediatric Ophthalmology and Adult Strabismus Center of Houston
Houston, Texas, USA

Introduction: Asthenopic symptoms, including eye discomfort, and headaches may be related to excess torsion. Subjective torsion is not always measured. Single red Maddox rod testing, which is not widely utilized, is presented as a simpler and easier way to determine torsion.

Methods: The left eye is patched and the room lights are dimly illuminated. A penlight is directed at the right eye. The red lines of the single Maddox rod are oriented starting fifteen degrees on the temporal side of the right eye, and then slowly rotated towards the straight up vertical position. The patient says stop, when the line appears horizontal. The Maddox is then started at fifteen degrees on the nasal side, and then slowly rotated until the red line appears horizontal. The left eye is then tested separately. Torsion can be estimated, or compared to torsion included on the compass app on most cell phones.

Results: Subjective excyclotorsion or incyclotorsion is easily determined, and not time intensive using this technique. The amount of torsion is sometimes slightly more than the double Maddox rod. Subjective numbers can vary on different visits.

Discussion: Subjective torsion, and its comparison to object torsion, is required in evaluation of asthenopia. Single Maddox red rod, unlike the double Maddox rod, requires no manipulation of a trial frame. Lancaster red-green or synoptohphore require another examiner.

Conclusion: Single Maddox rod is easy to perform and alerts the examiner to the possibility that asthenopia is secondary to torsion. This test can be performed on almost all patients age six and older.

References: Measurement of ocular cyclotorsion in superior oblique palsy using a single Maddox rod. Almog, Y, Nemet, AY, Ton Y. J Neuroophthalmol. 2014, Dec:34(4): 362-5

Cyclotorsion Measured in a Patient Population Using Three Different Methods: A Comparison Study. Flodin,S, Karisson, Anderson Grolund. Strabismus 2016;24 (1):26-36

Accuracy of double Maddox rod with induced hypertropia in normal subjects. Marsh, JD.et al, Am Orthopt J, 2014

Poster #122
Saturday, 9:55 am – 10:55 am

Utilizing Optical Coherence Tomography for Objective Assessment of Ocular Torsion

Haci Ugur Celik; Kara M. Cavuoto; Maja Kostic; Worawalun Honglertnapakul; Craig A. McKeown; Hilda Capo

Bascom Palmer Eye Institute
Miami, FL

Introduction: To evaluate ocular torsion objectively with optical coherence tomography (OCT).

Methods: Patients with subjective torsion by double Maddox rod (DMR) underwent imaging with the iVue OCT device. 6x6 scans of the optic nerve and macula of both eyes were obtained and overlaid. Objective torsion was assessed utilizing the disc-foveal angle (DFA), which was defined as the angle between a horizontal line through the disc center and the line connecting the fovea and disc center. The angle was measured with the scale option in Adobe Photoshop CS program for Macintosh. The objective torsion was analyzed using the sum and difference of the degrees of torsion in both eyes.

Results: 12 patients were enrolled. The mean age was 49.58 ±18.72 years. All patients had excyclotorsion, except for one. The range of torsion via DMR was 7.5 degrees of incyclotorsion to 40 degrees of excyclotorsion. The range of torsion via DFA was 2 degrees of excyclotorsion to 45.3 degrees. The Wilcoxon signed rank test found the comparison between the DMR and DFA summation was statistically significant (p=0.002); however there was no significant correlation between the DMR and DFA difference (Kendall's Tau=0.188, Spearman's Rank Correlation=0.238) or DMR and DFA summation (Kendall's Tau=0.326, Spearman's Rank Correlation=0.452).

Discussion: The tendency is to measure less excyclotorsion by DMR. This may be related to the normal anatomic position of the fovea. Discrepancies between the objective and subjective torsion may be attributed to sensory adaptation and fusional amplitudes.

Conclusion: Initial findings suggest that utilizing the DFA may be an objective method to analyze torsion; however more data is needed for confirmation.

References: 1. Sophocleous S. Use of optical coherence topography for objective assessment of fundus torsion. BMJ Case Rep. 2017 Feb 23;2017. pii: bcr2016216867.
2. Gegundez-Arias ME, Marin D, Bravo JM, Suero A. Locating the fovea center position in digital fundus images using thresholding and feature extraction techniques. Comput Med Imaging Graph. 2013 Jul-Sep;37(5-6):386-93.
3. Jonas RA, Wang YX, Yang H, Li JJ, Xu L, Panda-Jonas S, Jonas JB. Optic Disc -Fovea Angle: The Beijing Eye Study 2011. PLoS One. 2015 Nov 6;10(11):e0141771.

Poster #123
Saturday, 9:55 am – 10:55 am

Correlation Between Axial Length and Horizontal Extraocular Muscles Insertion Site Using Anterior Segment Optical Coherence Tomography in Normal Population

Nermeen M. Bahgat, MD; Dina M. El-Fayoumi, MD; Sherin H. Sadek, MD; Manal A. Kasem, MD; Mohamed M. Khafagy, MD; Dalia S. El-Emam, MD; Ghada H. Allam, MSc; Ragai M. Hatata, MD

Cairo University
Cairo,Egypt

Introduction: Previous studies proved the accuracy of anterior segment optical coherence tomography (AS-OCT) in identification of extraocular muscle insertion site.The aim of our study was to correlate between the axial length and the horizontal rectus muscle insertion site using Swept Source AS-OCT.

Methods: This observational, cross-sectional study was performed on the right eyes of 157 healthy subjects. The medial rectus (MR) and the lateral rectus (LR) insertion sites from the limbus were measured by Swept source AS-OCT (SS AS-OCT). These measurements were correlated to the axial length. Correlation was done by Pearson's correlation coefficient and confirmed by linear regression analysis and scatter diagrams.

Results: The Axial length correlated significantly with both insertions with a moderate positive correlation. For the MR insertion the model equation was: MR(mm) = 4.522 + 0.045 (AXL in mm) and for LR insertion the model equation was: LR(mm) = 5.72 + 0.048 (AXL in mm).

Discussion: AS-OCT can be performed prior to strabismus surgery for patients with axial myopia or hyperopia to exactly determine the insertion site of the horizontal muscle insertion site as this might modify the surgical plan especially in recurrent strabismus cases.

Conclusion: Significant positive correlation was found between horizontal extraocular muscle insertion site and the axial length which should be taken into consideration prior to any planning for strabismus surgery .

References: 1.Liu X, Wang F ,Xiao Y ,Ye X, Hou L. Measurment of the limbus -insertion distance in adult strabismus patients with anterior segment optical coherence tomography .Invest Ophthalmol Vis Sci 2011; 52:8370- 73.
2.Park KA,Lee JY,Oh SY.Reproducibility of horizontal extraocular muscle insertion distance in anterior segment optical coherence tomography and the effect of head postion.J AAPOS 2014;18:15-20.
3.Ngo CS,Smith D,Kraft SP.The accuracy of anterior segment optical coherence tomography (AS-OCT) in localizing extraocular rectus muscle insertions.JAAPOS 2015;19:233-6.

Poster #124
Saturday, 9:55 am – 10:55 am

Incidence of Strabismus in Children Initially Diagnosed with Pseudostrabismus using the Optum® Dataset

Won Yeol W. Ryu, MD; Ali Shariati; Scott R. Lambert, MD

Byers Eye Institute at Stanford
Palo Alto, California, United States

Introduction: Some children diagnosed with pseudostrabismus during early childhood are later found to have accommodative esotropia or intermittent exotropia. We used big data to determine the frequency with which children who were initially diagnosed with pseudostrabismus were later found to have strabismus.

Methods: This population-based retrospective cohort study used the Optum® SES medical claims dataset between 2002 and 2014. We included patients diagnosed with pseudostrabismus when <3 years of age. Patients diagnosed with strabismus before the diagnosis of pseudostrabismus were excluded. Age, gender, refractive error, and presence of amblyopia were assessed. 1% of the claims were analyzed.

Results: 45,267,843 claims for 529,720 patients were analyzed. 270 children were diagnosed with pseudostrabismus. Strabismus was later diagnosed in 9% of these children at a mean age of 3.9 ± 2.3 years. The most common types of strabismus diagnosed were esotropia (67%) and exotropia (21%). Amblyopia was present in 29% of the patients who were later diagnosed with strabismus. 71% of the patients diagnosed with amblyopia had esotropia. The mean time interval between the diagnosis of pseudostrabismus and strabismus was 2.3 ± 2.5 (range; 0.8 - 6.9) years.

Discussion: Accommodative esotropia can be misdiagnosed as pseudostrabismus during early childhood. A high percentage of children with accommodative esotropoia who were misdiagnosed with pseudostrabismus developed amblyopia presumably because there was more than a 2 year delay on average between the diagnosis of pseudostrabismus and strabismus.

Conclusion: Young children should not be diagnosed with pseudostrabismus unless a cycloplegic refraction is performed to exclude moderate or high hyperopia.

References: 1. Repka MX, Lum F, Burugapalli B. Strabismus, Strabismus Surgery, and Reoperation Rate in the United States: Analysis from the IRIS Registry. Ophthalmology 2018;125:1646-53.
2. Mohan K, Sharma A. Development of refractive accommodative esotropia in children initially diagnosed with pseudoesotropia. J AAPOS 2012;16:266-8.
3. Sefi-Yurdakul N, Tu?cu B. Development of Strabismus in Children Initially Diagnosed with Pseudostrabismus. Strabismus. 2016 Jun;24:70-3.

Poster #125
Saturday, 9:55 am – 10:55 am

Measuring Attention Bias in Subjects with Strabismus

Lina Raffa, MD, PhD[1,2]; Heather Fennell-Al Sayed, MSc[2], OC(C); Robert LaRoche, MD, FRCSC[2]

[1]Department of Ophthalmology, King Abdulaziz University Hospital, Jeddah, Saudi Arabia
[2]Department of Ophthalmology and Visual Sciences, Dalhousie University, IWK Health Centre, Halifax, Nova Scotia, Canada

Introduction: Despite the known negative psychosocial impact and the importance of facial aesthetics for patients with strabismus, until now the gaze pattern of the presumed attention bias has not been reported. The purpose of this study is to determine whether there is any attention bias toward the eye region in strabismic subjects.

Methods: Thirty images (15 digitally reconstructed color photographs to show strabismus and 15 photographs of volunteers without strabismus) were viewed in random order by 25 naive participants (age range 23-63 years; 15 females). Visual scan paths of participants were recorded using the EyeLink1000 and the individual parameters of saccades, fixations and dwell time were assessed using DataViewer software.

Results: While viewers primarily tended to fixate upon the eyes, the nose was the next most popular area of the face (both $p < 0.001$).There was a significant association between time to first fixation and the presence of strabismus in the images presented ($p<0.001$). When the eyes were viewed, there was more time spent looking at the strabismic eye ($p<0.001$), although the number of fixations toward the eyes was not significantly different between normal and strabismic faces ($p = 0.2$).

Discussion: Our findings show that the presence of strabismus in the features of the human face draws longer attention from the average viewer to the eye region, and in particular the strabismic eye.

Conclusion: This supports the notion reported in the literature that patients with strabismus are looked at differently.

References: 1. Haworth R, Sobey S, Chorney JM, Bezuhly M, Hong P. Measuring attentional bias in children with prominent ears: A prospective eye-tracking study. J Plast Reconstr Aesthet Surg. 2015;68:1662-6.
2. Van Schijndel O, Litschel R, Maal TJ, Berge SJ, Tasman AJ. Eye tracker based study: Perception of faces with a cleft lip and nose deformity. J Craniomaxillofac Surg. 2015;43:1620-5.
3. Chan KW, Deng L, Weissberg EM. Detection of Strabismus by Non-Health Care Professionals in an Ethnically Diverse Set of Images. JAMA Ophthalmol. 2016;134:30-6.

Poster #126
Saturday, 9:55 am – 10:55 am

Using the Diplopia Questionnaire as an Outcome for Strabismus Studies

Sasha A. Mansukhani, MBBS; Sarah R. Hatt, DBO; David A. Leske, MS; Jonathan M. Holmes, BM, BCh

Mayo Clinic
Rochester, Minnesota

Introduction: The diplopia questionnaire (DQ) is used both in clinical practice, and research (e.g. as a primary outcome measure in the Pediatric Eye Investigator Group [PEDIG] SAS1 study). Nevertheless, the reliability of the DQ has not been completely characterized. We evaluated test-retest reliability of the DQ and calculated outcome misclassification rate.

Methods: 100 adults with stable strabismus (< 5PD change in prism and alternate cover test measurements at distance and near), no evidence of change, stable visual acuity and no change in intervening treatment, completed the DQ at two consecutive office visits (median 71 days apart, range 5 to 350). Definitions of diplopia success corresponded to PEDIG SAS1 cohorts: 1) 'rarely' or 'never' for straight ahead distance (used for divergence insufficiency) and 2) 'rarely' or 'never' for straight ahead distance and reading (used for small-angle hypertropia). Patients were classified as success or not success for each administration of the DQ (using each definition). 95% limits of agreement were also calculated on a 0 to 100 scale.

Results: When defining success as rarely or never diplopic for distance, misclassification occurred in 5 (11%) of 45 (95% CI 4% to 24%). When defining success as rarely or never diplopic for distance and reading, misclassification occurred in 5 (10%) of 50 (95% CI 3% to 22%). 95% limits of agreement were 35.2 points.

Discussion: We have quantified test-retest variability of the DQ.

Conclusion: Misclassification using the DQ is infrequent but needs to be considered when interpreting study results.

References:

Poster #127
Saturday, 9:55 am – 10:55 am

Anomalous Superior Oblique Muscle in Congenital Fibrosis of the Extraocular Muscles

Talia N. Shoshany, BA; David G. Hunter, MD, PhD

Boston Children's Hospital
Boston, MA

Introduction: Congenital fibrosis of the extraocular muscles (CFEOM) is a rare genetic syndrome characterized by non-progressive ophthalmoplegia and ptosis. Mutations in axonal proteins have been identified in CFEOM and correlate with abnormal embryonic development of the oculomotor nucleus and its innervated muscles. Patients often require strabismus surgery to prevent functional limitations from anomalous compensatory head postures. We noticed abnormal superior oblique (SO) muscles intraoperatively in several children with CFEOM and wished to investigate this further.|

Methods: Retrospective chart review of patients evaluated for CFEOM at a teaching hospital between January 2010 and July 2018.

Results: Of 24 patients identified (ages 1 month-62 years), 10 (42%) had genetically-confirmed CFEOM. Twenty-two underwent strabismus surgery, 14 (64%) involving the SO muscle. Of these, 13 (93%) had a documented SO abnormality, including absent, thin, or anomalously inserted tendons in 9 (most commonly attached nasal to the superior rectus muscle), and tight muscles in 4.

Discussion: Almost all CFEOM patients who underwent SO surgery had abnormal SO muscles, a finding mentioned (though not well-characterized) in two previous reports to our knowledge. The high incidence of tendon misplacement may be under-appreciated given that tenotomies are often performed in the superonasal fornix, away from the tendon's insertion on the globe.|

Conclusion: CFEOM patients often have tight SO muscles or anomalously placed tendon insertions, suggesting that abnormal SO innervation is another feature of the disease process in these patients. Surgeons should expect to find such variants and should therefore plan to approach the SO tendon using a superonasal rather than superotemporal approach.|

References: 1. Brodsky, MC. Surgical Management of the Congenital Fibrosis Syndrome. American Orthoptic Journal. 1997; 47: 157-163.
2. Engle EC, Whitman MC. Ocular congenital cranial dysinnervation disorders (CCDDs): insights into axon growth and guidance. Human Molecular Genetics. 2017; 26(R1): R37-R44.
3. Graeber, C, Hunter, DG, Engle, EC. The Genetic Basis of Incomitant Strabismus: Consolidation of the Current Knowledge of the Genetic Foundations of Disease. Seminars in Ophthalmology, 2013; 28(5-6): 427-437

Poster #128
Saturday, 9:55 am – 10:55 am

Strabismus is Correlated with Gross Motor Function in Children with Cerebral Palsy

Heeyoung Choi, Dr; Hyeshin Jeon, Dr; Jaeho Jung

Pusan National University Hospital
Busan, South Korea

Introduction: Ophthalmic evaluation is limited and often neglected in patients with cerebral palsy (CP) because of the poor cooperation. This study was to investigate the correlation between clinical features of strabismus and motor dysfunction classified according to the Gross Motor Function Classification System (GMFCS) in patients with CP.

Methods: Sixty-five patients who are diagnosed with CP who had an ophthalmic examination between 2006 and 2014 were included in this retrospective study. The types of CP were classified as diplegia, hemiplegia, or quadriplegia for distribution of motor impairment; spastic, hypotonic, or mixed for abnormal muscle tonicity. The GMFCS was used to grade gross motor dysfunction, which was then classified as mild (grade 1, 2 and 3) or severe (grade 4 and 5). The relationship between strabismus characteristics and the level of GMFCS and type of CP were assessed.

Results: Thirty-eight and 27 patients had mild or severe motor deficit, respectively. Thirty-five patients had strabismus, which was more frequent in patients with severe motor impairment($P=0.024$). Exotropia and esotropia occurred with similar frequency. Constant and large-angle strabismus was frequently observed in patients with severe motor impairment($P<0.005$, 0.018). The topographical subtype of CP was not related to clinical features of strabismus.

Discussion: The prevalence of strabismus is higher in severe motor impairment. The constancy and angle of strabismus was related to the severity of motor impairment while the topographical subtype of CP was not.

Conclusion: Early ophthalmic evaluation may be necessary in these patients for detection of ophthalmic problems and early rehabilitation.

References: 1. Ghasia F, Brunstrom J, Gordon M, Tychsen L. Frequency and severity of visual sensory and motor deficits in children with cerebral palsy: gross motor function classification scale. Investigative ophthalmology & visual science 2008;49:572-580.
2. Pennefather PM, Tin W. Ocular abnormalities associated with cerebral palsy after preterm birth. Eye 2000;14:78-81.
3. Kozeis N, Anogeianaki A, Mitova DT et al. Visual function and execution of microsaccades related to reading skills, in cerebral palsied children. The International journal of neuroscience 2006;116:1347-1358.

Poster #129
Saturday, 9:55 am – 10:55 am

Diplopia After Strabismus Surgery for Adults with Non-Diplopic Childhood-Onset Strabismus

Jenny Y. Wang, MD; David A. Leske, MS; Sarah R. Hatt, DBO; Jonathan M. Holmes, BM, BCh

Mayo Clinic
Rochester, Minnesota

Introduction: Postoperative diplopia is reportedly rare (<1%) following strabismus surgery in adults with non-diplopic childhood-onset strabismus, but has not been studied prospectively using diplopia questionnaires and/or health-related quality of life (HRQOL) instruments.

Methods: We prospectively enrolled 79 non-diplopic adult patients with childhood-onset strabismus undergoing strabismus surgery (58% for primarily XT, 37% ET, 5% HT). Diplopia was assessed preoperatively, 6 weeks and 1 year postoperatively using a standardized diplopia questionnaire reflecting 5 frequencies ('never' to 'always') in 7 gaze positions. HRQOL was assessed with the Adult Strabismus-20 (AS-20) questionnaire, analyzed as 4 domains (self-perception, interactions, reading function, and general function) and change calculated.

Results: At 6 weeks postoperatively, 63 (81%) of 78 patients reported no diplopia in any gaze. Considering only straight ahead distance gaze, diplopia occurred in 1 (1%) patient always, 4 (5%) often, 4 (5%) sometimes, 4 (5%) rarely, and 65 (83%) never. At 1 year, 43 (84%) of 51 patients reported no diplopia in any gaze. Considering straight ahead distance gaze, diplopia occurred in 1 (2%) patient always, 1 (2%) often, 4 (8%) sometimes, 1(2%) rarely, and 44 (86%) never. For the 8 diplopic patients at 1 year, mean AS-20 scores improved (self-perception 21±27 points (P=.078), interactions12±19 (P=.13), reading function 16±17 (P=.031), and general function 11±13 (P=.094)).

Discussion: In adults with non-diplopic childhood-onset strabismus, even when postoperative diplopia occurs, HRQOL often markedly improves.

Conclusion: Postoperative diplopia appears somewhat more common than previously reported at 6 weeks and 1 year, although constant diplopia is rare.

References:

Poster #130
Saturday, 9:55 am – 10:55 am

A Prospective Observational Study of Adults with Small-Angle Hypertropia

Katherine A. Lee, MD, PhD; Trevano W. Dean, MPH; David K. Wallace, MD, MPH; Raymond T. Kraker, MSPH; Jonathan M. Holmes, MD; Amy E. Aldrich, OD; Casey J. Beal, MD; Eric R. Crouch, MD

Pediatric Eye Disease Investigator Group
Jaeb Center for Health Research, Tampa, Florida

Introduction: This prospective study evaluated outcomes of treatment for adults with small-angle hypertropias.

Methods: In a non-randomized observational study, we enrolled adults without prior strabismus surgery who had small fusible (≤10Δ) comitant hypertropias at distance and near by prism and alternate cover test, and, diplopia, reported by questionnaire1, with a frequency of 'sometimes', 'often', or 'always' in primary gaze at distance or when reading at near. Participants were enrolled if treatment with prism, exercises, or surgery was newly prescribed. The primary outcome, 'symptom success' (diplopia 'rarely' or 'never' in primary gaze at distance and when reading at near) was measured at 10 weeks and 12 months following initiation of treatment.

Results: Twenty-one participants were enrolled after prescription of prism (n=14, 67%), surgery (n=6, 29%), or exercises (n=1, 5%). After 10 weeks, 8 of 13 (62%, 95% confidence interval (CI)=31% to 86%) treated with prism and 4 of 6 (67%, 95% CI=22% to 96%) treated with surgery met criteria for symptom success. After 12 months, 4 of 8 (50%, 95% CI=16% to 84%) treated with prism and 3 of 6 (50%, 95% CI=12% to 88%) who had surgery met success criteria.

Discussion: Estimates of success are limited by small sample size and resultant wide 95% confidence intervals.

Conclusion: When assessed 12 months after initiating treatment, prism or surgery may successfully improve symptoms in adults with small angle hypertropia.

References: Holmes JM, Liebermann L, Hatt SR, Smith SJ, Leske DA. Quantifying diplopia with a questionnaire. Ophthalmology. 2013;120(7):1492-1496.

Poster #131
Saturday, 9:55 am – 10:55 am

A Novel Mechanism for Apparent Inferior Oblique Overactions (IOOA)

Lionel Kowal, FRANZCO; Shivanand Sheth, FRANZCO; Sheetal Shirke, DNB, FRCS; Robert Clark, MD

Royal Victorian Eye and Ear Hospital
Melbourne, Australia

Introduction: Over elevation of the adducted eye during versions (apparent IOOA) are seen in dissociated vertical deviations, orbital anomalies, Duane's syndrome, anti-elevation syndrome, mechanical restriction of IR, pulley heterotopia and silent sinus syndrome. We present a novel mechanism for apparent IOOA.

Methods: Multipositional MRI was performed in two patients with so-called left IOOA, both of whom presented with left hypertropia in right gaze with no significant primary position strabismus.

Results: MRI demonstrated normal extraocular muscle position in central gaze, but extorsion of the left eye pulleys in right gaze was seen in both cases. Fundus examination confirmed extorsion of left eye on right gaze. Both patients underwent a downward transposition of their left medial rectus (MR) and upward transposition of their right lateral rectus (LR) by half tendon width each. Good reduction in vertical strabismus in right gaze was achieved without any change in central gaze alignment.

Discussion: Extorsion of the pulleys in adduction can occur without any pulley extorsion in primary position. The MR moved to a higher position than the LR in adduction, which may explain the over-elevation in adduction due to upward directed vector force of the higher medial rectus.

Conclusion: Extorsion of pulleys on adduction can clinically appear as apparent IOOA. Dynamic fundus examination and dynamic MRI can be useful in diagnosis. Shifting the ipsilateral MR downwards and contralateral LR upwards can help correct the incomitance due to this mechanism.

References: 1. Kushner BJ. Multiple mechanisms of extraocular muscle 'overaction'. Arch Ophthalmol. 2006;124(5):680-8

Poster #132
Saturday, 9:55 am – 10:55 am

Sudden Onset Fourth Nerve Palsy: Clinical Characteristics and Treatment Implications

Jinali R. Diora, MD; David A. Plager, MD

Indiana University and Riley Hospital for Children at IU Health
Indianapolis, IN

Introduction: This study aims to identify clinical characteristics, etiologies and treatment implications of sudden-onset, clearly acquired cases of superior oblique palsy (SOP).

Methods: A retrospective chart review of 215 patients diagnosed with fourth nerve palsy between January 2010 and January 2018, as identified by database search of ICD-9 and 10 codes (378.53, H49.11-13) was performed. Each chart was reviewed to identify cases of definitively acquired fourth nerve palsy with a specific date of onset of acute symptoms or specific causative incident. Patients with congenital palsies or an unclear date of onset of symptoms, history of other strabismus, concomitant third or sixth cranial nerve palsies, or history of prior strabismus surgery were excluded.

Results: Of 215 patients with SOP, 23 had sudden-onset acquired palsies. There were 14 cases of unilateral palsy and 9 cases of bilateral palsy. Patients with unilateral palsy presented with vertical diplopia, while those with bilateral palsy complained of either torsional (4/9 patients) or vertical (5/9 patients) diplopia. The most common etiologies were severe trauma associated with traumatic brain injury, followed by CNS neoplasm and stroke. 15 patients underwent surgical intervention, 3 of whom required more than one surgery.

Discussion: While patients with imprecise etiology of SOP frequently present with vague symptoms, patients with acute acquired SOP complain of vertical and/or torsional diplopia.

Conclusion: Neuro-imaging should be considered in cases of acquired superior oblique palsy without a known inciting traumatic cause. Bilateral cases of acquired SOP are more challenging to manage surgically due primarily to symptomatic torsional diplopia.

References: 1) Sheeley M and Arnoldi K. Cyclotropia to differentiate longstanding and acute fourth cranial nerve palsy. Am Orthopt J. 2014;64:105-11.
2) Ivanir Y and Trobe JD. Comparing hypertropia in upgaze and downgaze distinguishes congenital from acquired fourth nerve palsies. J Neuroophthalmol. 2017;37(4):365-368.
3) Von Noorden GK, Murray E, and Wong SY. Superior oblique paralysis. A review 270 cases. Arch Ophthalmol. 1986;104(12):1771-6.

Poster #133
Saturday, 9:55 am – 10:55 am

Transposition of Plicated Horizontal Muscles

Parth R. Shah, MD; Matthew S. Pihlblad, MD

UPMC Children's Hospital of Pittsburgh
Pittsburgh, PA

Introduction: Various surgical techniques exist for simultaneous correction of a strabismus which has both horizontal and vertical components. Horizontal rectus muscle recession and/or resection may be combined with a vertical transposition (or offset).

Methods: This was a retrospective case series describing a surgical procedure for rectus muscle plication combined with vertical transposition. Minimum post-operative follow up was two months.

Results: Three children underwent unilateral rectus muscle recess– plication procedures combined with vertical transposition to treat a combined horizontal and vertical deviation. The patients had complex strabismus and general medical history. Vertical deviation measured between 8 – 15 PD. All three patients achieved the target alignment at the post-operative visit, with the vertical deviation measuring between 0 – 4 PD. There were no postoperative complications or unexpected shifts in ocular alignment during the follow up period.

Discussion: Transposition of horizontal muscles is most commonly done on recessed and resected muscles. Muscle plication is an alternate method of strengthening a muscle with the benefit of better preserving the anterior ciliary circulation compared with resections, as well as reducing the risk of a lost muscle. To our knowledge, combined rectus muscle plication with transposition has not previously been described in the literature. This novel surgical technique is particularly useful in complex and recurrent strabismus.

Conclusion: Horizontal muscle plication may be combined with a vertical transposition in the treatment of combined horizontal and vertical deviations.

References:

1. Chaudhuri Z, Demer JL. Surgical Outcomes Following Rectus Muscle Plication. A Potentially Reversible, Vessel-Sparing Alternative to Resection. JAMA Ophthalmol. 2014;132(5):579-585.
2. Huston, P. A., & Hoover, D. L. Surgical outcomes following rectus muscle plication versus resection combined with antagonist muscle recession for basic horizontal strabismus. Journal of American Association for Pediatric Ophthalmology and Strabismus {JAAPOS}. 2018;22(1):7-11.
3. Struck MC, Hariharan L, Kushner BJ, Bradfield Y, Hetzel S. Surgical management of clinically significant hypertropia associated with exotropia. J AAPOS. 2010;14(3):216-20.

Poster #134
Saturday, 9:55 am – 10:55 am

A Variation to the Rectus Plication Procedure

Sarah N. DeVaro; Gina Patel, MD; John M. DeVaro, MD

Mercer University School of Medicine
Savannah, GA

Introduction: Rectus plication has been increasingly accepted as an alternative to resection for tightening rectus muscles. However, difficulties with larger plications include a gap between the plicated tissue and its insertion, and a post-operative 'bump.' We compare the surgical outcomes of a variation to the plication procedure to standard rectus resection.

Methods: After plicating the rectus muscle by bunching it at the insertion and tying down the knot, both sutures are passed vertically through the center of the bunched muscle over which a second knot is tied, flattening the plicated muscle over its insertion. Results of such plications were retrospectively studied and compared to resections.

Results: 43 consecutive surgeries were retrospectively collected and compared. This included 17 recession/plication procedures, 6 bilateral plication procedures, and 20 recession/resection procedures. Mean age (years), pre-operative angle, post-operative angle, and follow-up (weeks) were 14.5, 29.4, 5.0, and 17.7 for plication procedures and 27.6, 35.7, 7.8, and 29.3 for resection procedures, respectively. The difference in final post-operative angle was not clinically significant between the two procedures ($p=0.28$).

Discussion: This variation produced consistent results similar to standard rectus resection. Surgical success rates were similar whether or not plication was combined with recession of the antagonist rectus muscle.

Conclusion: Tying down the plication tissue with a second knot may allow for larger plication amounts while reducing the post-operative bump and preserving the vessel-sparing and reversibility potential of plication. Surgical outcomes of this quick and easy approach to rectus plication are comparable to rectus resection.

References: •Chaudhuri Z, Demer JL. Surgical outcomes following rectus muscle plication – a potentially reversible, vessel-sparing alternative to resection. JAMA Ophthamol 2014; 132: 579-585.
•Alkharashi MS, Hunter DG. Reduced surgical success rate of rectus muscle plication compared to resection. J AAPOS 2017; 21: 201-204.
•Huston PA, Hoover DL. Surgical outcomes following rectus muscle plication versus resection combined with antagonist muscle recession for basic horizontal strabismus. J AAPOS 2018; 22(1): 7-11.

Poster #135
Saturday, 9:55 am – 10:55 am

Long Term Results of 'Sliding Shape Muscle Transposition with Plication' Operation

Birsen Gokyigit, MD; Ebru D. Aygit, MD; Asli Inal, MD; Osman B. Ocak, MD; Selcen Celik, MD; Ceren Gurez, MD; Zahid Huseyinhan, MD

University of Health Sciences Istanbul Beyolu Education and Research Eye Hospital
Istanbul / TURKEY

Introduction: The aim of this study is to present long-term results of sliding shape muscle transposition with plication operation which is delivering both vascular protection and strengthening, as well as the transposition of the muscles.

Methods: The patients' files were scanned retrospectively who had at least two years follow-up. All patients underwent complete eye examination besides motility examination both preoperatively and postoperative 1st. week, 1st. month 3rd. and 6th months and at 6-month intervals for long term follow. Cases' motility and transposition effectiveness were noted and compared with their 6th month control examination results. If there was no change or less than 10 prism diopter in their deviation it was considered as successful.

Results: There were 19 patients operated on with this novel technique. Two of the patients who underwent additional operation for their residual deviation are excluded from the study. Study Group included 17 (8 male and 9 female) patients. In study group, there were 13 operated horizontal and 8 vertical rectus muscles. No noticeable changes were recorded both in the deviations and transposition status of their last examination compared to their sixth month visit. There were no changes both in their deviations and transposition status.

Discussion: In some indications patients need both extra ocular muscle transposition procedure with resection and the blood supply protection for preventing anterior segment ischemia. This novel technique, were provided all the needs with a simple one operation for long term

Conclusion: 'Sliding shape' design extra ocular muscle transposition with plication procedure effectiveness, found stable in the long term.

References: 1. Sonwani P. et all . Plication as an alternative to resection in horizontal strabismus: A randomized clinical trial Indian J Ophthalmol. 2017 Sep;65(9):853-858.
2. Oltra EZ, Pineles SL, Demer JL, Quan AV, Velez FG. The effect of rectus muscle recession, resection and plication on anterior segment circulation in humans. Br J Ophthalmol 2015;99:556-60
3. Oltra EZ, Pineles SL, Demer JL, Quan AV, Velez FG. Surgical outcomes following rectus muscle plication: a potentially reversible, vessel-sparing alternative to resection. Br J Ophthalmol. 2015 Apr;99(4):556-60.

Poster #136
Saturday, 9:55 am – 10:55 am

Long Term Results of Lateral Rectus Disinsertion and Reattachment to the Orbital Wall in Complete Third Nerve Paralysis

Dana Garzozi, MD; Yair Morad, MD; Eran Pras, MD

Assaf Harofeh Medical Center, Tel Aviv University
Zrifin, Israel

Introduction: Complete third nerve paralysis is a complex surgical challenge mainly due to the unbalanced force of the lateral rectus which inevitably causes drift towards exotropia over the long run. Detaching the muscle from the globe and re-attaching it to the orbital wall aims to solve this problem

Methods: Five patients with complete third nerve palsy were operated during the years 2003 - 2018. All patients underwent lateral rectus disinsertion and re-attachment to the orbital wall, together with superior oblique tenectomy. Medial rectus resection with/without superior rectus resection was also done in order to achieve orthophoria on the operating table.

Results: All patients achieved near orthophoria alignment that was cosmetically acceptable. In four patients some residual abduction and adduction movements were noted. These surgical results were stable during a follow-up period of 5-15 years.

Discussion: Lateral rectus disinsertion and reattachment to the orbital wall, together with superior oblique tenectomy, abolish any abducting or depressing force on the globe. If ortho alignment is achieved on the operating table, it usually remain stable thereafter. Some abducting and adducting force is still generated by the lateral rectus extra-muscular attachments and by the weak medial rectus that has no counter balance force.

Conclusion: Lateral rectus detachment and re-attachment to the orbital wall is an excellent surgical choice in patients with complete third nerve palsy. The surgical results are remarkably stable over a long follow-up period.

References: Morad Y, Kowal L, Scott AB. Lateral rectus muscle disinsertion and reattachment to the lateral orbital wall. Br J Ophthalmol. 2005 Aug;89(8):983-5.

Poster #137
Saturday, 9:55 am – 10:55 am

Bilateral Full Tenectomy of the Superior Oblique Muscle for the Treatment of A-Pattern Strabismus

Iara Debert, MD, PhD; Ana L. Darcie, MD; Mariza Polati, MD, PhD

University of Sao Paulo
Sao Paulo, Brazil

Introduction: Superior oblique full tenectomy close to the scleral insertion was originally described as a treatment for moderate A-pattern strabismus. The purpose of this study is to evaluate the efficacy of this technique for A-patterns of all magnitudes in a large retrospective clinical record review.

Methods: The clinical records of patients with A-pattern strabismus associated with bilateral superior oblique overaction who underwent bilateral superior oblique 6.0 mm full tenectomy close to the scleral insertion, from 2001 to 2017, were retrospectively reviewed.

Results: A total of 102 patients were included. Preoperative A-pattern deviation was 21 ± 9 PD, with a postoperative pattern collapse of 18 ± 10 PD. The change in A-pattern was significantly correlated with the preoperative pattern deviation ($r = 0.70$ $p < 0.001$). Of patients with A-pattern >/= 25 PD, the preoperative A-pattern was 31 ± 7 PD, with a postoperative pattern collapse of 27 ± 9 PD. 76% of patients with A-pattern < 25 PD and 72% of patients with A-pattern >/= 25 PD had pattern correction to <10 PD. On average, 89% of the preoperative A-pattern was corrected in patients with pattern < 25 PD and 86% in patients with pattern >/= 25 PD.

Discussion: Bilateral superior oblique full tenectomy proved to be an effective and self-adjusting procedure for A-pattern strabismus associated with superior oblique overaction. Larger preoperative A-patterns did not show a significant trend toward larger residual postoperative deviations compared to smaller preoperative A-patterns.

Conclusion: A uniforme dose of bilateral superior oblique full tenectomy collapses A-patterns of all magnitudes.

References: 1. Souza-Dias, C., Uesugui, C. F. Efficacy of different techniques of superior oblique weakening in the correction of the 'A' anisotropia. J Pediatr Ophthalmol Strabismus. 1986; 23: 82-86.
2. Prieto-Diaz, J. Management of superior oblique overaction in A-pattern deviations. Graefes Arch Clin Exp Ophthalmol. 1988; 226: 126-131.
3. Archer, S. M. Why strabismus surgery works: the legend of the dose-response curve. J AAPOS. 2018; 22:1.e1-1.e6.

Poster #138
Saturday, 9:55 am – 10:55 am

Does It Work? The Inferior Oblique Anterior Nasal Transposition (IOANT) - Procedure with Short Tag Noose Adjustable Sutures in Treating 4th Nerve Palsy with Large Angle Deviation

Jon Peiter Saunte, MD; Tobias Torp-Pedersen, MD, PhD; Claes Lønkvist, MD

Ophthalmology Department Rigshospitalet, Glostrup
Copenhagen, Denmark

Introduction: In 4th nerve palsies, vertical deviations of more than 15 PD may require two or more muscle surgeries to correct. We wanted to investigate the effect of a single muscle IOANT procedure for ≥ 15PD vertical deviation or ≥+3 inferior oblique overaction (IOOA).

Methods: Retrospective chart review of last 10 months. We collected data on change in vertical deviation, IOOA and effect on head-tilt after IOANT procedure. In this procedure, the inferior oblique muscle is moved nasally and sutured in the lower nasal quadrant to sclera[1].

Results: IOANT was performed in 13 patients. We excluded one patient with bilateral IOANT, leaving 12 unilateral cases (age 2-70y, 8 males) for study inclusion. One patient had a previous inferior oblique transposition which was transformed to an IOANT. In this case we included vertical deviation and IOOA from before the primary procedure. IOANT changed the vertical deviation from mean 23 PD (SD=6.6PD, range [12,35]) to mean 4 PD (SD=3.6 PD, range [-1, 10]), and reduced the vertical deviation mean 19 PD (SD=7.5 PD, range [9,35]). IOOA was documented in 10 of 12 patients, and was reduced from mean +2.7 (SD=0.9, range [+1, +4]) to man +0.1 (SD=0.5, range [-0.5, +1]), and reduced IOOA 2.5 (SD=1.1, range [+1, +4]). Head posture was recorded pre- and postoperatively in seven patients, and improved in all of these cases. All IOANT procedures included short tag noose adjustable suture, but none required adjustment.

Discussion: In large angle 4th nerve palsies, two or more muscles needs to be operated on to align the eyes. Graded recession of the ipsilateral inferior oblique may reduce the vertical deviation up to 15 PD, and an added recession of the contralateral inferior rectus may be added. We found promising effects on vertical effect of up to 30 PD after one IOANT. The IOOA improved in all patients, and excyclotorsion and head-tilt was reduced.

Conclusion: In 4th nerve palsies, IOANT with an addded adjustable suture is a safe one-muscle-procedure and may correct vertical deviations of up to 30 PD, reducing abnormal headtilt and IOOA, and correct excyclotorsion.

References: 1. Anterior and nasal transposition of the inferior oblique muscles in patients with missing superior oblique tendons.Hussein MA, Stager DR Sr, Beauchamp GR, Stager DR Jr, Felius J. J AAPOS. 2007 Feb;11(1):29-33.

Poster #139
Saturday, 9:55 am – 10:55 am

Torsional Incomitance After Asymmetrically Adjusted Harada-Ito Procedures in an Attempt to Correct Small Co-Existing Vertical Deviations in Bilateral Fourth Nerve Palsy

Mireille N. Jabroun, MD; Justin D. Marsh, MD; David L. Guyton, MD

Wilmer Eye Institute, Johns Hopkins Hospital
600 N. Wolfe Street, Baltimore, MD 21287-9028

Introduction: Adjustable bilateral Harada-Ito procedures have been described with asymmetric adjustment sometimes used for correction of co-existing vertical misalignment.1 Our aim is to investigate the causes of post-operative diplopia and to illustrate a hazard in using Harada-Ito procedures for the simultaneous correction of vertical and torsional deviations.

Methods: Retrospective review of patients who underwent bilateral Harada-Ito procedures for bilateral fourth nerve palsy between 1980 and 2018. Cases with operation on any other oblique or vertical rectus muscle were excluded. Pre-op and post-op examinations and Lancaster Red-Green Plots2 (LRG) were recorded.

Results: Nine cases were identified. At 8 weeks post-op, 5 were diplopia-free. Of the 4 with diplopia, one had a LRG revealing an overcorrection with consecutive intorsion and another had undercorrection. A significant torsional incomitance was noted in the other 2 patients, with torsional incomitance defined as an incomitant eye movement pattern with the patient perceiving intorsion in upgaze and extorsion in downgaze. Asymmetric adjustment with weakening of one superior oblique tendon and tightening of the other was noted in those two cases. None of the 7 other patients had the same type of asymmetric adjustment.

Discussion: Torsional incomitance can be caused by incomplete correction of extorsion in down gaze with an induced Brown syndrome in upgaze in cases of asymmetric adjustment of Harada-Ito procedures.

Conclusion: Asymmetric adjustment of Harada-Ito procedures in an attempt to correct co-existing vertical misalignment may result in postoperative diplopia by creating a new pattern of torsional incomitance that is surgically challenging to correct.

References: 1.. Guyton DL. Strabismus: inferior oblique weakening procedures, superior oblique tenotomy, superior oblique strengthening procedures, and transposition procedures. In: Gottsch JD, Stark WJ, Goldberg MF, eds. Rob & Smith's Operative Surgery: Ophthalmic Surgery. 5th ed. New York: Oxford University Press; 1999:92–100. 2. Christoff A, Guyton DL. The Lancaster red-green test. Amer Orthoptic J 2006; 56: 157-165.

Poster #140
Saturday, 9:55 am – 10:55 am

Comparison of Unilateral Recession or Resection of the Inferior Oblique Muscle During Anterior Transposition for Treatment of Asymmetric Vertical Strabismus

Marlo Galli, CO; Gregg T. Lueder, MD

Washington University School of Medicine
Saint Louis, MO

Introduction: Dissociated vertical deviation (DVD) and overelevation in adduction (OEAd) occur frequently in children with infantile strabismus. This study evaluated the efficacy of combining bilateral inferior oblique muscle anterior transposition (IOAT) with unilateral recession or resection of the muscle for patients with asymmetric DVD and OEAd.

Methods: Retrospective review of 29 patients with infantile strabismus and asymmetric vertical deviations for whom unilateral recession (19 patients) or resection (10 patients) of the inferior oblique muscle was performed in addition to bilateral IOAT. Surgery was considered successful if patients had 10 prism diopters or less of DVD and/or resolution of the OEAd.

Results: Four of ten patients (40%) had good results when the inferior oblique muscle was resected in the eye with the larger deviation. Thirteen of nineteen patients (68%) had good results when the inferior oblique muscle was recessed in the eye with the smaller deviation.

Discussion: IOAT is an effective treatment for patients with DVD and OEAd. If the vertical strabismus is asymmetric, unilateral recession of the inferior oblique muscle in the eye with the smaller deviation may increase the efficacy of the procedure.

Conclusion: For patients with asymmetric vertical deviations associated with infantile strabismus who are treated with bilateral IOAT, unilateral recession of the inferior oblique muscle in the eye with the smaller deviation is more effective than unilateral resection of the inferior oblique muscle in the eye with the larger deviation .

References: 1. Bothun ED, Summers CG. Unilateral inferior oblique anterior transposition for dissociated vertical deviation. JAAPOS. 2004; 8:259-63.
2. Mims JL, Wood RC. Bilateral anterior transposition of the inferior obliques. Arch Ophthalmol. 1989;107:41-4.
3. Engman JH, Egbert JE, Summers CG, Young TL. Efficacy of inferior oblique anterior transposition placement grading for dissociated vertical deviation. Ophthalmology. 2001;1008:2045-50.

Poster #141
Saturday, 9:55 am – 10:55 am

Combined Inferior Rectus Recession and Lower Eyelid Retractor Release in Thyroid Eye Disease

Lindsay M. De Andrade, MD; Federico G. Velez, MD; Daniel B. Rootman, MD; Robert A. Goldberg, MD; Bunyada Putthirangsiwong, MD; Toshiaki Goseki, MD; Joseph L. Demer, MD, PhD; Stacy L. Pineles, MD

Stein Eye Institute
Los Angeles, California

Introduction: Eyelid retraction and hypotropia are common in thyroid eye disease (TED), but inferior rectus (IR) recession causes or increases lower eyelid retraction that in turn aggravates dry eyes. Standard dogma including the AAO Basic and Clinical Science Course (BCSC) holds that strabismus surgery should precede eyelid surgery.

Methods: Review of all combined IR recession and lower lid retractor release surgeries performed at a single institution in TED patients from 2014-2018. Alignment, lid positions, symptoms, and reoperations were recorded.

Results: Ten patients underwent IR recession (mean 5.2mm, range 3-7.5mm) combined with lower lid retractor release performed en glove via lateral rhytid skin incision. Average age was 60.4 years (range 41-83); 7 patients were female. Pre-operative hypotropia averaged 24 △ (range 4-50) in central gaze and 24 △ (range 2-40) in infraversion. Post-operatively, mean hypotropia improved significantly to 2.1 △ (range 0-8, p=0.0005) in central gaze and 1.6 △ (range 0-8 p=0.001) in infraversion. Comparison of pre and post operative photographs showed no significant increase in lower lid retraction at final follow up visit.

Discussion: Despite large IR recession there was no significant worsening of lower eyelid retraction when combined with lower lid retractor release. Contrary to the BCSC, retractor release may be performed concurrently with IR recession to correct or avert lower lid retraction in TED. This avoids return for staged eyelid surgery following strabismus surgery, and minimizes duration of corneal exposure following recession.

Conclusion: It is reasonable to concurrently release the lower eyelid retractors when the IR is recessed to treat hypotropia due to TED.

References: Basic and Clinical Science Course Section 7: Orbit, eyelids and lacrimal system. San Francisco, CA: American Academy of Ophthalmology; 2014:47-55.
Bothun ET, Scheurer RA, Harrison AR, Lee MS. Update on thyroid eye disease and management. Clin Ophthalmol 2009; 3:543-551.
Myer DR, Simon JW, Kansora M. Primary infratarsal lower eyelid retractor lysis to prevent eyelid retraction after inferior rectus muscle recession. Am J Ophthalmol 1996;122:331-339.

Poster #142
Saturday, 9:55 am – 10:55 am

The Outcome of Patients with Abnormal Head Position Due to Nystagmus treated with The Anderson-Kestenbaum Procedure

Alina V. Dumitrescu, MD; Hannah Pope; Aishwarya J. Kothapalli; Deborah V. Dawson, PhD; Scott A. Larson, MD; Richard J. Olson, MD; Pavlina S. Kemp, MD; Arlene V. Drack, MD

University of Iowa
Iowa City

Introduction: The purpose of this study is analyzing the long-term outcomes of the Anderson-Kestenbaum procedure (AKP).

Methods: Retrospective chart review of patients surgically treated with AKP for abnormal head posture (AHP) due to nystagmus over 30 years. Optimal outcome was defined as complete resolution or AHP less than 10 degrees at the last exam.

Results: 48 charts met the inclusion criteria. 92% of the patients exhibited some improvement in the AHP at the last follow-up, but only 52% had an optimal outcome with only 23% having no head posture postoperatively.
A trend of decreased frequency of improvement in AHP for those who had the procedure after the age of 145 months was noted. There also was a decrease in rates of optimal outcome as the length of follow up time increased. Average follow up was 74 months.
Of the patients who still had AHP, 59% had the same head position, and 41% developed a different head position. 21 % of patients developed new strabismus after the procedure.
Patients with head positions along the horizontal axis were the most common and had the highest rate of optimal outcomes.

Discussion: Setting realistic expectations for the patient is the most important recommendation from this study.

Conclusion: Overall the number of patients treated with this procedure was small. While improvement of AHP is likely, a certain degree of head position will still be left after the procedure, and a new head position or strabismus could develop. Age seems to be the single most important factor identified in this study.|

References: 1. Calhoun, J. H., & Harley, R. D. (1973). Surgery for abnormal head position in congenital nystagmus. Transactions of the American Ophthalmological Society, 71, 70-83; discussion 84-7.
2. Campos, E. C., Schiavi, C., & Bellusci, C. (2003). Surgical management of anomalous head posture because of horizontal gaze palsy or acquired vertical nystagmus. Eye, 17(5), 587-592. https://doi.org/10.1038/sj.eye.6700431
3. Nelson, L. B., N-Mulvey, L. D. E., Calhoun, J. H., Harley, R. D., & Keisler, M. S. (1984). Surgical management for abnormal head position in nystagmus: The augmented modified Kestenbaum procedure. British Journal of Ophthalmology, 68(11), 796-800. https://doi.org/10.1136/bjo.68.11.796

Poster #143
Saturday, 9:55 am – 10:55 am

Novel Classification of Strabismus Coexisting with Infantile Nystagmus Syndrome: Clinical Characteristics and Surgical Outcomes

Yuxi Zheng, BS; Derick G. Holt, MD, PhD; James J. Law, BS; David G. Morrison, MD; Sean P. Donahue, MD, PhD

Vanderbilt Eye Institute
2311 Pierce Ave, Nashville, TN 37232

Introduction: Kestenbaum described a procedure to correct the abnormal head positioning (AHP) that can be associated with infantile nystagmus syndrome (INS). Surgical planning must take any coexisting strabismus into account. We categorized strabismus that is present in children with INS into concordant, discordant, and independent depending on whether surgery on the fixating eye for the AHP improves, worsens, or has no effect on the strabismus.

Methods: Retrospective chart review of Kestenbaum procedures from 1995-2018. Cases of coexisting AHP and strabismus with more than 2 months of follow-up were reviewed.

Results: Of 150 Kestenbaum procedures, 33 had coexisting strabismus (24 concordant, 7 discordant, and 2 independent strabismus). Mean follow-up was 50 months. At 2 months post-op, 100% had resolved AHP (</=10 degrees) and 73% had resolved primary gaze strabismus (</=10 Prism-Diopters). A second procedure was performed on 10 patients (mean 1.5 years later); 29% of patients with concordant strabismus underwent reoperation while 43% with discordant strabismus underwent reoperation. 88% improved both AHP and strabismus ($p<0.001$); 100% had improved AHP compared to baseline.

Discussion: Surgical dosing for the Kestenbaum procedure should be modified to correct for strabismus by decreasing dosage in the non-fixating eye if concordant or decreasing dosage in the fixating eye if discordant. Our results suggest that those with discordant strabismus are more difficult to correct with surgery.

Conclusion: Classifying patients with AHP and strabismus into concordant and discordant types and modifying surgery based on this classification produces acceptable outcomes.

References:

Poster #144
Saturday, 9:55 am – 10:55 am

The Psychological Effects of Infantile Nystagmus

Maria Theodorou, FRCOphth; Kelly A. MacKenzie, MSc

Moorfields Eye Hospital NHS Foundation Trust
London, UK

Introduction: We aim to evaluate the impact of nystagmus on the mood and quality of life (QoL) in adult patients at a tertiary referral center.

Methods: Consecutive patients with infantile nystagmus looking for treatment options in adulthood were prospectively recruited. All completed a questionnaires measuring anxiety and depression (Hospital Anxiety & Depression Scale1 (HADS)), quality of life (Nystagmus-specific QoL Questionnaire2 (NYS-29)) and social support (Multidimensional Scale of Perceived Social Support (MSPSS))3.

Results: 40 questionnaires analysed. The mean best corrected binocular visual acuity (BCVA) 0.47 LogMAR (SD 0.265). The majority of the group were made up of adults with sensory abnormalities (68%) and idiopaths (32%). 10.5% experienced potential clinically identifiable levels of anxiety, and 9.1% clinical depression. The overall QoL score (0 worst - 100 best score) was 64.8 (SD 22). Physical and environmental subscale indicating a wider variance (mean 61.6, SD 29) compared to the personal and social subscale.

Discussion: There was a medium, negative correlation with greater levels of visual impairment being associated with lower physical and environmental subscale score (r=-0.443, n=36, p= 0.001). Those with less perceived social support from friends (r=-0.360, n=36, p=0.05) compared to family or a significant other, experienced higher levels of depression.

Conclusion: Almost 20% of patients with infantile nystagmus have a potential diagnosis of a mental health disorder with a wide variance of quality of life, which may be overlooked during a standard clinical assessment. Care must be taken to counsel patients looking for treatment to further enhance vision to ensure expectations are in line with expected clinical outcome.

References: 1. McLean RJ, Maconachie G, Gottlob I, et al. The Development of a Nystagmus-Specific Quality-of-life. Ophthalmol. 2016;123(9):2023-7.
2. Zigmond AS, Snaith P. The hospital anxiety and depression scale. Acta Psychiatr Scand. 1983;67:361-370.
3. Zimet GD, Dahlem NW, Zimet SG, et al. The Multidimensional scale of perceived social support. J pers assess. 1988;52:30.

Poster #145
Saturday, 9:55 am – 10:55 am

Clinical and Electrophysiological Outcomes After Eye Muscle Surgery in 81 Adults with Infantile Nystagmus Syndrome (INS)

Richard W. Hertle, MD; Molly Curtiss; Isabel Ricker; Alyssa Gehring

Akron Childrens Hospital
Akron Ohio

Introduction: The purpose of this report is to characterize the effects of eye muscle surgery on patients > 18 years of age with INS.

Methods: This is a prospective, interventional case series analysis of clinical and electrophyisological data after eye muscle surgery in adults with INS. Outcomes included: 1) routine demography and surgical procedure 2) binocular corrected visual acuity in the null position (BVA), 3) anomalous head posture (AHP), 4) contrast sensitivity function (CS), 5) Strabismic Deviation (SD) and 6) the nystagmus acuity function (NAFX). All patients were followed at least 12 months. Parametric and non-parametric statistical analysis of outcome measure were perfomed.

Results: Patients ranged from 18-72 yrs (ave 36.6) are included in this report. 63% were male. Follow up ranged from 13-78 mos (ave 33). Associated systemic and ocular system deficits included albinism (25%), amblyopia (24%), optic nerve dysplasia and/or retinal dystrophy (24%). 61% had a significant refractive error, 44% had an AHP, 44%% had a periodic component, 70% had strabismus. There were 9 consistent surgical procedures used with the most common being that for a horizontal head posture plus strabismus (22%). There were no serious surgical complications. Group means improved in BVA ($p<0.05$), CS ($P<0.01$), SD ($p<0.05$), AHP ($p<0.001$), and NAFX measures ($p < 0.01$). There were 12 (15%) reoperations for recurrent head posturing and or new strabismus.

Discussion: Adults with INS are characteristically similar to their childhood counterparts.

Conclusion: Adults with INS show sustained improvement in many afferent and efferent measures of visual function after initial eye muscle surgery.

References: 1. Singh A, Ashar J, Sharma P, Saxena R, Menon V.A prospective evaluation of retroequatorial recession of horizontal rectus muscles and Hertle-Dell'Osso tenotomy procedure in patients with infantile nystagmus with no definite null position.|J AAPOS. 2016 Apr;20(2):96-9
2. Dubner M, Nelson LB, Gunton KB, Lavrich J, Schnall B, Wasserman BN.Clinical Evaluation of Four-Muscle Tenotomy Surgery for Nystagmus.|J Pediatr Ophthalmol Strabismus. 2016 Jan-Feb;53(1):16-21.
3. Hertle RW, Yang, D, Ma, L, Gao, J, Madhavi, M, Roberts T, Otaibi, S. Visual rehabilitation of patients with oculocutaneous albinism Type I (OCA1): Results in 85 patents. New Frontiers in Ophthalmology, 2017:3; 1-14.

Poster #146
Saturday, 9:55 am – 10:55 am

Two-Muscle Extended Recession Surgery for in Infantile Nystagmus Syndrome with Face Turn

Ping Wang, MD; Dongsheng Yang, PhD

Shandong Bright eye hospital
6662 erhuan south road shizhong district Jinan Shongdong China

Introduction: To evaluated the effects of two-muscle extended recession surgery to reduce abnormal head posture(APH) in children with infantile nystagmus syndrome;

Methods: Twenty-two children who diagnosed with infantile nystagmus syndrome received two-muscle extended recession surgery for horizontal head turn (HT) were included in the study. Each patients were evaluated before and 3 months after operation for HT, monocular visual acuity (VA), binocular vision (BV), eye movement by horizontal version range, convergence range by near point, ocular alignment and EMR(eye movement recording).

Results: 1. Of the 22 patients aged 1–16y(mean 6.98+3.65y), 12 had AHP to the left and 10 to the right; 15 male and 7 female ; the head turn angle was 15~50PD(mean 34.56PD), and a total of 15~29 mm horizontal rectus recession (medial rectus recession millimeter range 8–13 mm, lateral rectus recession millimeter range 10~16mm) were done to reduce the head turn angle according to the age, axial length and angle;2. Postoperatively, residual head turn angle ranged from 0 to 15PD, fourteen patients without obviously residual head turn angle, four patients with residual head turn angle less than 10PD,four patients with residual head turn angle larger than 10PD received corrective press-on prism and no patients need another second surgery; 3. Postoperatively, the average null zone acuity was 0.76 in logMAR preoperatively, which improved significantly to 0.52 in logMAR postoperatively (P = .023); Data on binocular fusion were available for 13 patients, none of the patients having fusion preoperatively lost;4.Two patients with transient small angle esotropia(< 10PD) but disappeared 3 months later, two patients with exotropia(< 15PD) without necessary for second surgery, PDone 8y old boy with 30PD exotropia who was underdone second surgery and was found the medial rectus muscle slipping; 5. No patient with eye movement disability postoperatively; Convergence function is available in all patients with near point convergence test; 12 patients who showed a motility deficit in early postoperative period but all disappeared after 3 months observation; 6. EMR showed that all patients with ocular oscilliation wave-form improvement at the primary gaze position in frequency and amplitude compared to preoperative recording(p=0.02,p=0.05).

Discussion: 1. Two-muscle extended recession surgery is as effective as the four muscle surgery in INS with horizontal AHP;
2. Two-muscle extended recession surgery without any severe postoperative complications.

Conclusion: Two-muscle extended recession surgery is an effective and safe surgery for INS with horizontal AHP, and further clinical data should be done for long term following up and conclusion.

References: 1.Ritesh Gupta, Pradeep Sharma and Vimala Menon. A Prospective Clinical Evaluation of|Augmented Anderson Procedure for Idiopathic Infantile Nystagmus.J AAPOS 2006;10:312-317;
2.Abbas Bagheri, Azadeh Farahi, and Shahin Yazdani. The Effect of Bilateral Horizontal Rectus Recession on Visual Acuity, Ocular Deviation or Head Posture in Patients with|Nystagmus.J AAPOS 2005;9:433-437
3.Alio JL, Chipont E, Mulet E, De La Hoz F. Visual performance after|congenital nystagmus surgery using extended hang back recession of the|four horizontal rectus muscles. Eur J Ophthalmol 2003;13:415-23.

Poster #147
Saturday, 9:55 am – 10:55 am

Case Series: Horizontal Transposition of Vertical Recti for Idiopathic Nystagmus Syndrome with Head Tilt

Alexander H. de Castro-Abeger, MD, MBA; Nancy Benegas, MD; Burt Kushner, MD; Sean P. Donahue, MD, PhD

Vanderbilt University Children's Hospital
Nashville, Tennessee

Introduction: Patients with idiopathic nystagmus syndrome often develop an abnormal head position. A horizontal face turn can be treated with the augmented Kestenbaum procedure, while patients with a chin up or chin down position can be treated with surgery on the vertical recti and/or oblique muscles. Although rare, some patients may have a head tilt with no face turn. We report five patients who underwent horizontal transposition of the vertical rectus muscles to correct a head tilt.

Methods: Retrospective chart review. Surgery consisted of either a 7mm or full tendon width transposition of the vertical rectus muscles of each eye to induce cyclotorsion in the direction of the head tilt. The presenting clinical histories, measurements and surgical outcomes were reviewed.

Results: Of the 5 patients, 2 had previous horizontal face turns that were corrected with an augmented Kestenbaum procedure and later developed a head tilt, while 3 patients presented primarily with a head tilt. Age at surgery ranged from 5 to 8 years. Initial tilts were measured between 20-45 degrees. Post operatively, 4 out of 5 patients had near complete (0-5 degree) resolution of their tilt. One patient had a persistent 5 degree head tilt and a small chin up that was nullified with vertical prisms in spectacles.

Discussion: Von Noorden et al described the transposition of the vertical rectus muscles for incyclotorsion and excyclotorsion. Applying the same principle for head tilts where at least 2 vertical muscles were transposed horizontally, cyclotorsions were induced to nullify abnormal head tilts for patients with nystagmus.

Conclusion: Transposition of the vertical rectus to induce cyclotorsion in the direction of the head tilt improves abnormal head titling in patients who have idiopathic nystagmus syndrome.

References: 1. Nelson LB, N-Mulvey LDE, Calhoun JH, Harley RD, Keisler MS. Surgical management for abnormal head position in nystagmus: The augmented modified Kestenbaum procedure. Br J Ophthalmol. 1984;68(11):796-800. doi:10.1136/bjo.68.11.796.
2. Lueder GT, Galli M. Oblique muscle surgery for treatment of nystagmus with head tilt. J AAPOS. 2012;16(4):322-326. doi:10.1016/j.jaapos.2012.05.005.
3. Von Noorden GK, Jenkins RH, Chu MW. Horizontal transposition of the vertical rectus muscles for cyclotropia. Am J Ophthalmol. 1996;122(3):325-330. doi:10.1016/S0002-9394(14)72058-6.

Poster #148
Saturday, 9:55 am – 10:55 am

Correlation Between Spectral Domain Optical Coherence Tomography (SD-OCT) and Long-Term Vision Loss in Children with Papilledema

Michael J. Wan, MD, FRCSC

The Hospital for Sick Children, University of Toronto
Toronto

Introduction: The aim was to investigate the correlation between spectral domain optical coherence tomography (SD-OCT) parameters and long-term visual impairment in children with papilledema.

Methods: The medical records of pediatric patients with papilledema were reviewed. The primary outcome measure was the correlation of SD-OCT parameters with long-term visual impairment (defined as BCVA </= 20/40 and/or significant visual field loss at final follow-up).

Results: There were 51 children (102 eyes) with papilledema. Mean age on presentation was 11.7 ± 3.6 years and mean follow-up was 16.9 ± 15.3 months. Mean retinal nerve fiber layer (RNFL) thickness was 236.1 µm at diagnosis and 96.3 µm after resolution. The average change in RNFL thickness in all patients was a decrease of 139.8 µm. Final mean and minimum ganglion cell-inner plexiform layer (GC-IPL) thickness were 79.8 µm and 76.7 µm, respectively. At final follow-up, 24 eyes (13 patients) had evidence of long-term visual impairment. In comparison to eyes with normal visual function at final follow-up, eyes with long-term visual impairment had higher mean RNFL thickness at diagnosis (288.5 vs 219.9 µm, p = 0.01), higher mean change in RNFL from diagnosis to final follow-up (196.3 vs 122.4, p= 0.006), lower final mean GC-IPL thickness (74.2 vs 81.5 µm, p = 0.007), and lower mean minimum GC-IPL thickness (69.2 vs 78.9 µm, p = 0.003).

Discussion: SD-OCT parameters are significantly correlated with long-term vision loss in children with papilledema.

Conclusion: SD-OCT can become a useful tool in the prognosis and monitoring of papilledema in children.

References: 1. Kardon R. Optical coherence tomography in papilledema: what am I missing? Journal of neuro-ophthalmology : the official journal of the North American Neuro-Ophthalmology Society. Sep 2014;34 Suppl:S10-17.
2. Chen JJ, Thurtell MJ, Longmuir RA, et al. Causes and Prognosis of Visual Acuity Loss at the Time of Initial Presentation in Idiopathic Intracranial Hypertension. Investigative ophthalmology & visual science. Jun 2015;56(6):3850-3859.
3. Gu S, Glaug N, Cnaan A, Packer RJ, Avery RA. Ganglion cell layer-inner plexiform layer thickness and vision loss in young children with optic pathway gliomas. Investigative ophthalmology & visual science. Mar 10 2014;55(3):1402-1408.

Poster #149
Saturday, 9:55 am – 10:55 am

The Relationship Between Optic Canal Size and Severity of Papilledema in Children with Intracranial Hypertension

Anastasia A. Alex, MD; Hilliary E. Inger, MD; Hersh Varma, MD; Catherine O. Jordan, MD; Shawn C. Aylward, MD; Jeremy Jones, MD; David L. Rogers, MD

Nationwide Childrens Hospital
Columbus, OH

Introduction: Bony optic canal size has been proposed to affect the dynamics of cerebrospinal fluid pressure from the cranium to the subarachnoid space within the optic nerve sheath. This may contribute to variations in clinically observed optic nerve edema (ONE) in patients with intracranial hypertension (IH). The purpose of this study was to determine if a relationship exists between optic canal size and the grade of clinically observed ONE in pediatric IH patients.

Methods: Presenting ophthalmologic exam information and the results of intracranial imaging were collected retrospectively for 35 pediatric IH patients (70 eyes). Volumetric T1 magnetic resonance imaging (MRI) brain scans were reviewed by a neuroradiologist who was masked to the ONE grades. Cross-sectional area (CSA) of the narrowest region of the optic canal was measured using OSIRIX software. Spearman correlation and ANOVA testing was performed to study the relationship between CSA and ONE grade.

Results: Optic canal CSA and ONE were not significantly correlated ($r=0.02$, $p=0.84$). There were no significant differences among average optic canal CSA when compared according to ONE grade ($F(5,62) = 1.22$, $p=0.31$).

Discussion: Although an association of the optic canal CSA and ONE grade has been reported previously in adults with IH, there was no significant relationship found in our study of pediatric IH patients.

Conclusion: Our study suggests that the optic canal size in children with IH may not be associated with the severity of papilledema observed on physical exam.

References: Bidot S, Clough L, Saindane AM, Newman NJ, Biousse V, and Bruce BB. The optic canal size is associated with the severity of papilledema and poor visual function in indiopathic intracranial hypertension.||Hayreh SS. Pathogenesis of optic disc edema in raised intracranial pressure. Prog Retin Eye Res. 2016 Jan;50:108-114.
Saindane AM, Bruce BB, Riggeal BD, Newman NJ, and Biousse V. Association of MRI findings and visual outcome in idiopathic intracranial hypertension.

Poster #150
Saturday, 9:55 am – 10:55 am

Utility of the OCT Lazy V Sign in Diagnosing Optic Nerve Edema in a Pediatric Population

Hilliary E. Inger, MD; Hersh Varma, MD; Mea A. Weaver, BS; Catherine O. Jordan, MD; Rachel E. Reem, MD; Mary Lou McGregor, MD; Shawn C. Aylward, MD; David L. Rogers, MD

Nationwide Children's Hospital
Columbus, OH

Introduction: A subretinal hyporeflective space between the sensory retina and the RPE/choriocapillaris, known as the 'lazy V', has been described on optical coherence tomography (OCT) in patients with optic nerve edema (ONE). The purpose of this study is to determine if the lazy V can distinguish pediatric ONE from optic nerve head drusen (ONHD) and determine if it is visible at all grades of ONE.

Methods: Spectral-domain OCT optic nerve scans of 83 eyes with ONE and 117 eyes with ONHD were collected retrospectively. Four masked pediatric ophthalmologists independently reviewed the images for the presence of the lazy V.

Results: The sensitivity and specificity of the lazy V to differentiate ONE from ONHD were 54% and 63%, respectively. The average grade of ONE was 2.89 +/- 0.69 when a majority of readers agreed that the lazy V was present (group 1), 1.44 +/- 0.72 when a majority agreed it was absent (group 2), and 2.20 +/- 1.00 when the response was mixed (group 3). The average ONE grade was significantly higher between groups 1 and 2 (p=0.00), and 3 and 2 (p=0.049).

Discussion: The lazy V sign was inconsistently identified when clinical edema was present, and as a result, it cannot be relied upon to rule out ONE. We were unable to unanimously identify the lazy V even with more severe ONE.

Conclusion: The presence of the lazy V was not a reliable measure to confirm all grades of ONE or differentiate ONE from ONHD in our study.

References: 1. Savini G, Bellusci C, Carbonelli M, et al. Detection and quantification of retinal nerve fiber layer thickness in optic disc edema using stratus OCT. Arch Ophthalmol 2006;124:1111-1117.
2. Johnson LN, Diehl ML, Hamm CW, et al. Differentiating optic disc edema from optic nerve head drusen on optical coherence tomography. Arch Ophthalmol 2009;127(1):45-49.

Poster #151
Saturday, 9:55 am – 10:55 am

Influence of Optic Nerve Appearance on Final Visual Outcome in Pediatric Patients with Idiopathic Intracranial Hypertension (IIH)

Jason H. Peragallo, MD; Jonathan A. Micieli, MD; Caroline Vasseneix, MD; Richard J. Blanch, FRCOphth, PhD; Damian E. Berezovsky, MD; Nancy J. Newman, MD; Valerie Biousse, MD; Beau B. Bruce, MD, PhD

Emory University
Atlanta, GA

Introduction: In adult IIH patients, Frisén grade, but not optic disc hemorrhages (ODH) or cotton wool spots (CWS), was an independent risk factor for worse visual outcomes, allowing for early intervention. We investigated these variables in pediatric IIH (PIIH) patients.

Methods: 50/160 PIIH patients (100 eyes) ≤16 years seen within 30 days of lumbar puncture/medical treatment, with fundus photographs at presentation. Patients' characteristics, visual acuity (VA) and visual field grade (VFG)[1] were recorded. Fundus photographs graded by 3 independent reviewers used a standardized protocol for ODH/CWS,[2] and papilledema grade.[3] Multivariable linear and logistic mixed models evaluated the association between Frisén grade, ODH, CWS and visual outcomes controlling for confounding variables.

Results: 41/100 (41.0%) eyes had ≥1ODH, 27/100 (27.0%) eyes had ≥1CWS, 20/100 (20.0%) had both ODH and CWS. Controlling for Frisén grade,[3] BMI, race, and gender, the presence of ODH/CWS was not associated with worse VA and VFG at initial presentation or final follow-up. Severe ODH at presentation were associated with a worse VA and VFG at initial presentation, but not final follow-up ($p<0.03$). Severe CWS at presentation were associated with worse VFG at final follow-up ($p=0.007$). When controlling for age, BMI, gender, and race, Frisén grade correlated with worse VFG at presentation ($p=0.01$) and worse final VA when controlling for initial VA ($p=0.02$).

Discussion: Frisén grade was the only independent variable associated with worse visual outcomes at final follow-up.

Conclusion: In this study of PIIH patients, the presence of ODH or CWS were not associated with worse VA at initial presentation or final follow-up.

References: 1. Bruce BB, Preechawat P, Newman NJ, Lynn MJ, Biousse V. Racial differences in idiopathic intracranial hypertension.Neurology 2008;70:861-867.
2. Wall M, Thurtell MJ, NORDIC IIH Study Group. Optic disc haemorrhages at baseline as a risk factor for poor outcome in the Idiopathic Intracranial Hypertension Treatment Trial. Br J Ophthalmol 2017;101:1256-60.
3. Scott CJ, Kardon RH, Lee AG, Frisen L, Wall M. Diagnosis and grading of papilledema in patients with raised intracranial pressure using optical coherence tomography vs clinical expert assessment using a clinical staging scale. Arch Ophthalmol 2010;128:705-11

Poster #152
Saturday, 9:55 am – 10:55 am

Impact of Obstructive Sleep Apnea on Optic Nerve Function in Patients with Craniosynostosis and Recurrent Intracranial Hypertension

Josephine Q.N. Nguyen, BSc; Cory M. Resnick, MD, DMD; Yoon-hee Chang, MD; Ronald M. Hansen, PhD; Carly E. Calabrese, MPH; Anne Fulton, MD; Linda R. Dagi, MD

Boston Children's Hospital
Boston, Massachusetts

Introduction: Intracranial hypertension (ICH) and obstructive sleep apnea (OSA) can adversely impact optic nerve function. This study assesses the combined association of ICH and OSA on optic nerve function in patients with craniosynostosis (CS), monitored by pattern reversal visual evoked potential (prVEP).

Methods: Retrospective cross-sectional evaluation of patients with CS who had ophthalmic examination and prVEP at Boston Children's Hospital (2013-2014). Inclusion criteria were history of ICH based on direct measurement or presence of papilledema or classic features on neuroimaging and during cranial vault expansion. History of OSA was determined by polysomnography, and conditions related to OSA, including apnea and (adeno)tonsillectomy. Subjects were divided into 4 groups: 1) resolved ICH absent history of OSA; 2) resolved ICH with history of OSA; 3) recurrent ICH absent history of OSA; and 4) recurrent ICH with history of OSA. Predictor variables included: latency of P1 component of prVEP (60' and 15' checkerboard), best corrected visual acuity and optic nerve appearance. Primary outcome was association of prolonged P1 latency with resolved versus recurrent ICH and OSA.

Results: 28 patients were included (mean age 11.6±6.9 years); group 1, (n=3); group 2, (n=6); group 3, (n=8); group 4, (n=11). Eight of the 11 in group 4 had significantly delayed latency for 15' checks and were the only patients demonstrating prolonged latency (p=0.002).

Discussion: History of OSA in addition to recurrent ICH is associated with greatest risk of optic neuropathy.

Conclusion: Early recognition and management of OSA, as well as ICH, may be essential to prevent optic neuropathy associated with CS.

References: 1. Stavrou P, Sgouros S, Willshaw HE et al. Visual failure caused by raised intracranial pressure in craniosynostosis. Childs Nerv Syst. 1997 Feb;13(2):64-7.
2.Inverso G, Brustowicz KA, Katz E et al. The Prevalence of obstructive sleep apnea in symptomatic patients with syndromic craniosynostosis. Int J Oral Maxillofac Surg. 2016 Feb;45(2):167-9.

Poster #153
Saturday, 9:55 am – 10:55 am

Deformation of the Peripapillary Retinal Pigmented Epithelium Layer on OCT: A Useful Tool to Identify Intracranial Hypertension in a Pediatric Population?

Mea A. Weaver, BS; Hilliary Inger, MD; Hersh Varma, MD; Catherine Jordan, MD; Rachel Reem, MD; Mary Lou McGregor, MD; Shawn Aylward, MD; David Rogers, MD

Nationwide Children's Hospital
Columbus, Ohio

Introduction: Anterior angulation of the peripapillary retinal pigment epithelium (PRPE) on optical coherence tomography (OCT) can indicate intracranial hypertension (IH) in adults. This study determined the frequency of OCT PRPE deformation in amongst pediatric patients with elevated lumbar puncture opening pressures. It also assessed the opening pressure values at which the sign was present.

Methods: Spectral-domain OCT (SD-OCT) optic nerve scans of 75 eyes from patients with intracranial hypertension were collected retrospectively. Three masked pediatric ophthalmologists independently reviewed the images for the presence or absence of PRPE deformation. The results of image interpretation were compared to the LPOP values associated with each scan.

Results: There was complete agreement that PRPE deformation was present in 12 scans (14%) and absent in 49 scans (57%). There was a mixed response in 14 scans (16%) and 11 scans (13%) were unreadable. The average LPOP was 43.95 ± 11.01 when all readers agreed PRPE deformation was present (group 1), 35.9 ± 11.23 when all agreed it was absent (group 2), 41.08 ± 11.96 when there was a mixed response (group 3). There was a significant difference between the average LPOP between groups 1 and 2 ($p=0.037$). There was no significant difference in the average LPOP between groups 1 and 3 ($p=0.52$) and between groups 2 and 3 ($p=0.17$).

Discussion: Despite known elevations of intracranial pressure (ICP) in all patients in this study, PRPE deformation was not uniformly identified.

Conclusion: The presence or absence of PRPE deformation was not a reliable indicator of elevated ICP in our study.

References: Kupersmith MJ, Sibony P, Mandel G, et al. Optical coherence tomography of the swollen optic nerve head: deformation of the peripapillary retinal pigment epithelium layer in papilledema. Invest Ophthalmol Vis Sci 2011;52(9):6558-64.

Sibony P, Kupersmith MJ, Rohlf FJ. Shape analysis of the peripapillary RPE layer in papilledema and ischemic optic neuropathy. Invest Ophthalmol Vis Sci 2011;52(11):7987-95.

Wang JK, Kardon RH, Ledolter J, et al. OCT Sub-Study Committee and the NORDIC Idiopathic Intracranial Hypertension Study Group. Peripapillary Retinal Pigment Epithelium Layer Shape Changes From Acetazolamide Treatment in the Idiopathic Intracranial Hypertension Treatment Trial. Invest Ophthalmol Vis Sci 2017;58(5):2554-2565.

Poster #154
Saturday, 9:55 am – 10:55 am

Longitudinal Analysis of Optic Nerve Edema, Retinal Nerve Fiber Layer Thickness, and Visual Field Mean Deviation in Pediatric Patients with Intracranial Hypertension

Hersh Varma, MD; Hilliary E. Inger, MD; Anastasia Alex, MD; Catherine O. Jordan, MD; Shawn C. Aylward, MD; David L. Rogers, MD

Nationwide Children's Hospital
Columbus, Ohio

Introduction: Optic nerve edema (ONE), retinal nerve fiber layer (RNFL) thickening, and increased visual field mean deviation (VFMD) comprise several of the significant ophthalmic findings in intracranial hypertension (IH) patients. RNFL thickness is strongly correlated with ONE at baseline, and improves with medical management in adults. Similarly, VFMD shows improvement with appropriate therapy. As monitoring response to therapy can be challenging in some children, this study aims to describe the longitudinal differences in these parameters in pediatric patients.

Methods: A retrospective chart review of 40 medically managed IH patients (80 eyes) was performed. Clinical exam, spectral domain optical coherence tomography (OCT), and perimetry data were collected from the time of diagnosis and at follow up approximately 3 and 6 months later. Analysis was performed to examine the change in these parameters through this time period.

Results: 35 (88%) patients were female and 31 (78%) had primary IH. Follow-up visits were at 2.2±0.9 and 5.7±1.1 months. There was a significant reduction in optic nerve head edema ($p<0.0001$) and RNFL thickness ($p<0.0001$) of both right and left eyes at each visit, with maximal change occurring from baseline to first follow-up. VFMD improved significantly for right ($p=0.005$) and left ($p=0.009$) eyes by last follow-up.

Discussion: ONE and RNFL thickness showed maximal improvement in the initial interval to first follow-up whereas VFMD showed gradual improvement by last follow-up.

Conclusion: ONE and RNFL thickness may be more useful in monitoring early response to therapy while VFMD may not show significant improvement until later.

References: 1. Optical Coherence Tomography Substudy Committee; NORDIC Idiopathic Intracranial Hypertension Study Group. Papilledema Outcomes from the Optical Coherence Tomography Substudy of the Idiopathic Intracranial Hypertension Treatment Trial. Ophthalmology 2015;122(9):1939-45.
2. Ahuja S, Anand D, Dutta TK, et al. Retinal nerve fiber layer thickness analysis in cases of papilledema using optical coherence tomography - A case control study. Clin Neurol Neurosurg. 2015;136:95-9.
3. Mikkilineni S, Trobe JD, Cornblath WT, et al. Visual Field Mean Deviation at Diagnosis of Idiopathic Intracranial Hypertension Predicts Visual Outcome. J Neuroophthalmol 2018;00:1-5.

Poster #155
Saturday, 9:55 am – 10:55 am

Neurofibromatosis Type 1 Associated Optic Pathway Glioma - A Very Long Term Follow Up

Michael Kinori, MD; Robert Listernick, MD; Joel Charrow, MD; Janice L. Zeid

Division of Ophthalmology, Ann & Robert H. Lurie Children's Hospital of Chicago
Chicago, Illinois, USA

Introduction: Optic pathway gliomas (OPGs) are a common manifestation of Neurofibromatosis type 1 (NF1) and can cause significant visual morbidity. In this study we describe a very long follow up on children with NF1-associated OPG's.

Methods: This retrospective study included children with a documented follow up of at least 10 years. Three final outcomes were evaluated: visual acuity (VA) per eye (i.e. in the more severely affected eye), visual acuity per patient. (i.e. visual acuity when both eyes are open) and presence of optic nerve head pallor.

Results: 45 children were included with a mean follow up time of 14 years (range 10-21). At the end of follow up abnormal visual acuity (considered as moderate to severe impairment) in the more severely affected eye was present in 49% of the patients and in both eyes in 33%. Optic nerve head pallor of one or both nerves was present in 62%. In a multivariate analysis only initial VA and optic nerve head appearance at presentation were found to predict the final outcomes. All patients but one who at presentation were asymptomatic and had normal VA and normal appearing nerves preserved their good vision in both eyes.

Discussion: The VA and optic nerve head appearance at presentation predict long term outcome. Children with NF1-associated OPG who were at presentation asymptomatic and had a normal exam kept their good vision in both eyes.

Conclusion: In this study, children with NF1-associated OPG who had a normal initial exam had excellent very long-term visual and anatomical outcomes.

References: 1. Kinori M, Hodgson N, Zeid JL. Ophthalmic manifestations in neurofibromatosis type 1. Surv Ophthalmol. 2018 Jul - Aug;63(4):518-533
2. Thiagalingam S, Flaherty M, Billson F, North K. Neurofibromatosis type 1 and optic pathway gliomas: follow-up of 54 patients. Ophthalmology 2004;111:568-77.
3. Listernick R, Ferner RE, Liu GT, Gutmann DH. Optic pathway gliomas in neurofibromatosis-1: controversies and recommendations. Ann Neurol 2007;61:189-98.

Poster #156
Saturday, 9:55 am – 10:55 am

Ophthalmologic Findings in Children with Metopic Suture and Deformational Cranial Vault Abnormalities

Garrett N. Ungerer; Laura A. Roider; Leslie A. Shock, MD; Arshad R. Muzaffar, MD; Kristina J. Aldridge, PhD; Mohannad Al-Samarraie, MD

University of Missouri - Columbia
Columbia, MO

Introduction: It is hypothesized that deformational plagiocephaly (DP) and brachycephaly (B) promote premature closure of cranial sutures, and ophthalmologic abnormalities have been observed in patients with craniosynostosis. The purpose of this project was to study the incidence of ophthalmologic findings which are known to be risk factors for amblyopia in children who have coexisting metopic suture abnormalities and DP or B.

Methods: This IRB-approved retrospective study reviewed records of children seen for abnormal head shape from 2007 to 2017. 76 children diagnosed with metopic suture abnormalities and DP/B were evaluated by ophthalmology and included in the study. Patients with severe trigonocephaly, other suture involvement, syndromic diagnoses, and primary ocular disorders were excluded.

Results: In our patient population, the rates of amblyopia (17.1%) and strabismus (15.8%) are higher than the general pediatric population rates of 1.5-1.8% and 2.4-3.6%, respectively. Overall, 47.4% had significant refractive error: 28.9% with astigmatism, 15.8% with hyperopia, 5.3% with myopia, and 10.5% with anisometropia.

Discussion: The increased rate of visual abnormalities places this population at higher risk for amblyopia and improper visual development. Those with minor trigonocephaly are often not referred to ophthalmology, leaving a large group with undiagnosed visual abnormalities. Amblyopia and its causes are best treated early, thus prompt referral to an ophthalmologist for formal eye examination and treatment may benefit this patient population.

Conclusion: In our patient population, children with coexisting metopic suture abnormalities and DP or B were at increased risk for amblyopia, strabismus, and refractive errors.

Poster #157
Saturday, 9:55 am – 10:55 am

Ocular Findings in Pontine Tegmental Cap Dysplasia

Lauren C. Mehner, MD, MPH; Jennifer L. Jung, MD; Emily A. McCourt, MD

University of Colorado School of Medicine, Department of Ophthalmology
Aurora CO

Introduction: Pontine Tegmental Cap Dysplasia (PTCD) is a recently described very rare disorder characterized by a distinctive hindbrain malformation causing developmental delay and cranial nerve deficits. This study aimed to describe the ocular findings in PTCD and the management strategies employed to care for these children.

Methods: Subjects with PTCD were recruited via social media advertisement and completed a survey gathering information on potential ocular complications of the patient's PTCD disease and any current or previous treatments.

Results: 21 subjects or guardians completed the survey. Neurotrophic cornea was the most common ocular diagnosis (86%), followed by blepharitis (57%) and facial palsy (57%). Other diagnoses included cortical visual impairment (29%), strabismus (24%), amblyopia (14%), and nystagmus (19%). Common treatment modalities included lubricating eye drops (57%) or ointment (48%), contact lenses (14%), punctal plugs (29%), glasses (43%) and patching (19%). The most common surgical interventions were temporary or permanent tarsorrhaphy (67%), and amniotic membrane grafts (24%). Two subjects underwent corneal transplant. 71% of families reported self-injury to eyes and 95% reported the child to be primarily a visual learner.

Discussion: PTCD is a newly described, very rare disorder with a variety of vision-threatening ocular manifestations. High rates of deafness from the cranial nerve deficits associated with PTCD make it even more essential that the ophthalmologist be aware of the potential for neurotrophic cornea as timely treatment could prevent corneal scarring, perforation, and blindness.

Conclusion: Understanding the spectrum of ophthalmic phenotypes of PTCD will aid in diagnosis and management of this complex disease.

References: 1. Barth PG, Majoie CB, Caan MW, et al. Pontine tegmental cap dysplasia: a novel brain malformation with a defect in axonal guidance. Brain. 2007;130(Pt 9):2258–66.
2. Nixon JN, Dempsey JC, Doherty D, Ishak GE. Temporal bone and cranial nerve findings in pontine tegmental cap dysplasia. Neuroradiology.2016;58(2):179-87.
3. Rauscher C, Poretti A, Neuhann TM, et al. Pontine tegmental cap dysplasia: the severe end of the clinical spectrum. Neuropediatrics. 2009;40(1):43-6.

Poster #158
Saturday, 9:55 am – 10:55 am

Longitudinal Follow-Up Study of Ocular Pathology in Children with Trisomy 21 in a Pediatric Ophthalmology Clinic

Allison C. Umfress, MD; Collin Hair, MD; Sean P. Donahue, MD, PhD

Vanderbilt University Medical Center, Vanderbilt Eye Institute
Nashville, TN

Introduction: Various ophthalmologic findings have been associated with Trisomy 21. However, few long-term data are available regarding the incidence of new pathology after an initially normal exam. We sought to evaluate whether children who have a normal first examination need to have formal re-evaluation by an ophthalmologist.

Methods: A retrospective observational review was undertaken of 689 patients seen at Vanderbilt Eye Institute. For those with a normal screening examination, follow up data were reviewed to determine if new abnormalities developed at subsequent visits.

Results: 279 of the 689 patients had a normal first exam. 179 had at least one follow up visit at a mean follow-up period of 21.6 months). At the first follow up visit, 129 remained normal, while 50 had a new abnormality; most commonly visually significant refractive error and strabismus. The average time to follow up was 20.4 months for those with an abnormal follow up exam and 21.6 months for those with a normal exam. Of those with a normal first follow up visit, 65 had a second visit (mean follow up period of 12 months). 41 of those remained normal, while 24 (36%) developed a new abnormality.

Discussion: The development of ocular pathology in children with Trisomy 21 is unpredictable even after an initial normal exam. However, most of these abnormalities could be detected with photoscreening or traditional screening and may not require formal examination.

Conclusion: Down syndrome children who have an initially normal examination can be followed in the medical home using validated screening techniques.

References: 1. Ljubic A, Trajkovski V, Stankovic B. Strabismus, refractive errors and nystagmus in children and young adults with Down syndrome. Ophthalmic Genet. 2011;32(4):204-211.
2. Creavin AL, Brown RD. Ophthalmic abnormalities in children with Down syndrome. J Pediatr Ophthalmol Strabismus. 2009;46(2):76-82.
3. Yanovitch T, Wallace DK, Freedman SF, et al. The accuracy of photoscreening at detecting treatable ocular conditions in children with Down syndrome. J AAPOS. 2010;14(6):472-477.

Poster #159
Saturday, 9:55 am – 10:55 am

Experience of a Non-Pediatric Trained Ophthalmic Hospitalist at a Children's Hospital

Ashley Khalili, MD; Maggie Hymowitz, MD; Matthew Gorski, MD; Hal Schwartzstein, DO; Sylvia Kodsi, MD

Northwell Health
Great Neck, NY

Introduction: The role of an ophthalmic hospitalist includes the evaluation and management of all inpatient and emergency department ophthalmology consultations. The ophthalmic hospitalist at our institution is a non-pediatric trained ophthalmologist covering multiple hospital locations including a 202-bed children's hospital and emergency department. This review aimed to evaluate the consultations managed by an ophthalmic hospitalist covering a children's hospital and the need for escalation of care to a pediatric ophthalmologist or alternative subspecialists.

Methods: A retrospective chart review was performed of all patients managed by the weekday daytime consultation service between July 1st and August 31st. The requirement of a pediatric ophthalmologist consultation was identified and stratified between those requiring a discussion for assessment and plan management, or those requiring the subspecialist to come in and assess the inpatient directly. Further data was collected including the reason for consultation and abnormal findings.

Results: A total of 61 pediatric patients were evaluated by the ophthalmic hospitalist service. Consultation with the pediatric ophthalmology department was utilized in 15 cases(25%,) with 10 of such cases via discussion and 5 patients evaluated by the pediatric ophthalmology attending directly. Alternative subspecialists involved in hospitalist cases included oculoplastics, neuro-ophthalmology and cornea who were contacted for 8(13%), 2 and 2 cases respectively.

Discussion: A majority of consults are evaluated by an ophthalmic hospitalist without the consultation of a pediatric ophthalmologist.

Conclusion: The utilization of an ophthalmic hospitalist is an effective way to provide an ophthalmology consult service at a children's hospital in conjunction with pediatric ophthalmology subspecialists for management.

References:

Poster #160
Saturday, 9:55 am – 10:55 am

An Examination of Visits to the Pediatric Emergency Departments for Emergent, Urgent and Non-Urgent Ocular Conditions

Jing Jin, MD, PhD; Lauren Bules; Kaynan Doctor, MD; Dorothy Hendricks, MD; Julia Reid, MD; Jonathan Salvin, MD; Sharon Lehman, MD; Airaj Fasiuddin, MD

Nemours A. I. duPont Hospital for Children, Wilmington, Delaware
Nemours Children's Hospital, Orlando, Florida

Introduction: To analyze factors associated with visits to pediatric emergency departments (PEDs) for ophthalmologic conditions.

Methods: This is a retrospective review of the Electronic Medical Records of all PED ocular-related encounters seen at two children's hospitals in Delaware and Florida between January 2014 and May 2018. The encounters were categorized based on ICD and CPT codes. Emergent encounters were life or sight threatening, urgent encounters were those deemed to be associated with significant patient discomfort. Non-urgent encounters were conditions that could be managed in the outpatient setting. Demographic variables and insurance types were analyzed using x2 test to see if they influenced the frequency of visits within each category.

Results: There were 7,675 ocular-related PED encounters. Of these, 1649 (21%) were emergent, 1417 (18%) were urgent while the remaining 4609 (60%) were non-urgent encounters. The most common diagnosis amongst non-urgent encounters was conjunctivitis (70%), while more than 80% of emergent and 50% of urgent encounters were due to eye trauma. Male patients made up 65% of emergent encounters. African American, Hispanic, and patients </= 6 years made up a larger proportion of non-urgent visits compared to emergent visits ($p<0.001$). Additionally, non-urgent encounters were more likely to have Medicaid ($p<0.001$) and were found to visit the PED more frequently ($p<0.001$).

Discussion: Our study identifies several demographic factors associated primarily with non-urgent ocular PED visits.

Conclusion: We advocate for implementation of parental and clinician-centered education to reduce the prevalence of both preventable eye trauma in children and PED visitation for non-urgent ophthalmologic conditions.

References: National Center for Health Statistics. Health, United States, 2016: With Chartbook on Long-term Trends in Health. Hyattsville, MD. 2017.
Stagg et. al. Factors affecting visits to the emergency department for urgent and non-urgent ocular conditions. Ophthalmology. 2017 May; 124(5): 720–729.
Hoot NR, Aronsky D. Systematic review of emergency department crowding: causes, effects, and solutions. Ann Emerg Med. 2008;52:126–36.

Poster #161
Saturday, 9:55 am – 10:55 am

Pediatric Ocular Injuries: A 3-Year Follow-Up Study of Patients Presenting to a Tertiary Care Clinic in Canada

Cyril Archambault; Assia Mekliche; Jordan Isenberg; Patrick Hamel; Rosanne Superstein

Centre Hospitalier Universitaire - Hospital Sainte-Justine
Montreal, Qc (Canada)

Introduction: Ocular traumas represent the most common cause of non-congenital blindness in children. Sports or sports equipment related injuries represent a major cause in children over the age of 10. However, activities differ depending on country and climate, suggesting that the mechanisms of trauma may vary according to region.

Methods: A retrospective review of all trauma cases presenting to the eye clinic at CHU Ste Justine, Montreal, Quebec between 2013 and 2015 was conducted.

Results: A total of 409 patients with a mean age of 7.74 years were included. Boys were injured more frequently than girls (60.4%). Most ocular injuries occurred between the ages of 2 and 9 years old (51.8%). The most common sport was soccer, followed by ball/ice hockey. Injuries occurred at home in 23.2% of cases. Final visual acuity was 20/40 or better in 77.0% of patients.

Discussion: This is the second epidemiological study examining causes and outcomes of pediatric ocular traumas in the province of Quebec. In our current sample, soccer was responsible for 33% of sports injuries, while non-organized hockey for only 20%. This trend is similar to studies done in the UK and could indicate that soccer is increasing in popularity in Canada.

Conclusion: Our demographic findings are comparable with those of the only other Canadian study done on this subject. We are hoping that by identifying high risk activities, health authorities will be able to plan better prevention strategies thus reducing vision loss and morbidity in the pediatric population.

References: 1. Podbielski DW, Surkont M, Tehrani NN, Ratnapalan S. Pediatric eye injuries in a Canadian emergency department. Canadian journal of ophthalmology Journal canadien d'ophtalmologie. 2009;44(5):519-22.
2. Haring RS, Sheffield ID, Canner JK, Schneider EB. Epidemiology of Sports-Related Eye Injuries in the United States. JAMA ophthalmology. 2016;134(12):1382-90.
3. Matsa E, Shi J, Wheeler KK, McCarthy T, McGregor ML, Leonard JC. Trends in US Emergency Department Visits for Pediatric Acute Ocular Injury. JAMA ophthalmology. 2018;136(8):895-903

Poster #162
Saturday, 9:55 am – 10:55 am

Survey of Atropine for the Control of Myopia

Noha S. Ekdawi, MD[1]; Celso M. Cunha[2]

1) Wheaton Eye Clinic, Wheaton, IL
2) SOBLEC, Sao Paulo, Brazil

Introduction: We aim to define practice patterns by pediatric ophthalmologists through a survey held from October to November of 2017.

Methods: All members of AAPOS were contacted by e-mail to complete an anonymous, twenty-question internet-based survey.

Results: Two-hundred fifteen members answered the questionnaire. North America comprised 86% of respondents. All continents, except Antarctica, were represented. Regarding low dose atropine 79% believed it helped decrease myopic progression based on the current research. 69% of the respondents were prescribing atropine. Of 154 using atropine, 145 used 0.01%, 11 used 1% and 6 used 0.1%. Seventy-eight percent used nightly dosing for 2 years (36%) or greater than 3 years (46%). Over 90% of physicians would start atropine only on patients younger than 13 years. For syndromic patients, 56% of respondents would not start atropine. No side-effects were reported by 94%. The main side effects were light sensitivity (20%), decreased reading vision (12%), allergies (5%), and Headaches (1%).

Discussion: The use of low dose atropine was common in most continents. The majority were prescribing atropine 0.01% nightly for at least two years. The most unwanted side-effects might due to those using atropine 1%.

Conclusion: While low dose atropine is commonly used, its effectiveness needs to be defined by a new randomized control treatment trial.

References: 1. Holden BA, Fricke TR, Wilson DA, et al. Global prevalence of myopia and high myopia and temporal trends from 2000 through 2050. Ophthalmology. 2016;123(5):1036-42.
2. Chia A, Chua WH, Cheung YB, Wong WL, Lingham A, Fong A, Tan D. Atropine for the treatment of childhood myopia: safety and efficacy of 0.5%, 0.1%, and 0.01% doses (Atropine for the Treatment of Myopia 2). Ophthalmology. 2012;119(2):347-54.

Poster #163
Saturday, 9:55 am – 10:55 am

Psychosocial and Mental Health Disorders Among Patients with Congenital Ptosis

Tina M. Hendricks; Gregory J. Griepentrog, MD; David O. Hodge; Brian G. Mohney, MD

Mayo Clinic
Rochester, Minnesota

Introduction: Recent studies have demonstrated significant adverse psychosocial and mental health disorders among children with ocular disorders such as strabismus. The purpose of this study was to compare the psychosocial and mental health findings of patients with simple congenital ptosis to age- and gender-matched controls.

Methods: The medical records of all children (< 19 years) diagnosed with simple congenital ptosis (N = 81) from January 1, 1965, through December 31, 2004, in a medically-isolated region were retrospectively reviewed for psychosocial and mental health morbidity. One-to-one age- and gender-matched controls without ptosis from the same study population were similarly reviewed.

Results: An adverse psychosocial development was diagnosed in 41 (50.6%) patients with simple congenital ptosis monitored to a mean age of 21.4 years, compared with 26 (32.5%) controls (p=0.02). A mental illness was diagnosed in 31 (38.3%) patients with ptosis compared to 16 (20%) controls (p=0.01). Ptotic children were 2.5 and 2.1 times more likely than controls to develop a mental illness or psychosocial maladjustment, respectively. Patients with ptosis were also significantly more likely to have a greater number of mental health disorders (p=0.02) and a longer duration of psychotropic medication use (p=0.005).

Discussion: Simple congenital ptosis, a condition, like strabismus, noticeable to outside observers, is associated with an adverse psychosocial and mental health burden.

Conclusion: Children diagnosed with simple congenital ptosis in this population had significantly more psychosocial and mental health morbidity compared to controls.

References: 1. Satterfield D, Keltner JL, Morrison TL. Psychosocial aspects of strabismus study. Archives of Ophthalmology. 1993;111(8):1100-1105.
2. Menon V, Saha J, Tandon R, Mehta M, Khokhar S. Study of the psychosocial aspects of strabismus. Journal of pediatric ophthalmology and strabismus. 2002;39(4):203-208.
3. Mohney BG, McKenzie JA, Capo JA, Nusz KJ, Mrazek D, Diehl NN. Mental illness in young adults who had strabismus as children. Pediatrics. 2008;122(5):1033-1038.

Poster #164
Saturday, 9:55 am – 10:55 am

Differences in the Microbiome by Anatomic Site with Age

Kara M. Cavuoto, MD; Santanu Banerjee, PhD; Darlene Miller, DHSc; Anat Galor, MD

Bascom Palmer Eye Institute
Miami, FL

Introduction: Recent publications have shown that the ocular surface microbiome (OSM) differs in adults and children. However little is known about how the composition of the microbiome of the periocular tissues compares by age. We sought to characterize the OSM of the conjunctiva, eyelid margin and periocular skin in both children and adults.

Methods: Prospective, cross-sectional study using 16S sequencing to evaluate the OSM. Comparisons were made in bacterial yield and composition by sampling location (periocular skin, eyelid margin, or conjunctiva). 16S sequencing was performed using Illumina MiSeq 250 and analyzed using Qiime. Statistical analysis was performed using a two-sided student's t-test and Monte Carlo permutations.

Results: 30 patients (15 children [mean 3.7 years], 15 adults [mean 60.4 years]) were sampled. The periocular skin, eyelid margin and conjunctiva were all distinct in adults ($p=0.028$); however in children, no significant difference was found between periocular skin and eyelid margin or eyelid margin and ocular surface. When comparing the periocular skin microbiome in adults to children, there was a greater abundance of Firmicutes ($p=0.004$) and a lower abundance of Proteobacteria ($p<0.0001$).

Discussion: The microbiome of the ocular surface in children is similar to the microbiomes of the eyelid margin and periocular skin, whereas the adult OSM showed distinct compositional differences between the periocular skin, eyelid margin and conjunctiva. This finding implies that there is tutoring of the host immune system and the microbial ecosystem with aging.

Conclusion: Age plays an important role in the evolution of distinct microbiomes at different periocular and ocular anatomic sites.

References:

Poster #165
Saturday, 9:55 am – 10:55 am

Conjunctival Flora Before and After Povidone-Iodine in Neonates

Sapna S. Desai, MD; Ryan N. Vogel, MD; Iris S. Kassem, MD, PhD; Deborah M. Costakos, MD

Medical College of Wisconsin Eye Institute
Milwaukee, Wisconsin

Introduction: Intravitreal injections are used more frequently for treatment of type 1 retinopathy of prematurity (ROP). There is no evidence on the efficacy of 5% povidone-iodine (PI) or topical antibiotics during or after the injection in neonates. This study identifies conjunctival flora, antibiotic susceptibility, and effect of PI in neonates in the neonatal intensive care unit (NICU) at Children's Hospital of Wisconsin (CHW).

Methods: Consent was obtained by the parent of 40 neonates in the CHW NICU undergoing ROP exams. A sample was obtained from the fornix of a randomly selected eye from each participant using an E-swab™. Two drops of 5% PI were instilled in the fornix. After two minutes, another sample was obtained. Samples were sent for Gram stain, culture, quantification of colony-forming units, and susceptibility to five antibiotics (erythromycin, polymyxin, tobramycin, ofloxacin, and moxifloxacin).

Results: There was a statistically significant decrease in the number of positive cultures from 72.5% to 47.5% after PI ($p=0.022$). The most common species isolated before and after PI were coagulase-negative Staphylococcus (CNS) (58% and 57% of positive cultures, respectively) and Streptococcus viridans (20% and 16%, respectively). The decrease in the number of cultures positive for CNS was statistically significant ($p=0.0073$), but not for Streptococcus viridans ($p=0.13$). Most CNS were susceptible to ofloxacin, moxiflocaxin, and tobramycin.

Discussion: PI does significantly decrease the culture positivity rate in neonates, but is not significantly effective for all of the most common bacterial causes of endophthalmitis.

Conclusion: Antibiotic prophylaxis should be considered prior to intravitreal injection and continued afterwards in this population.

References: 1. Storey P, Dollin M, Pitcher J, et al. The role of topical antibiotic prophylaxis to prevent endophthalmitis after intravitreal injection. Ophthalmology. 2014;121(1):283-289.
2. Kim SJ, Toma HS. Antimicrobial resistance and ophthalmic antibiotics: 1- year results of a longitudinal controlled study of patients undergoing intravitreal injections. Arch Ophthalmol. 2011;129(9):1180-8.
3. CLSI. Performance Standards for Antimicrobial Susceptibility Testing. 27th ed. CLSI supplement M100. Wayne, PA: Clinical and Laboratory Standards Institute; 2017.

Poster #166
Saturday, 9:55 am – 10:55 am

Antibiotic Resistance Among Ocular Bacterial Pathogens from Pediatric Patients

Rachel A. Wozniak, MD, PhD[1]; Matthew Gearinger, MD[1]; Sherman J. Alter, MD[2]; Christine Sanfilippo, PhD[3]

[1]Flaum Eye Institute, University of Rochester Medical Center, Rochester, NY; [2]Division of Infectious Disease, Dayton Children's Hospital, Wright State University Boonshoft School of Medicine, Dayton Ohio; [3]Bausch + Lomb, Rochester NY

Introduction: The Antibiotic Resistance Monitoring in Ocular micRoorganisms (ARMOR) study is a nationwide antibiotic resistance surveillance program specific to bacterial pathogens encountered in ocular infections. We report *in vitro* antimicrobial resistance data for isolates collected from pediatric patients from 2009 through 2017.

Methods: Clinical centers across the US submitted ocular isolates of *Staphylococcus aureus*, coagulase-negative staphylococci (CoNS), *Pseudomonas aeruginosa*, *Streptococcus pneumoniae*, and *Haemophilus influenzae* to a central laboratory. Minimum inhibitory concentrations (MICs) were determined for a panel of antibiotics and were interpreted as susceptible or resistant based on established breakpoints.

Results: 330 S. aureus, 245 CoNS, 75 *P. aeruginosa*, 163 *S. pneumoniae*, and 329 *H. influenzae* isolates were collected from pediatric patients (</=17 years) between 2009-2017. Among *S. aureus* and CoNS, respectively, 23% and 48% were methicillin-resistant (MR) with 47% MRSA and 71% of MRCoNS resistant to >/=3 drug classes. Resistance to the early-generation fluoroquinolone ciprofloxacin was 14% and 17% for S. aureus and CoNS, respectively; the latest-generation fluoroquinolone besifloxacin had the lowest MICs. In vitro fluoroquinolone resistance was low among *P. aeruginosa*, *S. pneumoniae*, and *H. influenzae* (<4%). Longitudinal trend analysis showed significant decreases in oxacillin/methicillin and ciprofloxacin resistance among *S. aureus* ($P<0.01$) over the study period.

Discussion: *In vitro* antibiotic resistance is common among staphylococcal isolates collected from pediatric patients with ocular infections. Methicillin resistance was prevalent among staphylococci, with many strains demonstrating multidrug resistance.

Conclusion: Since culturing of eye infections is rarely performed, these data should be considered in selecting empirical treatment for pediatric patients.

References: Alter SJ, Sanfilippo CM, Asbell PA, DeCory HH. Antibiotic resistance among pediatric-sourced ocular pathogens: 8-year findings from the ARMOR surveillance study. Pediatr Infect Dis J. In press.
Asbell PA, Sanfilippo CM, Pillar CM, DeCory HH, Sahm DF, Morris TW. Antibiotic resistance among ocular pathogens in the United States: Five-year results from the Antibiotic Resistance Monitoring in Ocular micRoorganisms (ARMOR) surveillance study. JAMA Ophthalmol. 2015;133(12):1445-1454.

Poster #167
Saturday, 9:55 am – 10:55 am

Management of Ocular Manifestations of Harlequin Ichthyosis in the Perinatal Period

Sylvia Kodsi, MD; Hal R. Schwartzstein, DO; Ashley Khalili, MD; Matthew Schear, DO; Giovanni Greaves, MD; Matthew Gorski, MD

Northwell Health
Great Neck, New York

Introduction: Harlequin Ichthyosis (HI) is a severe and rare genetic disorder caused by mutations on the ABCA12 gene on chromosome 2 (2q34). Dysfunction of this gene, involved in the regulation of protein synthesis required for skin barrier function, leads to extreme hyperkeratosis. Patients present with thick plate-like scales separated by deep cracks (fissured hyperkeratosis,) leading to tightness of the skin around the eyes, mouth, ears, chest, abdomen and extremities with subsequent high morbidity and mortality during the neonatal period. Cicatricial ectropion may result in exposure keratopathy and severe ocular surface pathology. There is limited literature describing management of this ocular manifestation.

Methods: Case series of two newborns with HI presenting within 2 months, and a review of the management and outcomes.

Results: Two newborns were seen in the Neonatal ICU with HI, severe upper eyelid ectropion, and corneal exposure. The ophthalmic management of both patients included aggressive lubrication with petrolatum ophthalmic ointment alternating with erythromycin ointment every 2 hours. The patients were treated with systemic retinoids and were placed in contact precaution humidified incubators. Both patients were followed closely with improvement over the course of three months and did not require eyelid skin grafting. The corneas remained clear throughout the neonatal period.

Discussion: HI can cause severe corneal disease in the neonatal period. Aggressive lubrication with close follow up is necessary for preservation of the ocular surface.

Conclusion: Non-surgical management of HI in a newborn can prevent sequela of severe exposure keratopathy.

References: Kelsell DP, Norgett EE, Unsworth H, et al. Mutations in ABCA12 Underlie the Severe Congenital Skin Disease Harlequin Ichthyosis. American Journal of Human Genetics. 2005;76(5):794-803.

Poster #168
Saturday, 9:55 am – 10:55 am

Magnetic Resonance Imaging Findings in Children with Congenital Corneal Opacities

Julia Xia, BA; Sasha Mansukhani, MBBS; Nadja Kadom, MD; Phoebe Lenhart, MD

Emory Eye Center, Emory University School of Medicine
Atlanta, GA

Introduction: Children with congenital opacities often have multiple systemic anomalies. Few studies have characterized magnetic resonance imaging (MRI) findings associated with congenital corneal opacification. This study investigates the most common associated central nervous system and globe abnormalities in these children.

Methods: Retrospective cohort study of patients diagnosed with corneal opacification within the first 6 months of life at a tertiary referral academic center. Clinical, operative, and radiology records were reviewed. Characteristics of the corneal opacities were investigated as well as findings of MRI brain and orbits.

Results: A total of 146 patients presenting at age 1 day - 12 years (mean age 1 year) were followed for an average of 3.5 years between January 2001-September 2018. Of these, 50.7% had unilateral opacity vs. bilateral, and 41.1% had total opacification vs. partial. Microphthalmos (26.0%), iris coloboma (9.6%), chorioretinal coloboma (4.8%), iridocorneal/lenticular corneal lesions (29.5%), and glaucoma (31.5%) were seen in these patients. A total of 48 (32.9%) patients had MRI imaging, of which 31 (64.6%) had abnormal findings. The most common findings were ventriculomegaly (58.1%), corpus callosum abnormalities (32.2%), and megacisterna magna (25.8%). More than half (58.1%) of the patients who had MRI also had orbital anomalies, most commonly enlarged globes (66.7%).

Discussion: Children with congenital corneal opacities who were imaged with MRI had abnormal associated brain and orbit findings.

Conclusion: MRI can provide information about co-morbid neurological abnormalities in children with corneal opacities to help guide management of these challenging patients.

References: Skalicky SE, White AJR, Grigg JR, et al. Microphthalmia, Anophthalmia, and Coloboma and Associated Ocular and Systemic Features Understanding the Spectrum. *JAMA Ophthalmol.* 2013;131(12):1517–1524. doi:10.1001/jamaophthalmol.2013.5305

Poster #169
Saturday, 9:55 am – 10:55 am

Anatomic and Visual Outcomes in Peters Anomaly

Samiskha Fouzdar Jain, MD; Zena Ibrahim; Mehmet C. Mocan, MD

Department of Ophthalmology and Visual Sciences , Illinois Eye&Ear Infirmary, University of Illinois at Chicago
Chicago, IL

Introduction: The aim of this study was to evaluate the anatomic and visual outcomes of pediatric patients diagnosed with Peters anomaly

Methods: This is a retrospective single-center study conducted at Department of Ophthalmology and Visual Sciences at University of Illinois at Chicago 2000-2017. Visual acuity (VA) levels, intraocular pressures (IOP), presence of glaucoma, and surgical procedures performed were recorded.

Results: We looked at 29 eyes of 16 patients and the mean age at initial presentation was 3.8±7.0 months (range=0.25-30 months), and the mean follow-up period was 80.0±55.6 months (range=12–209 months). Twenty eyes had type 1 Peters while 9 eyes had type 2 Peters anomaly. At initial visit, VA was BTL in 9 eyes, fix and follow in 15, no fix and follow in 3 and was unrecordable in 2 eyes. Final VA ranged from NLP to 20/30. Nine (42.9%) eyes had VA of 20/200 or better at final visit while 12 eyes (57.1%) had VA worse than 20/200. None of the eyes with type 2 anomaly had better VA than 20/100. Twenty three (79%) eyes were found to have glaucoma. The mean IOP at initial visit was 23.8±9.1 mmHg (range= 12.0-48.5mmHg) and mean IOP at final visit 16.1±6.2 (range= 8-28 mmHg) was statistically significant ($p< 0.02$). Almost two thirds (72.4%) of patients underwent surgical interventions to restore corneal clarity, reduction of IOP or cataract removal.

Discussion: In our series, majority of patients with Peters anomaly had glaucoma and IOP control could be achieved with medical and surgical interventions. Eyes with type 2 Peters anomaly generally tend to have a poor visual prognosis as compared to those with type 1 Peters anomaly.

Conclusion: Prognosis of visual acuity in Peters anomaly is poor and the surgical interventions are associated with risk and complications. It is imperative to manage these patients with a multidisciplinary approach.

References: 1. L.L. Yang, S.R. Lambert, M.J. Lynn, R.D. Stulting Long-term results of corneal graft survival in infants and children with Peters anomaly|Ophthalmology, 106 (1999), pp. 833-848
2.Yoshikawa H1, Sotozono C, Ikeda Y, Mori K, Ueno M, Kinoshita S.Long-Term Clinical Course in Eyes With Peters Anomaly.Cornea. 2017 Apr;36(4):448-451.

Poster #170
Saturday, 9:55 am – 10:55 am

Ocular Trauma Score (OTS) versus Adapted OTS in Pediatric Open Globe Injuries

Nashwa Badr Eldine; Maha M. Youssef, MD; Ghada Gawdat; Ghada Osama

Kasr Alainy Hospital, Faculty Of Medicine, Cairo University
Cairo, Egypt

Introduction: Ocular Trauma Score (OTS) is a categorical system used for standardized assessment and visual prognosis of ocular injuries. Relative afferent pupillary defect (RAPD) is a variable that is difficult to assess in pediatric patients. An adapted OTS score was suggested excluding RAPD. In this study, we compare the prognostic value of OTS and adapted OTS in predicting the likely visual outcome of pediatric patients with open globe injuries.

Methods: A prospective observational study including children with open globe injuries. Initial and final best corrected visual acuity (BCVA) (after 3 months) were recorded as follows: 1- NLP (No light perception), 2- LP to HM (Light perception to Hand Movement), 3- 1/200 to 19/200, 4- 20/200 to 20/50, and 5->/= 20/40. OTS and adapted OTS were calculated and compared regarding the prediction for final visual outcome.

Results: 130 patients were included, ages (4-18, mean 10.06 +/- 3.94 years). The median initial visual acuity category (LP to HM) significantly improved to 20/200 - 20/50. ($p < 0.001$). OTS parameters analysis showed that the initial visual acuity category, retinal detachment and RAPD had a highly significant impact on final visual outcome ($p<0.001$). The final visual acuity according to OTS and adapted OTS prediction was comparable with the achieved final visual outcome. Comparing both scores as a whole, OTS had a higher predictive value however not statistically significant ($p=0.55$).

Discussion: Excluding RAPD would still make the OTS reliable and highly prognostic while rendering it much easier to apply.

Conclusion: Adapted OTS can be reliably used among pediatric patients.

References: 1. Unver YB, Acar N, Kapran Z, et al. Visual predictive value of the ocular trauma score in children. Br J Ophthalmol 2008; 92: 1122-4.
2. Shah MA, Shah SM, Applewar A,etal. Ocular trauma score as a predictor of final visual outcomes in traumatic cataract cases in pediatric patients. J Cataract Refract Surg 2012;38: 959-65.
3. Schorkhuber MM, Wackernagel W, Riedl R, et al. Ocular trauma scores in paediatric open globe injuries. Br J Ophthalmol 2014; 98: 664-8.

Poster #171
Saturday, 9:55 am – 10:55 am

Ocular Chemical Injuries from Laundry Detergent Pods in Children

Samantha J. Feldman, MD; Marijean Miller, MD; Catherine Origlieri, MD; Laura Kueny, MD; Rasheed Alhabshan, MD

Children's National Medical Center
Washington DC

Introduction: The National Poison Data System had more than 17,000 inquiries relating to laundry pods in 2012-13. This study characterizes the ocular injuries treated at a children's hospital from market entry in 2012 to 2017.

Methods: All ICD codes related to ocular chemical burns were identified and reviewed for laundry pod exposure. Patient demographics, pod brand and eye exams were collected.

Results: Eighty-two ocular chemical injuries were treated by consulting ophthalmologists. Laundry pods accounted for 25 (30%), mostly in preschoolers. Initial exam findings included lid swelling, chemical conjunctivitis and corneal abrasion, without limbal ischemia. Injuries generally resolved over 2-7 days, even when >50% of the corneal surface was abraded at presentation. Only 5 children had residual, healing abrasions at last follow up; one child had a persistent corneal scar.

Discussion: Long-term damage from laundry pods in our series was rare. One child with a permanent, yet visually insignificant corneal scar was exposed to the pod brand with the highest pH. Abrasions may stem from surfactant cytotoxicity as most pods are near neutral pH. In this preschool aged population, corneal abrasion size was measured in percent of the total cornea rather than in millimeters, which may be a limitation.

Conclusion: This data highlights the growing prevalence of laundry pod ocular injuries in young children. Avoidance is important given the risk of poisoning and death from pod ingestion, yet it may be reassuring to ophthalmologists that permanent corneal scarring was rare in our series.

References: Williams, Haley et al. Exposure to liquid detergent capsules: A study undertaken by the UK National Poisons Information Service. Clinical Toxicology. 2012; 50(8): 776–780. doi: 10.3109/15563650.2012.709937.

Valdez, Amanda et al. Pediatric Exposure to Laundry Detergent Pods. Pediatrics. 2014; 134(6): 1-9. doi: 10.1542/peds.2014-0057.

Haring, Sterling et al. Detergent Pod-Related Eye Injuries Among Preschool-Aged Children. Jama Ophthalmology. 2017; 135(3): 283-284. doi: 10.1001/jamaophthalmol.2016.5694.

Poster #172
Saturday, 9:55 am – 10:55 am

Pediatric Lens Subluxation and Post-Lensectomy Visual Acuity

Deborah K. Vanderveen, MD; Bharti Gangwani, MD; Crystal S. Cheung, MD

Introduction: Timing of surgery for children with early onset lens subluxation has been controversial due to increased surgical risks and challenges with optical correction. The purpose of this study is to present best corrected visual acuity (BCVA) outcomes after lensectomy with or without IOL implantation, and identify factors associated with subnormal BCVA.

Methods: Chart review of patients undergoing surgery 2007-2018 was performed; only patients with bilateral lens subluxation before age 5 years and with at least 3 months follow up were included. Data collected included age at diagnosis, pre- and post-operative BCVA, mode of pre- and post-operative refractive correction, biometry, surgical technique, and complications. Comparison of variables contributing to visual acuity outcome was performed.

Results: Twenty patients were identified, 18/20 had Marfan syndrome. Median age at surgery was 8.5 years (range, 8 months - 20 years). At the last visit, 12 eyes were aphakic, 28 were pseudophakic (5 eyes sutured PCIOL, 23 iris-fixated IOL). Mean follow-up was 35.9+22.7 months.
Overall, mean pre-operative BCVA was 0.5+0.3 logMAR, and post-operative BCVA was 0.2+0.2 logMAR ($p<0.001$). Persistent refractive amblyopia (20/40 or worse) was noted in 5 eyes of 4 patients. Inadequate early correction of high refractive error was associated with amblyopia.

Discussion: Surgery for lens subluxation in childhood typically results in good final vision and may be delayed if appropriate refraction can be provided and tolerated in the early years. Adequate refractive correction is important for BCVA.

Conclusion: Early surgery may be needed if adequate optical correction cannot be achieved.

References: Miraldi Utz G, Coussa RG, Traboulsi E. Surgical management of lens subluxation in Marfan syndrome. J AAPOS 2014 Apr;18(2):140-6.

Poster #173
Saturday, 9:55 am – 10:55 am

Longer-Term Outcomes of Intraocular Lens Implantation in Children with Marfan Syndrome: Trans-scleral Sutured vs Ophtec Iris-Enclaved

Marisa O'Brien, OD; James Hoekel, OD; Paul Foeller, MS; Lawrence Tychsen, MD

Washington University in St. Louis School of Medicine
St. Louis, MO

Introduction: Treatment of ametropia in children with Marfan Syndrome due to ectopia lentis entails removal of the dislocated crystalline lens. The ensuing aphakia has been treated by intraocular lens (IOL) implantation using either a trans-scleral sutured, posterior chamber IOL (TSS-IOL) or an iris-enclaved anterior chamber IOL (Ophtec IOL). Here we compare efficacy and safety outcomes after TSS-IOL or Ophtec IOL implantation in a series of Marfan Syndrome children.

Methods: Outcomes were collated retrospectively (TSS-IOL) and prospectively (Ophtec IOL) for 17 eyes (9 children) implanted with TSS-IOLs and 23 eyes (12 children) implanted with Ophtec IOLs. All children had a history of lensectomy-vitrectomy with complete capsulectomy for ectopia lentis. Age at IOL implantation was comparable ($p = .60$), an average 6.25 yrs (1 - 19 yrs) for TSS-IOL and 4.92 yrs (1 - 11 yrs) for Ophtec IOL. Average follow-up in the TSS-IOL group was 10.0 yrs (5 - 16 yrs) and in the Ophtec IOL group 3.17 yrs (1 – 7.5 yrs).

Results: At last follow-up visit, CDVA was better than pre-operative measures in 59% of TSS-IOL implanted eyes and 91% of Ophtec IOL eyes. The major cause of severe visual loss in TSS-IOL eyes was retinal detachment (41%, 7/17 eyes); no cases of retinal detachment occurred in Ophtec IOL eyes (0%, 0/26). Suture breakage-related TSS-IOL dislocation required either re-suturing in (35.3%, 6/17 eyes) and/or subsequent IOL exchange with implantation of an anterior chamber IOL (53%, 9/17 eyes). One case of dislocation of an Ophtec IOL occurred after it was exchanged from the TSS-IOL. Iris capture required IOL repositioning in 24% (4/17) of TSS-IOL eyes. Central corneal thickness was greater ($p = .35$) in TSS-IOL eyes compared to Ophtec IOL eyes.

Discussion: Longer term follow-up of children with Marfan Syndrome reveals substantial differences in efficacy and safety for TSS vs Ophtec IOL implanted eyes. IOL dislocation, IOL exchange and/or retinal detachment with loss of CDVA occurred in greater than 40% of TSS IOL implanted eyes followed an average of 10 years. These complications were not encountered in children implanted with the Ophtec IOL.

Conclusion: The Ophtec IOL is safer and more effective in treatment of aphakia compared to the TSS-IOL in pediatric patients with Marfan Syndrome. Iris-enclaved IOL implantation poses less risk to the surgeon and child in the operative and immediate post-operative period. Follow-up longer than the average 3.17 years in Ophtec IOL receiving eyes here remains to be determined.

References:

1. Bardorf CM, Epley KD, Lueder GT et al. Pediatric transscleral sutured intraocular lenses: efficacy and safety in 43 eyes followed an average of 3 years. J AAPOS. 2004;8:318-24.
2. Konradsen T, Kugelberg M, Zetterstrom C. Visual outcomes and complications in surgery for ectopia lentis in children. J Cataract Refract Surg. 2007;33:819-24.
3. Buckley, EG. Hanging by a Thread: The Long-Term Efficacy and Safety of Transscleral Sutured Intraocular Lenses in Children (An American Ophthalmological Society Thesis). Trans Am Ophthalmol Soc 2007;105:294-311.

Poster #174
Saturday, 9:55 am – 10:55 am

FLEX-Module Optical Coherence Tomography (OCT) - Expanding the Reach of OCT in Evaluating Childhood Glaucoma

Navajyoti R. Barman, BS; Michelle S. Go, MD; Michael P. Kelly; Robert J. House, MD; Jill C. Rotruck, MD; Mays A. El-Dairi, MD; Sharon F. Freedman, MD

Department of Ophthalmology
Duke University Medical Center
Durham, NC

Introduction: Objective evaluation of glaucomatous optic neuropathy with OCT can be limited by very young age, inability to cooperate, or technical challenges. The HRA+OCT SPECTRALIS® with Flex module (FLEX-OCT, Heidelberg, Germany) allows supine imaging under anesthesia. This is the first study to describe its use and feasibility in imaging childhood glaucoma.

Methods: Childhood glaucoma patients undergoing examination under anesthesia and/or surgical intervention were included in this ongoing prospective study. FLEX-OCT imaging of the posterior pole was performed. Images were analyzed for peripapillary retinal nerve fiber layer (pRNFL), Bruch membrane opening (BMO), and macular pathology.

Results: FLEX-OCT successfully imaged 60 affected eyes in 41 of 47 (87.2%) enrolled patients (mean age 5.0±5.0, range 0.06-22.5 years). Imaging failure (8 eyes, 11.8%) was attributed to imager-learning(1), media opacity(3), and technical factors(4). We evaluated the pRNFL global thickness, BMO, and macular appearance for 60, 40, and 51 affected eyes, respectively (mean image quality 23.3 dB). Results were directly comparable to similarly-aged controls (mean pRFNL global thickness 83.4±33.1μm vs. 107.6±10.3μm, $p<0.001$, and mean BMO 1602±349μm vs. 1525±212μm, $p=0.55$ for affected vs. control eyes, respectively; under review). Macular pathology, present in 14 of 51 macular scans (27.5%), included abnormal foveal pit, epiretinal membrane, localized schisis, and paracentral acute middle maculopathy.

Discussion: FLEX-OCT allowed high-quality image acquisition and analysis comparable to tabletop OCT in patients who otherwise could not be imaged.

Conclusion: The future clinical application of FLEX-OCT is broad. Further studies may improve clinical management and understanding of childhood glaucoma-related pathophysiology.

References: El-Dairi, M. A., Holgado, S., Asrani, S. G., Enyedi, L. B., & Freedman, S. F. (2008). Correlation between optical coherence tomography and glaucomatous optic nerve head damage in children. British Journal of Ophthalmology,93(10), 1325-1330.

Poster #175
Saturday, 9:55 am – 10:55 am

Anterior Chamber Angle Features in Primary Congenital Glaucoma Using Hand-Held Anterior Segment-OCT

Dina El-Fayoumi, MD; Ghada Gawdat, MD; Amanne Esmael, MD; Weam Abdeen, MB, BCh

Kasralainy Pediatric Eye Hospital, Cairo University
Cairo, Egypt

Introduction: Gonioscopy is an indispensable technique to examine anterior chamber angle (ACA) structures however quantification requires ultrasound biomicroscopy (UBM) or optical coherence tomography (OCT). (1) We used Hand-held anterior segment OCT (HH-ASOCT), as a non-contact technique, to study (ACA) in primary congenital glaucoma (PCG) infants

Methods: A descriptive cross-sectional study was conducted on 48 eyes of normal and glaucomatous infants <24 months. Using HH-ASOCT corneal pachymetry map, ACA width and iris thickness (IT) were measured.Trabecular meshwork (TM), Schlemm's canal (SC), scleral spur (SS) identification were described.

Results: Twenty-six PCG-eyes were studied and compared to 22 normal-eyes (overall mean age 9.12± 6.7months). Nasal and temporal ACA width (39.3±6.6° vs. 30.4 ±5.6, and 40.1±5.3° vs. 32.5 ±6.2 respectively) were significantly larger ($p< 0.001$) and IT was significantly reduced ($p<0.01$). TM was identified in all normal eyes (100%) and 9 (34.6%) PCG-eyes. SC was identified in 16 (72.7%) normal eyes versus 4(15.4%) PCG. Abnormal structure occluding the angle was seen in 7(26.9%), and a hyper-reflective membrane in 5(19.2%) PCG-eyes. Iris was anteriorly inserted in all PCG-eyes

Discussion: Iridotrabeculodysgenesis was clearly identified (with constant iris anterior insertion) in PCG using HH-ASOCT. Iris thinning appeared to be part of the pathology not a result of IOP elevation. The abnormal tissue obscuring the angle was seen in PCG infants of smaller age.

Conclusion: Using HH-ASOCT permits thorough examination of the ACA in PCG infants, and helps in understanding the pathophysiology of the disease.

References: 1- C K-S Leung and R N Weinreb. Anterior chamber angle imaging with optical coherence tomography. Eye (Lond). 2011 Mar; 25(3): 261-267.

Poster #176
Saturday, 9:55 am – 10:55 am

Structural Changes of the Ciliary Body and Ciliary Processes Measured by Ultrasound Biomicroscopy of Primary Congenital Glaucoma in Comparison to Glaucoma Following Congenital Cataract Surgery

Laura Andrews, MD[1]; Laura Kueny, MD[1]; Camilo Martinez, COA[1]; Joy Li[2]; Adrianna Lee[2]; Osamah Saeedi, MD[2]; Moran Roni Levin, MD[2]; Mona Kaleem, MD[2]; Bethany Karwoski, MD[1]; Marlet Bazemore, MD[1]; Marijean Miller, MD[1]; Mohamad Jaafar, MD, FACS, FAAP[1]; Janet Leath Alexander, MD[2]; William P. Madigan, MD, FACS, FAAP[1]

1. Children's National Medical Center 2. University of Maryland

Introduction: Glaucoma is an important cause of pediatric blindness. Our study aims to better understand ciliary body structural parameters and differences in patients with Primary Congenital Glaucoma (PCG) and Glaucoma Following Congenital Cataract Surgery (GFCCS).

Methods: This is an ongoing prospective comparative study conducted at Children's National Medical Center and University of Maryland comparing patients with PCG and GFCCS undergoing exam under anesthesia. Eyes without any ocular pathology are used for comparison. Longitudinal ultrasound biomicroscopy (UBM) was performed for all patients. Image analysis was performed using ImageJ software to measure 6 structural parameters of the ciliary body (CB) and ciliary processes (CP).

Results: 9 PCG eyes and 6 GFCCS eyes were compared to 25 control eyes. CP integrated density and CP area were significantly lower in patients with glaucoma compared to controls ($p = .0428$ and 00485, respectively). PCG CP thickness and CP integrated density were also significantly lower in comparison to GFCCS ($p = .0041$ and .000024 respectively). However, CB thickness was significantly lower in patients with GFCCS compared to PCG ($p = .01129$).

Discussion: Our study demonstrates quantifiable differences between the CB and CP in patients with PCG in comparison to both normal eyes and GFCCS. Quantifying the anatomical variance of the CB and CP in patients with pediatric glaucoma opens opportunity to better understand these disease processes.

Conclusion: UBM can be used to better understand the anatomy of patients with pediatric glaucoma. A better understanding of anatomical and structural changes may help guide therapeutic surgical approaches to these diseases.

References:

Poster #177
Saturday, 9:55 am – 10:55 am

Structural Changes of the Anterior Segment Measured by Ultrasound Biomicroscopy in Pediatric Glaucoma

Laura S. Kueny, MD; Laura Andrews, MD; Camilo Martinez; Adrianna Lee; Joy Li; Mohamad S. Jaafar, MD; Janet L. Alexander, MD; William P. Madigan, MD; Roni Levin; Osamah Saeedi; Mona Kaleem

Children's National Medical Center and University of Maryland
Washington, DC and Baltimore, MD

Introduction: Pediatric glaucoma (PG) is a rare and visually devastating disease. The aim of our study is to better quantify the anterior segment (AS) structures of patients with PG using ultrasound biomicroscopy (UBM).

Methods: This is a multicenter prospective comparative study conducted at Children's National Medical Center and University of Maryland. Patients with PG undergoing an exam under anesthesia prior to intraocular surgery were assessed. Eyes without any ocular pathology were used for comparison. Exclusion criteria included prior intraocular surgery, ocular trauma, or any other anterior or posterior segment abnormalities. Longitudinal UBM was completed in all patients and image analysis was performed using ImageJ software to measure 21 structural parameters of the AS.

Results: 20 eyes with PG were identified, 17 eyes were measured as controls. 9 of the 21 structural parameters measured were found to be statistically significant between the two groups. These parameters include: angle to angle distance (AA), Central Corneal Thickness (CCT), AA to CCT distance, scleral spur to CCT distance, central corneal integrated density, scleral integrated density, and post corneal radius of curvature.

Discussion: Patients with PG exhibit increased anterior chamber size, thicker CCT, less dense cornea and sclera, and a flatter anterior chamber. Improved understanding of the AS structural parameters of PG may eventually allow us to modify surgical techniques to best fit each individual patient.

Conclusion: UBM is a powerful tool that can be used to better understand the anatomy of PG and has the potential to assist in the surgical management of PG.

References:

Poster #178
Saturday, 9:55 am – 10:55 am

Comparison of Vessel Density in Eyes of Children with Juvenile Open Angle Glaucoma and Healthy Age-Matched Controls: An Optical Coherence Tomography Angiography Study

Carmel L. Mercado, MD; Liang Liu, MD; Beth Edmunds, MD, PhD; J. Peter Campbell, MD, MPH; David Huang, MD, PhD; Allison Loh, MD

Oregon Health & Science University
Portland, OR

Introduction: Optical Coherence Tomography Angiography (OCTA) allows for rapid, noninvasive imaging of the peripapillary and macular microvasculature. The purpose of this study is to evaluate optic disc and macular perfusion using OCTA in juvenile open angle glaucoma (JOAG).

Methods: Case-control study of OCTA findings in children with JOAG compared to healthy controls in a hospital-based sample. The AngioVue SD-OCT system was used to obtain 6x6mm high-definition AngioDisc scans of the macular vasculature and peripapillary vasculature centered over the optic disc. The merged 3-D OCT angiograms were then exported for superficial vascular complex vessel density (SVC-VD) and nerve fiber layer plexus capillary density (NFLP CD) measurements using custom software. NFLP-CD was calculated using a smaller 5.5x5.5 mm square. Non-parametric Wilcoxon-Mann-Whitney test was used for statistical analysis.

Results: 20 subjects were identified, 5 with JOAG and 15 controls. Mean age was 11.4±1.2 years for the glaucoma patients and 11.1±0.7 years for the controls. Macular SVC-VD was reduced in the glaucoma patients (51.3±3.2%) compared to the controls (58.4±1.0%) (P= 0.03). NFLP-CD was also decreased in the glaucoma patients (51.9±1.1%) compared to controls (58.8±1.7%) (P= 0.05).

Discussion: OCTA showed decreased peripapillary and macular perfusion in the JOAG group compared to controls although the sample size was small.

Conclusion: OCTA in children with glaucoma is feasible and encouraging as a potential noninvasive evaluation technique in children. Further investigations are needed.

References: Liu L, Jia Y, Takusagawa HL, et al. Optical Coherence Tomography Angiography of the Peripapillary Retina in Glaucoma. JAMA Ophthalmol. 2015;133(9):1045-1052.
Jia Y, Wei E, Wang X, et al. Optical coherence tomography angiography of optic disc perfusion in glaucoma. Ophthalmology. 2014;121(7):1322-1332.
Leveque PM, Zeboulon P, Brasnu E, Baudouin C, Labbe A. Optic Disc Vascularization in Glaucoma: Value of Spectral-Domain Optical Coherence Tomography Angiography. J Ophthalmol. 2016;2016:6956717.

Poster #179
Saturday, 9:55 am – 10:55 am

The Relationship Between Retinal Nerve Fiber Layer Thickness and Optic Nerve Cupping in Pediatric Patients with Large Optic Nerve Cup-to-Disc Ratios

Mehmet C. Mocan, MD; Inae Jang; Lindsay Machen, MD

Department of Ophthalmology and Visual Sciences, University of Illinois at Chicago
Chicago, IL

Introduction: Optic nerve cupping is a source for concern for a glaucomatous process in pediatric patients. The aim of this study was to evaluate the peripapillary retinal nerve fiber layer (RNFL) in pediatric glaucoma suspects who presented with large cup-to-disc ratios (CDR).

Methods: This was a retrospective study undertaken at a single academic setting. Pediatric patients between the ages of 5-15 years who were diagnosed as glaucoma suspects based on a large (≥0.7) CDRs but without evidence of elevated intraocular pressure (IOP) in either eye were included in the study. RNFL thickness measurements were performed by spectral-domain optical coherence tomography (SD-OCT) device (Spectralis® OCT, Heidelberg, Germany). Patient demographic data, ophthalmologic examination findings, and RNFL measurements were included for analysis.

Results: Twenty-five eyes of 15 patients (9M/6F) with a mean age of 9.0±3.6 years were evaluated. The mean CDR was 0.73±0.04, the mean IOP was 15.6±3.2 mmHg and the mean refractive error was 0.12±2.02 diopters. RNFL thickness was similar between males (101.4±13.6 microns) and females (98.0±8.3 microns) (p=0.479). There was no correlation between CDRs and the average RNFL thickness (r=0.143; p=0.946) of study subjects. A trend towards moderate correlation was observed between average RNFL thickness and refractive error (r=0.396; p=0.055).

Discussion: There is no correlation between CDR and RNFL in pediatric glaucoma suspect patients who present with large (≥0.7) optic nerve cups and whose IOPs are not elevated.

Conclusion: RNFL thickness evaluation in pediatric glaucoma suspects who present with large CDRs may assist in ruling out a glaucomatous process.

References: Kooner K, Harrison M, Prasla Z, Albdour M, Adams-Huet B. Pediatric glaucoma suspects. Clin Ophthalmol. 2014;8:1139-45.

El-Dairi M, Holgado S, Asrani S, Freedman SF. Optical coherence tomography (OCT) measurements in black and white children with large cup-to-disc ratios. Exp Eye Res. 2011;93(3):299-307.

Silverstein E, Freedman S, Zéhil GP, Jiramongkolchai K, El-Dairi M. The macula in pediatric glaucoma: quantifying the inner and outer layers via optical coherence tomography automatic segmentation. J AAPOS. 2016;20(4):332-6.

Poster #180
Saturday, 9:55 am – 10:55 am

Canaloplasty-Trabeculotomy: A Novel Approach to Pediatric Glaucoma of Various Etiology

Lydia Matkovich, MD

Lydia Matkovich, MD (private practice)
23600 Telo Ave, Suite 210, Torrance, CA 90505

Introduction: To determine if Canaloplasty-trabeculotomy (CT) reduced intraocular pressure (IOP) in pediatric glaucoma patients of various etiology.

Methods: Chart data for 10 eyes diagnosed with pediatric glaucoma who underwent modified canaloplasty where the itrack probe was circumnavigated through Schlemm's canal and drawn to create a trabeculotomy were reviewed. IOP data were analyzed at 3 months and every 6 months (if available) postoperatively. This glaucoma cohort comprised 1 Peter's Anomaly, 1 primary congenital, 2 juvenile, 3 aphakic, and 3 s/p previous goniotomy (>8 years prior to surgery) eyes.

Results: Average preoperative IOP was 38, with an average IOP reduction to 16 (56%) at both 3 and 6 months, 13 (65%) at 1 year, and 17 (53%) at both 2 years (6 eyes) and 3.5 years (4 eyes) post-surgery. 2 eyes required glaucoma medications and 1 eye underwent G6MP3 laser treatment 2 years postop.

Discussion: Even in this small sample size due to low pediatric glaucoma incidence, a 56% reduction in IOP maintained up to 3.5 years postoperatively (glaucoma medication-free in 8/10 cases) is significant. Sutureless 360-degree trabeculotomy via canaloplasty has not been studied extensively, may be easier to perform and more effective with fewer complications than suture or traditional trabeculotomy. A long-term study with larger sample size is needed to examine this combined procedure's applications and effects.|

Conclusion: Canaloplasty-Trabeculotomy(CT) can reduce intraocular pressure in various forms of pediatric glaucoma, and should be considered in the surgical approach to pediatric glaucoma cases, regardless of previous goniotomy, trabeculotomy or cataract surgery.|

References: 1.Morales, Jose & Alshahwan, Sami & Al Odhayb, Sami & Aljadaan, Ibrahim & P Edward, Deepak. (2013). Current Surgical Options for the Management of Pediatric Glaucoma. Journal of ophthalmology. 2013. 763735. 10.1155/2013/763735.
2.E Neely, Daniel. (2005). False Passage: A Complication of 360° Suture Trabeculotomy. Journal of AAPOS : the official publication of the American Association for Pediatric Ophthalmology and Strabismus / American Association for Pediatric Ophthalmology and Strabismus. 9. 396-7. 10.1016/j.jaapos.2005.05.003.
3.Beck, Allen & J Lynn, Michael & Crandall, James & Mobin-Uddin, Omar. (2011). Surgical outcomes with 360-degree suture trabeculotomy in poor-prognosis primary congenital glaucoma and glaucoma associated with congenital anomalies or cataract surgery. Journal of AAPOS : the official publication of the American Association for Pediatric Ophthalmology and Strabismus / American Association for Pediatric Ophthalmology and Strabismus. 15. 54-8. 10.1016/j.jaapos.2010.12.002.

Poster #181
Saturday, 9:55 am – 10:55 am

Micropulse Laser for Glaucoma in Children

Krupa H. Patel, MD; Kathryn M. Haider, MD; Charline S. Boente, MD; Daniel E. Neely, MD; Heather A. Smith, MD; David A. Plager, MD; George Eckert, MAS

Riley Hospital for Children at Indiana University Health
Indianapolis, Indiana

Introduction: The purpose of this study is to evaluate our early experience with micropulse laser for glaucoma in children from Riley Hospital for Children at Indiana University Health.

Methods: A retrospective chart review was performed collecting the following data: age of presentation, glaucoma diagnosis, previous ocular surgeries, previous glaucoma surgeries, preoperative medications, preoperative intraocular pressure (IOP), age at procedure, details of the procedure, and postoperative IOP.

Results: There were 20 eyes of 15 patients included in this study. The mean age at presentation was 4.4 years (range 2 days to 16.3 years) and age at procedure 8.2 years (range 4 months to 18 years). Average preoperative IOP was 36.3 (range 23 to 52). Postoperatively, at 1 week the mean IOP was 20.8. At 4 weeks post op, mean IOP was 27, at 8 weeks mean IOP was 27.7, and 12 weeks mean IOP was 16.0. The data was analyzed via a paired T-test.

Discussion: With a p-value of 0.05, intraocular pressure was lowered significantly at the 1 week post operative visit and the 12 week post operative visit. The variability at post operative visits were secondary to the small sample size. We will have updated data by the time of presentation in March.

Conclusion: At this point, it has been determined that this procedure has been safe in the short term. A larger sample size and longer follow-up is needed for determination of long-term efficacy.

References: Kuchar, S., Moster, M.R., Reamer, C.B. et al. Lasers Med Sci (2016) 31: 393. https://doi.org/10.1007/s10103-015-1856-9.

Poster #182
Saturday, 9:55 am – 10:55 am

Biomechanical Analysis of Ligatures and Technique for Managing Drainage Tubes in Pediatric Glaucoma

Carolina Adams, MD; Steven Kane, MD, PhD; Steven Brooks, MD

Columbia University Medical Center
New York City

Introduction: Absorbable ligatures are often used with glaucoma drainage tubes to avoid early postoperative hypotony. We sought to measure the force required to ligate a drainage tube, and develop a modified technique to promote earlier release in pediatric patients, where plate encapsulation occurs more quickly than adults.

Methods: A precision digital force gauge was used to measure the tensile strength of several common ophthalmic sutures, and the necessary tensile force required to achieve tube ligation. A novel technique for tube ligation was devised to allow sutures as small as 10-0 to be effectively used.

Results: The mean tensile strengths of unknotted sutures varied from 211g $\pm$ 127g for 10-0 vicryl to 477g $\pm$ 69g for 6-0 chromic gut. The mean tensile force required to ligate a Baerveldt or Ahmed tube was 35.9g $\pm$ 0.9g. However, 9-0 or 10-0 vicryl could not be reliably used for ligation, due to breakage, unless a modified technique was employed, wherein the tube was first stretched to reduce its thickness and diameter.

Discussion: Frictional forces inherent to knot tying make it unfeasible to reliably use 9-0 or 10-0 vicryl to ligate a drainage tube, despite the unknotted threads possessing apparently sufficient tensile strength. Our modified ligation technique overcomes this issue, allowing a wider range of suture choices, and the potential for achieving more rapid release in pediatric cases.

Conclusion: A novel modification in technique allows the use of very small guage sutures to ligate tubes in glaucoma drainage implants, allowing for potentially faster release times that may be favorable in managing pediatric glaucomas.

Poster #183
Saturday, 9:55 am – 10:55 am

Glaucoma Drainage Device Surgery for Refractory Childhood Glaucoma - Safely Managing the Short Eye

HongVan T. Le, MD; Ann Shue, MD; Sharon Freedman, MD

Department of Ophthalmology, Duke University Medical Center

Durham, NC

Introduction: Treatment of refractory childhood glaucoma often includes glaucoma drainage device (GDD) implantation, with little reported on GDD modification for short eyes. Purpose: 1) to determine the frequency of GDD plate trimming/modification for short eyes; and 2) to quantify axial length changes following intraocular pressure (IOP) reduction after GDD implantation in young children (≤3yo).

Methods: Retrospective study of consecutive GDD implantation in childhood glaucoma patients ≤18yo at surgery, from 2013-2018, under one attending surgeon. Data collected included demographics, glaucoma diagnoses, prior surgeries, surgical details, and axial length and IOP data pre- and post-GDD implantation for children ≤3yo.

Results: Included were 132 eyes (72 OD/60 OS), of 110 patients (58 male/52 female). Glaucoma diagnoses included: primary congenital (40,30%), post-cataract removal (38,29%), Sturge-weber related (15,11%), and other (39,30%). In all, 157 GDDs were implanted (Baerveldt-250 (73,46%), Ahmed-FP7 (53,34%), Baerveldt-350 (30,19%), Ahmed-FP8 (1,0.6%). GDDs modification occurred in 26(16%) cases/22 eyes, with mean axial length 21.17 mm (range 19.47-24.18). GDD plates were trimmed by mean 2.3 mm (range 0.5-6.5); GDD placement was superotemporal in 16(62%) and inferonasal in 10(38%). In children ≤3yo (n=10) at GDD implantation, mean post-GDD axial length reduction was 0.80±0.85mm (range:-3.1 to +0.59, $p=0.002$), with mean IOP reduction 15±6.7mmHg, $p<0.0001$), measured at mean 1.8 mos post-GDD.

Discussion: Among children having GDD implantation for glaucoma, modifications for short axial length are not rare. Eyes of young children can further shorten with successful GDD-related IOP reduction.

Conclusion: Axial length determination and appropriate short-eye modifications are important considerations when implanting GDDs in children.

References: 1. Margeta MA, Kuo AN, Proia AD, Freedman SF. Staying away from the optic nerve: a formula for modifying glaucoma drainage device surgery in pediatric and other small eyes. J AAPOS. 2017 Feb;21(1):39-43.e1. doi: 10.1016/j.jaapos.2016.09.027. Epub 2017 Jan 16.

2. Law SK, Bui D, Caprioli J. Serial axial length measurements in congenital glaucoma. Am J Ophthalmol 2001; 132:926-928.

Poster #184
Saturday, 9:55 am – 10:55 am

Long Term Outcomes of Baerveldt Glaucoma Implant (BGI) in Management of Glaucoma Following Congenital Cataract Surgery (Gf-CCS)

Jane Ashworth, FRCOphth, PhD; Siddharth Agrawal, MS, FRCOphth; Bhamy Hariprasad Shenoy, MS, FICO, FRCOphth; Susmito Biswas, FRCOphth; Cecilia Fenerty, MD, FRCOphth

Manchester Royal Eye Hospital
Manchester, UK

Introduction: Glaucoma is the most common vision threatening complication following congenital cataract surgery. Previous studies have shown Glaucoma Drainage Implants (GDI) to be relatively safe in management of paediatric glaucoma including Gf-CCS. These studies have been limited by small sample size and limited follow-up. Aim of this study was to assess long-term outcomes of BGI in management of Gf-CCS.

Methods: Retrospective interventional case series of children <16 years who underwent BGI for Gf-CCS. Age at cataract surgery <12 months and minimum post-BGI follow-up of 1 year was essential for inclusion.

Results: Forty-seven eyes of 41 patients (6 bilateral, 35 unilateral) were analysed. Mean age at cataract surgery was 10.1 10 weeks. Mean age at glaucoma diagnosis was 16.7 20.3 months. Mean age at BGI surgery was 47.3 55.8 months. 39 eyes were aphakic and 8 were pseudophakic. Mean IOP reduced from 29.96 4.75 mmHg pre-operatively to 15.1 5.15 mmHg at the last follow-up (p=0.000). Mean no.of glaucoma medication reduced from 2.9 1.02 pre-operatively to 0.94 1.04 at the last follow-up (p=0.0000). Mean duration of follow-up was 73.85 56.7 months (range 12-193 months). One eye developed retinal detachment during the follow-up and resulted in no light perception vision. IOP<21mmHg was maintained in 91.5% eyes at the last follow-up.

Discussion: Current study demonstrates that BGI results in effective control of IOP in children with refractory Gf-CCS. This study benefits from being the largest series with longest mean duration of follow-up.

Conclusion: BGI is a relatively safe and effective procedure for managing Gf-CCS in children and may be considered as the primary intervention in these cases.

References: 1.Freedman SF, Lynn MJ, Beck AD et al. Infant aphakia treatment study group. glaucoma- related adverse events in the first 5 years after unilateral cataract removal in the infant aphakia treatment study. JAMA Ophthalmol. 2015; 133:907-914
2.Kirwan C, Lanigan B, O'Keefe M. Glaucoma in aphakic and pseudophakic eyes following surgery for congenital cataract in the first year of life. Acta Ophthalmol. 2010; 88:53-59
3.Mandal AK, Bagga H, Nutheti R, Gothwal VK, Nanda AK. Trabeculectomy with or without mitomycin-C for pediatric glaucoma in aphakia and pseudophakia following congenital cataract surgery. Eye. 2003; 17:53-62

Poster #185
Saturday, 9:55 am – 10:55 am

Baerveldt Glaucoma Implant after Strabismus Surgery - What to do When a Muscle is Recessed

Ann Shue, MD; HongVan Le, MD; Sharon F. Freedman, MD

Department of Ophthalmology, Duke University Medical Center
Durham, NC

Introduction: The non-valved Baerveldt glaucoma implant (BGI), a mainstay for surgical management of refractory childhood and adult glaucoma, has two wings intended for placement under respective adjacent rectus muscles. Purpose: to describe a newly-developed BGI implantation technique in eyes with prior strabismus surgery.

Methods: Retrospective chart review of consecutive glaucoma drainage device (GDD) implantations in patients ≤18yo at surgery, from 2013-2018, under one attending surgeon. Data collected included demographics, prior surgeries, and surgical details. Eligible eyes had prior strabismus surgery, and subsequent BGI modification to accommodate a recessed muscle adjacent to the quadrant chosen for implantation. BGI modification entailed calculated trimming of the relevant anterior wing, allowing secure placement behind the recessed muscle. BGI wing trim magnitude was calculated as ∆[distance from limbus to recessed muscle - desired BGI distance from limbus].

Results: 135 eyes of 114 childhood glaucoma patients underwent 160 total GDD implantations (107, 66.9% BGIs); 17 eyes (12.6%) had previous strabismus surgery. Of these, 4 eyes (23.5%) of 4 children (ages 1-17yrs) had previously recessed rectus muscles affecting BGI implantation (3 lateral rectus/superotemporal BGI, 1 medial rectus/inferonasal BGI). All four BGIs were successfully trimmed (maximum 9mm) and placed behind respective recessed muscles without peri- or post-operative complication, or unsightly anterior bleb formation.

Discussion: Prior strabismus surgery occurs in ~13% of children requiring GDDs, and may necessitate surgical modification to allow secure BGI placement.

Conclusion: Prior strabismus surgery warrants consideration when planning BGI surgery in childhood (and adult) glaucoma. Anterior plate trimming constitutes a simple and safe BGI modification.

References: Budenz DL, Gedde SJ, Brandt JD, Kira D, Feuer W, Larson E. Baerveldt glaucoma implant in the management of refractory childhood glaucomas. Ophthalmology. 2004;111:2204-10.

Poster #186
Saturday, 9:55 am – 10:55 am

Psychosocial Functioning in Parents of Patients with Retinoblastoma

[1]Jana A. Bregman, MD; [1]Mary Louise Z. Collins, MD; [2]Carol L. Shields, MD; [2]Rachel Schewndeman; [2]Chloe Koo; [2]Elizabeth Elimimian; [3]Jennifer Ford, PhD

[1]Greater Baltimore Medical Center, Baltimore, MD
[2]Wills Eye Hospital, Philadelphia, PA
[3]Hunter College & The Graduate Center, CUNY, NY, New York

Introduction: Prior work has established that parents of children with chronic illness suffer from higher levels of stress. However, few studies have examined the psychological health of parents of patients with ocular conditions, and none in retinoblastoma. This study examines stress, anxiety, and depression in parents of children with retinoblastoma.

Methods: Longitudinal, self-reported, study using validated instruments: Parental Stress Index 4 - Short Form (PSI-4), Beck Anxiety Inventory (BAI), and Beck Depression Inventory - II (BDI-II). Knowledge Assessment (KA) and demographic forms were also administered to each parent (or legal guardian) at study enrollment and at 6 months post-enrollment.

Results: Of 121 study participants to date, 60% have children with unilateral disease and 23.7% were diagnosed within 6 months of enrollment. PSI-4 scores were significantly higher in cases of parental depression ($p<0.05$ and child developmental delay ($p<0.01$). A trend towards higher PSI-4 scores resulted with more time since treatment ($p=0.058$). BDI-II scores were significantly higher in the bilateral group ($p<0.05$). Overall KA scores were significantly lower in the bilateral group ($p<0.05$) with a majority incorrectly answering questions regarding risk of second malignant neoplasms and heritability ($p<0.05$ for both). An analysis of 6-month data is ongoing and will also be included.

Discussion: This study is the first to perform a longitudinal analysis of a comprehensive look at stress, anxiety and depression in parents of children with both newly diagnosed and treated retinoblastoma.

Conclusion: Both parent and patient factors impact stress and depression levels in parents of patients with retinoblastoma. Important retinoblastoma knowledge is lacking in certain patient subgroups. Ophthalmologists caring for retinoblastoma patients need to be aware of these risk factors to optimally care for their patients and families.

References: 1. Ford J, Chou J, Sklar C et al. Psychosocial outcomes in adult survivors of retinoblastoma. J Clin Oncology. 2015;33:3608-3614.
2. MacDonald D and Lessick M. Hereditary cancers in children and ethical and psychosocial implications. J Pediatric Nursing. 2000; 15: 217-225.
3. Nahum MGdal-On MKuten A et al;. Long-term follow-up of children with retinoblastoma. Pediatric Hematology and Oncology. 2001;18:173-179.

Poster #187
Saturday, 9:55 am – 10:55 am

Retinal Mapping of Heritable Retinoblastoma

Stefan J. Langenegger; Sameh E. Soliman; Brenda L. Gallie

Dept. of Ophthalmology and Vision Sciences, The Hospital for Sick Children
Toronto, Canada

Introduction: Accurate diagnosis of retinoblastoma is crucial to develop a proper treatment plan, especially in limited resource settings. Retinal imaging facilitates the exchange of clinical findings to assist management.

Methods: We developed a scalable graphics tool that can be enlarged, rotated and overlaid onto fundus images (Microsoft PowerPoint). Scaling and orientation of the tool are defined by matching the optic nerve center and the fovea. Zone A refers to a circular zone centred on the optic disc with a diameter twice the distance to the fovea. Zone C refers to peripheral retina only seen with indentation. Zone B extends between both zones. All zones are divided into quadrants (S, N, I, T) by lines extending from the central zone to the periphery. The temporal quadrant of zone A is subdivided by the ETDRS grid to assess visually most threatening lesions.

Results: Fundus images from 68 eyes of 54 patients with retinoblastoma were assessed using this tool by two independent reviewers and verified by a third reviewer. 228 tumors were mapped to zones according to location of the tumour center at first tumor diagnosis. The mapping was reproducible with >95% inter-observer agreement across image modalities.

Discussion: This mapping tool requires minimal training and a rapid learning curve with precise reproducible tumor localization independent of image acquisition skill or camera. Furthermore, proper tumor localization can contribute to the understanding of the spatiotemporal evolution of heritable tumors.

Conclusion: This tool has the potential to improve treatment and follow-up decisions based on image exchange or Telemedicine.

References: 1. Abramson DH, Gombos DS. The topography of bilateral retinoblastoma lesions. Retina (Philadelphia, Pa). 1996;16(3):232-9.
2. Munier FL, Balmer A, Melle G van, Gailloud C. Radial asymmetry in the topography of retinoblastoma Clues to the cell of origin. Ophthalmic Genetics. 1994 Jan;15(3-4):101-6.

Poster #188
Saturday, 9:55 am – 10:55 am

An Intraocular Pressure Predictive of High-Risk Histopathologic Features in Group E Retinoblastoma Eyes

Mary E. Kim, BA; Sona Shah, BS; Emily Zolfaghari, MS; Rima Jubran, MD; Mark W. Reid, PhD; Jonathan W. Kim, MD; Jesse L. Berry, MD

The Vision Center at Children's Hospital Los Angeles
Los Angeles, CA

Introduction: To determine the intraocular pressure (IOP), with or without neovascularization of the iris (NVI), that most accurately predicts the presence of high-risk histopathologic features, including post-laminar optic nerve invasion, massive choroidal invasion, and extra-scleral invasion.

Methods: A retrospective chart review was done on 118 enucleated Group E eyes with numerical IOP recorded at diagnosis and documentation of high-risk histopathologic features.

Results: The mean IOP at diagnosis for eyes with high-risk pathology (31.8 mmHg) was significantly higher than the mean IOP at diagnosis for eyes without high-risk pathology (24.5 mmHg) ($p = 0.0031$). An IOP cutoff value of 34 mm Hg optimizes specificity (82.4%) in predicting the presence of high-risk histopathologic features, as eyes with an IOP >= 34 mmHg at diagnosis were 5.91 times more likely to have high-risk histopathologic features than those with an IOP < 34 mmHg at diagnosis. Furthermore, having an IOP >= 34 mmHg at diagnosis was more predictive of high-risk histopathology than either the presence or absence of NVI.

Discussion: Whether or not NVI occurs, eyes with an IOP >= 34 mmHg at diagnosis are 5.91 times more likely to have high-risk histopathologic features than eyes with an IOP below this value. Thus, any attempts at salvage for these eyes may predispose the child to unnecessary metastatic risk.

Conclusion: Because high-risk histopathologic features increase risk for metastasis, recognizing them at time of diagnosis is beneficial. Clinicians can use this predictive information to better formulate their treatment plans and decisions regarding the safety of attempting eye salvage for advanced eyes.

References: 1. Kaliki S, Srinivasan V, Gupta A, Mishra DK, Naik MN. Clinical features predictive of high-risk retinoblastoma in 403 Asian Indian patients: a case-control study. Ophthalmology. 2015 Jun 30;122(6):1165-72.
2. Kaliki S, Shields CL, Rojanaporn D, Al-Dahmash S, McLaughlin JP, Shields JA, Eagle RC. High-risk retinoblastoma based on international classification of retinoblastoma: analysis of 519 enucleated eyes. Ophthalmology. 2013 May 31;120(5):997-1003.
3. Chawla B, Sharma S, Sen S, Azad R, Bajaj MS, Kashyap S, Pushker N, Ghose S. Correlation between clinical features, magnetic resonance imaging, and histopathologic findings in retinoblastoma: a prospective study. Ophthalmology. 2012 Apr 30;119(4):850-6.

Poster #189
Saturday, 9:55 am – 10:55 am

Histopathologic Findings After Selective Ophthalmic Arterial Injection (SOAI) of Melphalan for Retinoblastoma

Ho-Min Chen, MD; Sherine J. Ong, MD; An-Ning Chao, MD; Kuan-Lyin Liou, MD; Shih-Ming Jung, MD; Ling-Yuh Kao, MD

Department of Ophthalmology, Chang Gung Memorial Hospital, Keelung, Taiwan
Taiwan

Introduction: To describe histopathologic observations in eyes enucleated after selective ophthalmic arterial injection (SOAI) of melphalan for retinoblastoma (Rb)

Methods: Histopathologic analysis of 14 eyes (13 patients) from May 2008 through January 2015 at Chang Gung Memorial Hospital.

Results: The eyes after SOAI were enucleated due to tumor viability (n=7, 2 with vitreous hemorrhage), neovascular glaucoma (n=4), lens drop to vitreous with total hyphema and elevated intra-ocular pressure (n=1), retinal detachment progressed (n=1) and persistent retinal detachment with phthisis change (n=1). Almost all of the eyes showed vitreous seeding (n=11 eyes) before treatment. After the treatment of SOAI , the histopathological examination revealed complete regression in 4 eyes with one was clinically diagnosed as viable tumor and progression, one with retinal detachment progression and two as neovascular glaucoma. Six eyes showed invasion into the optic nerves, reaching the lamina cribrosa in 5 eyes, and 6 eyes with invasion into the choroid were observed. All of the cases with lamina cribrosa involvement showed tumor progression before enucleation, 4 cases with lamina cribrosa involvement expired later.

Discussion: The cause of enucleation in our cases were related to SOAI complications, recurred vitreous and subretinal seedings or tumor progression. Treating advanced cases ICRB Gr D or E, repetitive SOAI with prolonged treatment course sometimes could increase the risk of metastasis.

Conclusion: Although retinoblastoma can be controlled effectively with SOAI, but for refractory cases after SOAI, earlier decision of enucleation may be needed.

References: 1. Chen YH, Lin HY, Hsu WM, et al. Retinoblastoma in Taiwan: incidence and survival characteristics from 1979 to 2003. Eye (London, England) 2010;24:318-22.
2. Yamane T, Kaneko A, Mohri M. The technique of ophthalmic arterial infusion therapy for patients with intraocular retinoblastoma. International J of Clin Oncol. 2004;9:69-73.
3. Abramson DH, Dunkel IJ, Brodie SE, et al. A phase I/II study of direct intraarterial (ophthalmic artery) chemotherapy with melphalan for intraocular retinoblastoma initial results. Ophthalmology. 2008;115:1398-404, 404.e1.

Poster #190
Saturday, 9:55 am – 10:55 am

Posterior Vitreous Detachment and the Associated Risk of Retinal Toxicity with Intravitreal Melphalan Treatment for Retinoblastoma

John R. O'Fee, BS; Jesse L. Berry, MD; Ramon Lee, MD; Luv Patel, MD; Bao Han A. Le, BS; Rima Jubran, MD, MPH, MACM; Jonathan Kim, MD

USC Roski Eye Institute
Los Angeles, CA

Introduction: Intravitreal melphalan (IVM) has been introduced as a safe and effective treatment modality for vitreous seeding, but studies have demonstrated this new modality has dose-dependent toxicity on retinal pigment epithelial cells.[1-3] It has been hypothesized that the presence of a posterior vitreous detachment (PVD) may play a role in the development of retinal toxicity. We evaluated the incidence of PVDs in retinoblastoma eyes and correlated the presence of PVD with risk of developing retinal toxicity secondary to IVM for vitreous seeding.

Methods: We reviewed 112 eyes of 81 retinoblastoma patients with B-scan images available for review from 2010 to 2017. A cohort with vitreous seeding treated with IVM was compared to a cohort that did not undergo injection. Primary outcome measure was the presence of PVD at diagnosis and after treatment. Secondary measures included IVM-associated retinal toxicity and other ocular complications.

Results: The incidence of PVD was 20% at diagnosis, and in eyes with B-scans available both at diagnosis and after treatment 18% of eyes developed a PVD over the course of therapy, more frequently after IVM ($p=0.05$). Of 34 eyes receiving IVM treatment, the incidences of posterior segment toxicity and globe salvage were similar between eyes with and without PVD ($p = 0.4015$ and 0.52, respectively).

Discussion: In this cohort of patients, there appears to be no association with the presence of PVD during IVM and the development of retinal toxicity.

Conclusion: More research is required to better understand the risk factors for the development of posterior toxicity post IVM injection.

References: [1] Munier FL, Soliman S, Moulin AP, Gaillard MC, Balmer A, Beck-Popovic M. Profiling safety of intravitreal injections for retinoblastoma using an anti-reflux procedure and sterilisation of the needle track. Br J Ophthalmol. 2012;96:1084-7.
[2] Aziz HA, Kim JW, Munier FL, Berry JL. Acute Hemorrhagic Retinopathy following Intravitreal Melphalan Injection for Retinoblastoma: A Report of Two Cases and Technical Modifications to Enhance the Prevention of Retinal Toxicity. Ocul Oncol Pathol. 2017;3:34-40.
[3] Munier FL. Classification and management of seeds in retinoblastoma. Ellsworth Lecture Ghent August 24th 2013. Ophthalmic Genet. 2014;35:193-207.

Poster #191
Saturday, 9:55 am – 10:55 am

Practice Patterns Changes in the Treatment of Retinopathy of Prematurity

Joyce Khandji; Gerard Barry; Graham Quinn; Yinxi Yu; Lauren A. Tomlinson; Gui-shuang Ying; Gil Binenbaum;
on behalf of the G-ROP Study

The Children's Hospital of Philadelphia
Philadelphia, PA

Introduction: There are limited patient-level data describing ROP-treatment-modality preferences. We sought to describe recent ophthalmologist practice patterns for ROP treatment choice and identify changes over the past decade.

Methods: We used detailed North American ROP screening data from two G-ROP-studies: G-ROP-1 retrospective data at 29 hospitals from 2006-2012; G-ROP-2 prospective data at 41 hospitals during 2015-2017. Outcomes included treatment type and ROP diagnosis at treatment.

Results: Treatment rates were similar in G-ROP-1 (514/7483 (6.9%) infants, 1008 eyes) and G-ROP-2 (256/3981 (6.4%) infants, 500 eyes). Initial treatment was 96%-laser, 4%-anti-VEGF in G-ROP-1; but 60%-laser, 40%-anti-VEGF in G-ROP-2. Zone I treatment increased slightly (from 15% to 23%) between studies, as did eyes receiving >1 treatment (from 11% to 16%). In G-ROP-2, eyes receiving anti-VEGF (n=202) were treated earlier than laser (n=298) (mean PMA 35.8 versus 37.5) and were more often in zone I (42% versus 10%). 73% of Zn-I cases and 30% of Zn-II cases were treated initially with anti-VEGF injection. Re-treatment by 50 weeks PMA was more common following anti-VEGF than following laser (29% vs. 7%).

Discussion: The significantly increased use of intravitreal anti-VEGF agents highlights the need for further study of appropriate dosage, systemic effects, and long-term visual outcomes.

Conclusion: Anti-VEGF injections now account for 40% of first-line treatments for ROP. For posterior disease, ophthalmologists are predominantly choosing anti-VEGF agents over laser.

References: 1. Binenbaum G, Tomlinson L, on behalf of the G-ROP Study Group: Postnatal Growth and Retinopathy of Prematurity Study: Rationale, Design, and Subject Characteristics. Ophthalm Epidem 24(1): 36-47, Feb 2017.

Poster #192
Saturday, 9:55 am – 10:55 am

Interleukin-8 as an Emerging Therapeutic Target for Angiogenic Retinopathies

Dolly Ann Padovani-Claudio, MD, PhD; Nolan J. Beatty; Samuel A. Palmer; John S. Penn. PhD

Vanderbilt University School of Medicine
Nashville, TN

Introduction: Various vitreous soluble factors other than VEGF accumulate in angiogenic retinopathies like retinopathy of prematurity. However, only VEGF signaling is currently targeted clinically. Interluekin-8 (IL-8)'s vitreous levels correlate with disease severity in angiogenic retinopathies. IL-8 is a pro-angiogenic chemokine linked to diseases in other organ systems. We hypothesize that manipulating IL-8 signaling can alter retinal vascularization.

Methods: First, we injected IL-8 or vehicle intravitreally in wild-type P4 mice and collected their retinas at P8 to evaluate IL-8's effect on retinal vascularization. Next, we subjected mixed-genotype littermate pups from breeding pairs of heterozygous CXCR2 (IL-8-receptor) mutant mice to oxygen induced retinopathy (OIR) to analyze the effects of interfering with IL-8 signaling on pre-retinal neovascularization. OIR involved exposing mice to 75%-oxygen from P7-P12, returning them to room-air, and collecting eyes at P18. For both experiments, we dissected fixed retinas, stained with isolectin-B4, and flat mounted them. A masked observer traced vascular, avascular and neovascular areas.

Results: Intravitreal IL-8 injection at P4 increased radial retinal vascular growth-rate in wild-type mice when compared to vehicle. After OIR, Cxcr2-/- (knockout) mice had significantly less pre-retinal neovascularization than wild-type littermate controls, despite having no significant difference in relative avascular area.

Discussion: The findings that exogenous IL-8 accelerats retinal vascularization in normoxia, and genetic absence of an IL-8 receptor reduces pre-retinal neovascularization in OIR, support the hypothesis that the IL-8 signaling pathway may be relevant in angiogenic retinopathies.

Conclusion: Several drugs that block IL-8 signaling are in clinical trials for non-ocular diseases and may emerge as alternative therapies for angiogenic retinopathies.

References: 1. Sato T, Kusaka S, Shimojo H, Fujikado T. Simultaneous analyses of vitreous levels of 27 cytokines in eyes with retinopathy of prematurity. Ophthalmology. Nov 2009;116(11):2165-2169.
2. Li A, Dubey S, Varney ML, Dave BJ, Singh RK. IL-8 directly enhanced endothelial cell survival, proliferation, and matrix metalloproteinases production and regulated angiogenesis. Journal of immunology. Mar 15 2003;170(6):3369-3376.
3. Powers MR, Davies MH, Eubanks JP. Increased expression of chemokine KC, an interleukin-8 homologue, in a model of oxygen-induced retinopathy. Current eye research. Apr 2005;30(4):299-307.

Poster #193
Saturday, 9:55 am – 10:55 am

Two-Year Ocular and Neurodevelopmental Outcomes Among Infants Treated for Retinopathy of Prematurity Using a Commercial Claims Database

Michael Zhang, BS; Michael P. Blair, MD; Sarah Hilkert Rodriguez, MD, MPH

University of Chicago
Chicago

Introduction: Limited data exists regarding ocular and systemic effects of antiVEGF agents for the treatment of ROP.

Methods: This study uses Marketscan, a national insurance claims database, to evaluate neurodevelopmental and ocular outcomes among infants treated from 2011-2014 with at least 2 years follow-up.

Results: Of 18,384 infants with ROP and 2 years follow-up, 224 received laser and 59 received injections. Overall, 4 patients in the laser group and no patient in the IVB group expired. One patient developed endophthalmitis after injection. There was a trend towards less retinal detachment with injections than laser (5% and 11%, $p = 0.190$). Infants who received injections were 5 times greater odds of having a second procedure (36% and 9%, $p < 0.001$). Rates of vitreous hemorrhage, corneal opacities, cataracts, glaucoma, and strabismus were not significantly different. Rates of any developmental delay were 91% with laser and 93% with injections. Comparing injection to laser, other delays were motor (19% and 22%, $p= 0.541$), cognitive (37% and 34%, $p=0.676$) and language (63% and 49%, $p=0.063$). Rates of CP were 37% with injections and 17% with laser, $p=0.001$, although infants receiving injections were more likely to have severe intraventricular hemorrhage (29% v. 17%, $p = 0.05$). The difference in CP by treatment group was not statistically significant after propensity score matching (OR=1.96, $p=0.06$).

Discussion: Ocular outcomes appear similar by treatment group. Although developmental outcomes seem to favor laser treatment, severe intraventricular hemorrhage likely represents a confounding factor.

Conclusion: There appears to be a propensity to treat sicker infants with injections.

References: 1. Morin J, Luu TM, Superstein R, et al. Neurodevelopmental outcomes following bevacizumab injections for retinopathy of prematurity. Pediatrics 2016;137(4):e20153218.
2. Kennedy KA, Mintz_Hittner HA, Medical and developmental outcomes of bevacizumab versus laser for retinopathy of prematurity. J AAPOS 2017; 22(1): 61-65.
3. Morrison D, Shaffer J, Ying GS, Binenbaum G. Ocular complications following treatment in the postnatal growth and retinopathy of prematurity (G-ROP) study. J AAPOS 2018; 22:128-133

Poster #194
Saturday, 9:55 am – 10:55 am

A Comparison of Respiratory Outcomes after Treatment for Retinopathy of Prematurity (ROP) with Pan-Retinal Photocoagulation (PRP) or Bevacizumab

Gerard Barry, MD; Kate Tauber, MD; Farzana Afroze, MD; Elizabeth Finuncane, MD; Scott H. Greenberg, MD; Helena Oechsner, MD; Gil Binenbaum, MD, MSCE; Paul Feustel, PhD

Albany Medical College
Albany, NY

Introduction: There are limited data detailing respiratory outcomes following treatment for ROP. We aimed to compare respiratory outcomes after treatment with PRP under general anesthesia to bevacizumab using bedside sedation. 1,2

Methods: Data on 139 consecutive patients treated for ROP from 2010 to 2018 at one institution were examined. The primary outcome measure was complete return to respiratory baseline 48 hours after treatment. Multivariable regression analysis was performed.

Results: 119 patients initially treated with PRP were less likely to return to their respiratory baseline by 48 hours compared to 19 patients initially treated with bevacizumab, odds ratio 0.18 (CI 0.05-0.67), when controlling for birth weight, gender and pre-procedure respiratory support or intubation. For patients treated with laser, a return to respiratory baseline occurred in 47 (39%), 62 (52%), and 93 (78%) at 24 hours, 48 hours and 7 days respectively, compared to 14 (73%), 15 (79%) and 19 (100%) at the same intervals for the patients treated with bevacizumab. Univariate analysis of patients treated with laser showed a significant correlation between not returning to respiratory baseline at 48 hours and lower birth weight, lower gestational age, lower post-menstral age at treatment, and pre-procedure respiratory support, but no correlation with gender or multiple procedures.

Discussion: Infants in both groups were at risk of not returning to their pre-procedure respiratory baseline 48 hours after treatment.

Conclusion: Infants treated with bevacizumab using bedside sedation are more likely to return to pre-procedure respiratory baseline by 48 hours than infants treated with PRP under general anesthesia.

References: 1. Jiang J-B, Strauss R, Luo X-Q, et al. Anaesthesia modalities during laser photocoagulation for retinopathy of prematurity: a retrospective, longitudinal study. BMJ Open. 2017;7(1). doi:10.1136/bmjopen-2016-013344
2. Ülgey A, Günes I, Bayram A, et al. Decreasing the need for mechanical ventilation after surgery forretinopathy of prematurity: sedoanalgesia vs. general anesthesia. Turkish Journal Of Medical Sciences. 2015;45:1292-1299. doi:10.3906/sag-1401-24

Poster #195
Saturday, 9:55 am – 10:55 am

Does the Newer Anti-VEGF Therapy Impact Neurodevelopmental Outcomes More than Conventional Laser Therapy in Infants Treated for Retinopathy of Prematurity?

L. Daphna Y. Barbeau, MD; Swati Agarwal

University of Florida
Gainesville, Florida

Introduction: To compare the neurodevelopmental outcomes in infants who have and who have not received bevacizumab injections (anti-VEGF) and or laser therapy for Retinopathy of Prematurity (ROP) treatment. We hypothesize that the neurodevelopmental outcomes may be similar by group, or that differences in outcomes might better be explained by other complications of prematurity, rather than the ROP therapy treatments.

Methods: Data is being collected both retrospective and prospectively via chart review of 100 preterm neonates. Information evaluated includes gestational age, birth weight, complications of prematurity that are known to increase risk for ROP and Bayley III scores through 2 years as available.

Results: Preliminary data includes untreated control group (n=16) and therapy group (n=22). Of the therapy group, 15 infants had bevacizumab monotherapy and 7 had laser plus bevacizumab. The results show that while those infants treated with therapy are younger (25.40 ± 4.36 therapy group vs 27.49 ± 3.15 control group, P=0.010) and smaller (0.71 ± 0.28, therapy group vs 0.87 ± 0.32 control group, P=0.049) as compared to the untreated control group, the groups were not significantly different in incidence of chronic lung disease, intraventricular hemorrhage or the need for postnatal steroids. There were no significant differences in Bayley III subcategories over time, between the two groups. Trends in data indicate that there may be more significant (P=.007) delays in language in infants who receive laser and bevacizumab therapy, as compared to bevacizumab therapy alone. In addition, there was a significant (P=.002) trend that infants who received both laser and bevacizumab therapy has lower language and motor categories on the Bayley III as compared to those infants who did not require treatment.

Discussion: Infants who are more likely to require ROP treatment tend to have more independent risk factors for neurodevelopmental delays. In this pilot study, which is the first to compare ROP therapy to controls who do not receive therapy, there does not appear to be differences in short term neurodevelopmental outcomes associated with bevacizumab monotherapy treatment. Anti-VEGF therapy seems to be safe in the short-term, however, a longitudinal study is necessary to ensure the long term neurodevelopmental outcomes.

Conclusion: In this pilot study, which is the first to compare ROP therapy to controls who do not receive therapy, there does not appear to be differences in short term neurodevelopmental outcomes associated with bevacizumab monotherapy treatment.

References: 1. Quinn, G, Darlow, B. (2016) Concerns for Development After Bevacizumab Treatment of ROP. Pediatrics
2. Mintz-Hittner, H et al (2013)Efficacy of Intravitreal Bevacizumab for Stage 3+ Retinopathy of Prematurity. New England Journal of Medicine
3. Lien, R (2016) Neurodevelopmental Outcomes in Infants with Retinopathy of Prematurity and Bevacizumab Treatment. PLoS one.

Poster #196
Saturday, 9:55 am – 10:55 am

Neurodevelopmental and Visual Outcomes in Infants with Retinopathy of Prematurity Treated with Bevacizumab versus Laser

Nasrin Therani; Maram Isaac, MD; Kamini Raghuram; Kamiar Mireskandari; Prakesh Shah

The Hospital for Sick Children
Toronto, ON, Canada

Introduction: We aimed to compare neurodevelopmental and visual outcomes in preterm infants treated with intravitreal bevacizumab (IVB) to laser ablation at 18-24 months corrected age.

Methods: A retrospective chart review was performed between April 2009-June 2015. Data was collected from charts/local database information. The primary outcome was moderate-significant neurodevelopmental impairment (NDI), defined as a composite of neuromotor, neurocognitive and/or neurosensory impairment. Secondary outcomes were significant NDI (sNDI), cerebral palsy, hearing loss and the median composite scores of the cognitive, language and motor domains of the Bayley Scales of Infant Development, 3rd edition. Visual outcomes included structural, visual and refractive outcomes. Univariate and multivariable logistic regression were performed, adjusting for significant confounders.

Results: Sixty-four infants were included; 34 (60 eyes) received IVB and 30 (51 eyes) laser. There were no baseline neonatal differences between the two groups. No significant differences were identified in NDI (OR=1.63, [95% CI 0.54, 4.87], adjusted OR=1.77, [95% CI 0.46, 6.73]) or sNDI (OR=2.19, [95% CI 0.80, 5.98], adjusted OR=2.31, [95% CI 0.75, 7.14]) for infants treated with IVB compared to laser. Median visual acuity was 0.40±0.36 and 0.30±0.44 for IVB and laser groups respectively (p=0.85). Median spherical equivalent was -1.0 (range -16.5-1.0) and -2.5 (range -19.5-1.5) for the IVB and laser groups, respectively (p=0.02). All infants had favorable structural outcomes.

Discussion: IVB therapy was not associated with adverse neurodevelopmental or visual outcomes at 18-24 months in this cohort.

Conclusion: Larger randomized trials with longer-term follow-up are required to assess efficacy, ocular and systemic safety of IVB.

References:

Poster #197
Saturday, 9:55 am – 10:55 am

Early Recurrence of Retinopathy of Prematurity after Initial Intravitreal Ranibizumab Monotherapy - Experience from a Tertiary Referral Center in Abu Dhabi, UAE

Tin T. Chan, DR; Abeer A. Al Ali, DR; Ahmed A. ElBarky, DR; Fiona F. Dean, DR; Fatima F. Habroosh, DR; Manal M. Alzaabi, DR; Rawdha R. Al Nuaimi, DR

Sheik Khalifa Medical City
Abu Dhabi, UAE

Introduction: To evaluate recurrence rate of retinopathy of prematurity (ROP) after initial intravitreal ranibizumab injection (IVR) monotherapy for infants with Type 1 retinopathy of prematurity (zone I and posterior zone II) and Threshold Disease

Methods: A retrospective study of electronic medical files was performed on 38 infants (75 eyes) seen between May 2013 to July 2017. They received initial intravitreal ranibizumab monotherapy (IVR) only for Type1 or Threshold Disease retinopathy of prematurity (ROP). All babies received 0.25mg/0.025ml (IVR) 1.75 to 2.00 mm posterior to the limbus.

Results: Success rate, measured by ROP resolution post-initial IVR injection monotherapy was 61.3 %(46/75 eyes) in 23 infants while 38.7 % (29/75 eyes) of 15 infants had an early recurrence. The early (first) recurrence occurred 5 to 8 weeks post initial monotherapy of IVR injection (mean 7 weeks). The second recurrence in 4/15 eyes was 1 to 8 weeks post- treatment (Mean 4.2 weeks) and 1 eye had third recurrence 8 weeks post- treatment. Mean follow up was 12 months post IVR.

Discussion: Early recurrence after initial injection occurs in 38.7 % of infants and the mean onset of recurrence is 7 weeks. None of the infants developed recurrence after 52 post menstrual age (PMA). Recurrence with intravitreal bevacizumab injection is reported to occur at 16 weeks or later but in our study using intravitreal ranibizumab monotherapy, recurrence of ROP occurred earlier.

Conclusion: We highly recommend a stringent follow up protocol to look for recurrences post IVR injection, especially in the initial three-month period.

References: 1- Krohne TU, Liu Z, Holz FG, Meyer CH. Intraocular pharmacokinetics of ranibizumab following a single intravitreal injection in humans. Am J Ophthalmol 2012;154:682–686.
2- Bakri SJ, Snyder MR, Reid JM, et al. Pharmacokinetics of intravitreal ranibizumab (Lucentis). Ophthalmology 2007;114:2179–2182
3- Jang SY, Choi KS, Lee SJ. Delayed-onset retinal detachment after an intravitreal injection of ranibizumab for zone 1 plus retinopathy of prematurity. Delayed-onset retinal detachment after an intravitreal injection of ranibizumab for zone 1 plus retinopathy of prematurity. J AAPOS 2010;14:457–459.
4- Lin CJ, Chen SN, Hwang JF. Intravitreal ranibizumab as salvage therapy in an extremely low-birth-weight infant with rush type retinopathy of prematurity. Oman J Ophthalmol 2012;5:184–186.
5- Kuo, H., Sun, I., Chung, M., & Chen, Y. (2015). Refractive Error in Patients with Retinopathy of Prematurity after Laser Photocoagulation or Bevacizumab Monotherapy. Ophthalmologica, 234(4), 211-217. doi:10.1159/000439182
1- Avery RL, Castellarin AA, Steinle NC, et al. Systemic pharmacokinetics following intravitreal injections of ranibizumab,bevacizumab or aflibercept in patients with neovascular AMD.Br J Ophthalmol 2014;98:1636–1641.
2- Zehetner C, Kirchmair R, Huber S, et al. Plasma levels of vascular endothelial growth factor before and after intravitreal injection of bevacizumab, ranibizumab and pegaptanib in patients with age-related macular degeneration, and in patients with diabetic macular oedema. Br J Ophthalmol 2013;97:454–459.
3- Lee SJ, Kim SY, Yoo BC, et al. Plasma level of vascular endothelial growth factor in retinopathy of prematurity after intravitreal injection of bevacizumab. Invest Ophthalmol Vis Sci 2011;52; ARVO abstract 3165.
4- Mintz-Hittner HA, Kennedy KA, Chuang AZ; BEAT-ROP Cooperative Group. Efficacy of intravitreal bevacizumab for stage 3+ retinopathy of prematurity. N Engl J Med 2011;364:603–615.
5- Feng, J., Qian, J., Jiang, Y., Zhao, M., Liang, J., Yin, H., . . . Li, X. (2017). Efficacy of Primary Intravitreal Ranibizumab for Retinopathy of Prematurity in China. Ophthalmology, 124(3), 408-409. doi:10.1016/j.ophtha.2016.10.032
6- Chan, J. J., Lam, C. P., Kwok, M. K., Wong, R. L., Lee, G. K., Lau, W. W., & Yam, J. C. (2016). Risk of recurrence of retinopathy of prematurity after initial intravitreal ranibizumab therapy. Scientific Reports, 6(1). doi:10.1038/srep27082
7- Huang, Q., & Zhao, P. (2017). Anti-vascular endothelial growth factor treatment for retinopathy of prematurity. Annals of Eye Science, 2, 47-47. doi:10.21037/aes.2017.02.06
8- Chuluunbat, T., Chan, R. P., Wang, N., Lien, R., Chen, Y., Chao, A., Wu, W. (2016). Nonresponse and Recurrence of Retinopathy of Prematurity After Intravitreal Ranibizumab Treatment. Ophthalmic Surgery, Lasers and Imaging Retina, 47(12), 1095-1105. doi:10.3928/23258160-20161130-03
9- Papadopoulos, Nicholas, et al. 'Binding and Neutralization of Vascular Endothelial Growth Factor (VEGF) and Related Ligands by VEGF Trap, Ranibizumab and Bevacizumab.' Angiogenesis, vol. 15, no. 2, Mar. 2012, pp. 171–185., doi:10.1007/s10456-011-9249-6.
10- Connor, Alan J., et al. 'Ultra-Low Dose of Intravitreal Bevacizumab in the Treatment of Retinopathy of Prematurity.' Journal of Pediatric Ophthalmology & Strabismus, 2015, doi:10.3928/01913913-20150421-11.

Poster #198
Saturday, 9:55 am – 10:55 am

Bilateral Endophthalmitis from Bevacizumab Intravitreal Injections in Type I Retinopathy of Prematurity

Jason M. So, MD; Alan B. Richards, MD

LSUHSC Shreveport Department of Ophthalmology
Shreveport, Louisiana

Introduction: Anti-VEGF is currently a treatment modality of retinopathy of prematurity. Possible complication of intravitreal injection for ROP includes endophthalmitis. The prevalence of endophthalmitis post-intravitreal injection is currently unknown. Currently in the literature, there is one case report of an endophthalmitis following injection of bevacizumab. There were no other published reports of endophthalmitis following intravitreal injection of anti-VEGF for ROP. We report a result of a survey of US pediatric ophthalmologists for incidence of endophthalmitis post-injection in neonates with ROP. We also report a case of bilateral endophthalmitis following bilateral anti-VEGF injections.

Methods: A 24-week gestation neonate was noted to have zone 1, stage 2 disease with plus at week 32 and was treated with bilateral intravitreal injections of bevacizumab. Subsequent vitrectomy with culture yielded Streptococcus mitis/oralis. A survey was conducted in 2017 using US pediatric ophthalmology online listserv requesting the number of endophthalmitis seen after intravitreal injection of anti-VEGF for retinopathy of prematurity.

Results: The survey was completed by 33 US pediatric ophthalmologists. There were six complications resulting from the intravitreal anti-VEGF agents for ROP, including one case of endophthalmitis. The case of endophthalmitis remains unpublished.

Discussion: The true incidence and severity of ocular adverse effects from intravitreal injections of anti-VEGF agents in ROP is not known. Contamination during compounding bevacizumab should be considered. Oral pathogen is a major cause of post-injection endophthalmitis and was the microbe isolated from our case.

Conclusion: Gowns, gloves and masks are used at one large medical center. Separate vials, preferable separate lots, should be used for each eye. Care should be taken with concurrent nasolacrimal obstruction, sepsis, or CPAP (switching to nasal cannula during the injection is recommended). Further study of the true incidence of endophthalmitis after anti-VEGF injection in preterm infants is recommended.

References: 1. Falavarjani, K Ghasemi, Nguyen, QD. Adverse events and complications associated with intravitreal injection of anti-VEGF Agents: A review of literature. Eye (Lond) 2013;27: 787-794.
2. Englander M, Chen TC, Paschalis EI, et al. Intravitreal injections at the Massachusetts Eye and Ear Infirmary: analysis of treatment indications and post-injection endophthalmitis rates. Br J Ophthalmol 2013;97(4):460-465.
3. Dossarps D, Bron AM, Koehrer P, et al. Endophthalmitis after intravitreal injections: incidence, presentations, management, and visual outcome. Am J Ophthalmol 2015;160(1):17-25.

Poster #199
Saturday, 9:55 am – 10:55 am

Band Keratopathy in Treated Retinopathy of Prematurity

Jon C. Hildebrand, MD; Natalie Kerr, MD

University of Tennessee Health Science Center
Memphis, TN

Introduction: Juvenile Idiopathic Arthritis (JIA) is a well-known cause of band keratopathy (BK) in the pediatric population. We have recognized an association of BK with retinopathy of prematurity (ROP) in our patients. We conducted a retrospective review of pediatric patients in our practice with BK to determine which etiologies are most commonly associated with BK in the pediatric population.

Methods: All patients within a single, academic pediatric ophthalmology practice diagnosed with BK between 2013 and 2016 were identified. Additionally, all patients requiring superficial keratectomy with EDTA for BK from 2013 to 2018 were identified. Patients born before 1988 were excluded. We then compared all causes of BK within this population.

Results: Twenty-four eyes (in fifteen children) were identified as having a diagnosis of BK. The most common associations with BK in this group were JIA (29%), ROP (17%), and Idiopathic uveitis (17%). Additionally, eleven eyes were identified as requiring intervention via superficial keratectomy. 46% of eyes requiring keratectomy had a diagnosis of ROP (all of which had previous retinal laser treatment).

Discussion: Studies in patients treated for ROP usually do not list BK as a complication. Our study suggests that, not only is treated ROP associated with BK, but it may also be one of the primary associations in the pediatric population. Furthermore, based on the number of superficial keratectomies performed at our institution, BK in ROP may be more visually significant or functionally debilitating than BK in JIA.

Conclusion: Band keratopathy may be an under-recognized long-term complication of patients treated for retinopathy of prematurity.

References: 1. Salgado C, Celika Y, VanderVeena D. Anterior Segment Complications After Diode Laser Photocoagulation for Prethreshold Retinopathy of Prematurity. American Journal of Ophthalmology. Volume 150, Issue 1, July 2010, Pages 6-9.e2.
2. Al-Hity A, Ramesh K, Lockington D. EDTA chelation for symptomatic band keratopathy: results and recurrence. Eye. 2018. Volume32, pages26-31
3. Jhanji V, Rapuano C, Vajpayee R. . Corneal calcific band keratopathy. Current Opinion in Ophthalmology. Issue: Volume 22(4), July 2011, p 283-289.

Poster #200
Saturday, 9:55 am – 10:55 am

Binocularity Outcomes Following Treatment for Retinopathy of Prematurity

Sonia Manuchian; Maram Isaac; Kamiar Mireskandari; Nasrin Tehrani; Michael Vincer; Jill Hatchette; Johane Robitaille

SickKids Hospital and IWK Health Centre
Toronto, ON and Halifax, NS (respectively), Canada

Introduction: Retinopathy of prematurity (ROP) can be successfully treated with laser or intravitreal bevacizumab (IVB). However, functional outcomes of each treatment require further investigation. We aimed to compare binocularity in children treated with either modality.

Methods: This prospective, cross-sectional study tested the relationship between binocular responses in children aged three to eight and ROP treatment. Presence of binocularity consisted of either a fusion response on Bagolini testing or stereopsis measured by the Frisby stereotest. Insults to development of binocularity included amblyopia, anisometropia and strabismus quantified by logMAR charts, cycloplegic refraction and cover testing, respectively. Presence of neurodevelopmental impairment, binocularity and binocularity-interrupting events were analysed using Chi-Square tests.

Results: 44 children were recruited: 23 treated with IVB and 21 with laser. No statistically significant difference in rates of binocularity was detected (67% laser vs 82% IVB; p=0.27). Laser-treated participants experienced a greater number of cumulative insults to binocularity than those in the IVB group (81% vs 52%, respectively, p=0.04).

Discussion: This study reinforces the need for close monitoring following ROP treatment during the visual development years to optimize binocularity. Although we did not detect a significant difference in the rates of binocularity, both groups experienced high rates of amblyopia, strabismus and anisometropia. IVB may be superior to laser in reducing the number of binocularity-disrupting events in these children.

Conclusion: ROP patients treated with laser or IVB require long-term follow-up to address binocularity-disrupting factors. Further investigation with a larger sample size of visually mature subjects is needed to confirm these findings.

References:

Workshops

Workshop #1
Thursday, 2:15 pm – 3:15 pm

How I Raised My Sons to be Rock Stars: A Family's Journey with Leber Congenital Amaurosis

Margaret Wakeley; Arlene V. Drack, MD
(Casey Harris; Sam Harris)

University of Iowa
Iowa City, IA

Purpose/Relevance: How does living with a genetic eye disorder impact our patients in everyday life? Does a molecular genetic diagnosis change their understanding of the condition? Rather than hearing only from doctors and researchers, this talk will present a genetic diagnosis from the standpoint of the patient and family.

Target Audience: Pediatric ophthalmologists, residents, fellows, orthoptists

Current Practice: We are accustomed to answering questions, but there is rarely an opportunity for care providers to ask questions and get feedback from patients and families on the best ways to discuss serious diagnoses and genetic testing.

Best Practice: Patients, family members and other lay people can offer important perspectives on our work and our organization. Inviting members of the community to participate in our yearly meeting bridges the gap between providers and our patients.

Expected Outcomes: The audience will better understand the challenges and needs of patients and families with genetic eye diseases and the value of genetic testing.

Format: Margaret Wakeley will describe her experience with discovering her child had vision loss and later, end stage renal disease, how she supported and raised him and his normally sighted brother, and how her sons eventually became touring rock stars in the popular band, X Ambassadors, despite Casey's blindness. In adulthood, Casey and Margaret submitted blood for genetic testing and received a molecular genetic diagnosis for Casey's lifelong condition; she will discuss what this means to them. A music video by X Ambassadors will be shown, which highlights how their experiences with disability have influenced their music. The audience will have time to ask questions.

Summary: Genetic testing is not only a scientific and medical pursuit, it is a human pursuit as well. By inviting patients and parents to share their experiences with molecular genetic diagnosis, pediatric ophthalmologists will better understand the importance of genetic testing, as well as how to support families dealing with genetic eye disease.

References: www.drackresearch.org/interviews
This presentation is supported by the AAPOS Ophthalmic Genetic Eye Disease Committee

Workshop #2
Thursday, 3:30 pm – 4:30 pm

Duty to Patients: Beginning, Ending, and Obligations

Robert E. Wiggins, Jr., MD, MHA; Anne M. Menke, RN, PhD

OMIC
San Francisco, CA

Purpose/Relevance: Determining whether a doctor-patient relationship exists is an important issue in medical professional liability cases as this relationship creates a duty to care for the patient. If there is no relationship, there can be no malpractice. In most situations, establishing this relationship is clear cut though in some cases the existence of a relationship is ambiguous and can even result in a claim being filed when the physician has not examined the patient. A lack of understanding of this relationship has resulted in professional liability claims and, in some cases, patient harm.

Target Audience: Pediatric ophthalmology and strabismus physicians

Current Practice: The question of whether a doctor-patient relationship exists arises in many situations in medical practice such as phone consultations in hospital ER coverage as well as in situations where a patient referred to the practice may not have insurance coverage accepted by the practice. Once a doctor-patient relationship has been established, problems may also arise if the relationship is not properly terminated for noncompliance with recommendations or follow up or failure to pay for services. OMIC's claims data shows that these issues have each led to professional liability claims.

Best Practice: Physicians understand that providing phone advice to/for a specific patient, speaking to the ED physician, accepting a referral, and scheduling an appointment may create a doctor-patient relationship and duty of care. They arrange consultations, ensure follow-up care, and properly terminate the relationship under appropriate circumstances.

Expected Outcomes: Physicians will better ensure that they meet their duty to patients by taking the following actions:
1. Clarify their follow-up duties when serving on-call to a hospital ED.
2. Inform staff when patients are expected from the ED.
3. Review the process in their practice for scheduling appointments, and arranging consultations and tests.
4. Advise patients by sending a termination letter when they wish to end the relationship.

Format: Lecture and case presentation from OMIC files. Audience Q and A.

Summary: Patients have been harmed and physicians have been sued when the physician did not realize a relationship had been established or termination of the relationship was not handled appropriately. A plaintiff cannot prove negligence if there is no doctor-patient relationship. Education about the duty of care and management of the physician-patient relationship will be provided through a series of case presentations and discussion.

References: 1. Blake, V. When is a patient-physician relationship established? American Medical Association Journal of Ethics. May 2012, Volume 14 (5): 403-6.
2. Weber, P. When is a physician-patient relationship established? www.OMIC.com. Accessed September 23, 2018.
3. Geline, R. Defining and terminating the physician-patient relationship. http://www2.aaos.org/bulletin/oct06/ORM2.asp. Accessed September 23, 2018
4. Menke, A. Terminating the physician-patient relationship. www.OMIC.com. Accessed September 23, 2018.

Workshop #3
Friday, 7:00 am – 8:15 am

Stump the Chump - Tough Cases to Highlight Challenges in Childhood Glaucoma Diagnosis and Management

Sharon F. Freedman, MD; Alex V. Levin, MD; Allen D. Beck, MD; Ta Chen (Peter) Chang, MD; Amanda L. Ely, MD; Allison R. Loh, MD

Duke University Medical Center
Durham, NC

Purpose/Relevance: This workshop is designed to use a case-based approach to highlight challenges in the management of childhood glaucoma, from diagnostic and treatment dilemmas to complex surgical interventions and their problems.

Target Audience: Pediatric ophthalmologists, comprehensive and glaucoma-trained ophthalmologists, and ophthalmologists-in-training whose practice includes (or will include) children with known or suspected glaucoma.

Current Practice: The prompt diagnosis and optimal treatment of children with known or suspected glaucoma often presents challenges. The relative rarity of these conditions can make diagnosis and decision-making difficult for those encountering these cases as unexpected 'surprises' in a busy practice. The heterogeneity of childhood glaucoma diagnostic groups and the variable severity and response-to-therapy make management particularly challenging. We will have tough cases presented by relatively early-career pediatric 'glaucomatologists' to our 'senior' panel, prompting discussion among the group to identify and highlight the various approaches and common themes that arise when managing these cases.

Best Practice: This workshop will facilitate the sharing of 'wisdom', strategies, and 'pearls and pitfalls' among those relatively junior, and those with decades of experience, as we team together to best treat childhood glaucoma. Cases will highlight themes including diagnostic challenges, therapeutic dilemmas, and what to do when the unexpected or dreaded happens (managing complications including those that are surgery-related, as well as those that are disease-related).

Expected Outcomes: This workshop is intended to increase the attendee's level of familiarity with, and confidence in examining, diagnosing, and planning treatment for childhood glaucomas of varying severity and complexity.

Format: Strictly case-based format where the junior 'presenters' present and moderate the discussion of selected cases of childhood glaucoma, with discussion by the expert panel, presenters, and audience.

Summary: Presentation of selected cases of childhood glaucoma (or suspected glaucoma) and their management, with focus on exchanging ideas and sharing pearls/pitfalls/strategies for managing these challenging patients.

Workshop #4
Friday, 7:00 am – 8:15 am

21st Century Teaching: Best Practices in Medical Education

Matthew D. Gearinger, MD; Tammy Yanovitch; Michelle Cabrera; Gena Heidary

Flaum Eye Institute
Rochester, NY

Purpose/Relevance: There are 470 new ophthalmology residents and 40 pediatric ophthalmology fellows each year in the US. Most medical educators have no formal training in education. There is a growing body of research in medical education which can improve our teaching activities.

Target Audience: Pediatric ophthalmologists who teach residents, fellows, or medical students.

Current Practice: Most academic clinicians have no formal training in education, and teach in the same way that they were taught. Powerpoint slides in a dark room and 'see one, do one, teach one' are the typical methods for didactic and clinical instruction. Medical education has not been a priority topic in most ophthalmic sub-specialty meetings.

Best Practice: Increasing numbers of faculty will become proficient in educational theory and best practices. This will lead to a more efficient learning environment for our trainees and improved patient care.

Expected Outcomes: By the end of the workshop, participants will be able to:
Apply adult-learning principles to trainee education
Discuss best practice for clinical and didactic education
Develop a simulation program for surgical education
Design a remediation program for the struggling learner

Format: This workshop will utilize a panel format to discuss evidence-based methods for training residents and fellows in pediatric ophthalmology and strabismus. Audience polling via polleverywhere will assess current practices. There will be ample time for interaction and discussion of personal experience.

Summary: We will present a panel discussion in best practices in medical education, focusing on didactic, clinical, and surgical instruction. Basic principles of adult education, use of technology in medical education, and remediation of the struggling trainee will also be presented.

References: 1. Adebayo T, Abendroth M, Elera GG, Kunselman A, Sinz E, Ely A, Elkamshoushy A, Soni A. Developing and validating a simple and cost-effective strabismus surgery simulator. J AAPOS. 2018 Apr;22(2):85-88.e2.
2. Warburton KM, Goren E, Dine CJ. Comprehensive Assessment of Struggling Learners Referred to a Graduate Medical Education Remediation Program. J Grad Med Educ. 2017 Dec;9(6):763-767.
3. Paley GL, Shute TS, Davis GK, Culican SM. Assessing Progression of Resident Proficiency during Ophthalmology Residency Training: Utility of Serial Clinical Skill Evaluations. J Med Educ Train. 2017;1(4).

Workshop #5
Friday, 7:00 am – 8:15 am

IPOSC Workshop: Nightmares in Strabismus

Faruk H. Orge; Frank Martin; Sonal Farzavandi; Tamara Wygnanski Jaffe; Adolfo Guemes; Eedy Mezer; Moustafa Salah

UH CMC and Rainbow B&C Hospital
Cleveland, Ohio, USA

Purpose/Relevance: Although strabismus surgeries are commonly performed, , surgeons often encounter complicated cases or unpredicted findings. We seek to share experiences and different approaches to such cases via discussion by expert strabismus surgeons.

Target Audience: Pediatric ophthalmologists and strabismus surgeons

Current Practice: Ophthalmologists may not be familiar with strategy, surgical pearls, tips and tricks to handle nightmares in strabismus cases. Sharing various experiences can teach us to expect, be aware, avoid and plan for complications, if /when they should occur in order to avoid further surgeries and poor outcome.

Best Practice: Ophthalmologists should be familiar with possible complications, plan to avoid or appropriately deal with these situations. Strabismus surgeons should also be familiar with particularly complex cases and be able to plan surgical approaches to be able to adequately help their patients.

Expected Outcomes: Through many case presentations and expert panel discussion, the attendee will be able to familiarize themselves with complex strabismus cases to enhance their surgical skills and management.

Format: Members of the panel will present surgical cases with management dilemmas followed by a question/answer period from the panel and the audience.

Summary: The workshop will focus on nightmares in strabismus surgery either due to underlying conditions (i.e. thyroid orbitopathy, neuropathies, complex strabismus), previous surgeries or significant complications during strabismus surgeries. Several topics will be led by one of the authors with a case presentation followed by a panel discussion and author's approach and outcome presentations. There will be a dedicated time for attendee questions and contributions.

Workshop #6
Friday, 7:00 am – 8:15 am

Reading Difficulties and the Pediatric Ophthalmologist

Melinda Rainey, MD; Deborah M. Alcorn, MD; Linn M. Mangano, MD; Laura J. Heinmiller, MD; Sheryl M. Handler, MD; Walter F. Fierson, MD

AAPOS Learning Disability Committee, A. Melinda Rainey MD, Chair

Purpose/Relevance: Difficulties in learning to read occur in up to 40% of children. Many of these children will have dyslexia which represents 80% of all learning disabilities. Many people wrongly believe that reading difficulties are due to 'visual problems.' It is important for Pediatric Ophthalmologists to be conversant in the signs and symptoms of dyslexia, its underlying etiology, evidence-based treatments as well as controversial therapies, and to provide parents clarity and guidance to appropriate resources.

Target Audience: Pediatric Ophthalmologists and Orthoptists

Current Practice: Pediatric Ophthalmologists have very little training about dyslexia in residency or even fellowship. However, we are often ask to examine children with reading problems but may lack the knowledge to be able to properly counsel families.

Best Practice: A Pediatric Ophthalmologist will be able to evaluate children with reading difficulties, ensure a normal eye exam, recognize the salient features of suspected dyslexia and provide information on local resources.

Expected Outcomes: The participant will gain understanding of the etiology of dyslexia, controversial and unproven therapies, evidence-based proven therapies and be able to provide families with factual information and how to find appropriate therapeutic resources.

Format: Workshop as a didactic lecture with question and answer forum

Summary: This course will provide a summary of the latest information on how we read, eye functions necessary to read, etiology of dyslexia and evidence-based remedial treatments. It will further examine controversial therapies such as Vision Therapy, Behavioral Optometry practices and Colored Lenses/Filters. We will further provide information on what to tell parents to assist our patients in finding the correct diagnosis, treatment and educational modifications.

References: Handler SM, Fierson WM, Section on Ophthalmology; Council on Children with Disabilities; American Academy of Ophthalmology; American Association for Pediatric Ophthalmology and Strabismus and American Association of Certified Orthoptists. Pediatrics. 2011 Mar, 127(3) e818-56.
Handler SM, Fierson WM, Rainey AM, Cooper K. Dyslexia: what pediatric ophthalmologists and families need to know. JAAPOS. 2016 Aug, 20(4) e52.
Handler SM, Fierson WM. Reading Difficulties and the Pediatric Ophthalmologist. JAAPOS. 2017 Sep, 21(6) 436-442.

Workshop #7
Friday, 8:30 am – 9:45 am

What's New and Important in Pediatric Ophthalmology and Strabismus in 2019

Darron A. Bacal, MD, FAAP; Tina Rutar, MD; Hee-Jung Park, MD, MPH; Marina Eisenberg, MD; Melanie Schmitt, MD; Sudha Nallasamy, MD; Kara Cavuoto, MD; Gena Heidary, MD, PhD; Ilana Friedman MD; Phoebe Lenhart, MD

Professional Education Committee of AAPOS
None

Purpose/Relevance: The authors will investigate the literature for articles of interest to the sub-specialty of Pediatric Ophthalmology and Strabismus for the time period February 2018- January 2019. Ophthalmic journals are stressed but journals from other specialties such as pediatrics, neurology and comprehensive medicine will be included. The authors will summarize the key findings in the major topics including, but not limited to, vision screening, amblyopia, neuro-ophthalmology, retinopathy of prematurity, strabismus, cataract, glaucoma, genetics, retina, orbit, uveitis and practice management. The presentations in these topic areas will summarize and emphasize second-order analyses of the material.

Target Audience: Pediatric and Comprehensive Ophthalmologists who examine, diagnose and treat children and adults with strabismus, Orthoptists.

Current Practice: Pediatric Ophthalmology is a rapidly evolving sub-specialty. It is difficult to remain current with all of the literature in this field. Our goal is to keep clinicians up-to-date on important published articles.

Best Practice: The authors will summarize, analyze and present the most current and important information from more than 20 medical journals. This will allow the audience to have an overview of the most current and important literature.

Expected Outcomes: The audience will understand the most current published information in this sub-specialty.

Format: Didactic lecture

Summary: More than 20 medical journals will be reviewed for relevant new findings in the sub-specialty of Pediatric Ophthalmology and Strabismus from February 2018-January 2019. The material presented will educate the Ophthalmologists and Orthoptists in new research.

References: Journal of AAPOS, Ophthalmology, Pediatrics

Workshop #8
Friday, 8:30 am – 9:45 am

Pediatric Optometrists Trained in a Medical Home - Inside Look at a Training Program and the Pediatric MD-OD Working Relationship

Sharon F. Freedman, MD; Nathan Cheung, OD; Robert Enzenauer, MD, PhD; Daniel Smith, OD; Scott E. Olitsky, MD; Erin D. Stahl, MD; Timothy E. Hug, OD; Michael E. Gray, MD

Duke University Medical Center
Durham, NC

Purpose/Relevance: This workshop will provide attendees an opportunity to learn firsthand about the current pediatric optometry residency programs housed entirely in a medical institution, including the necessary components for creating new training programs, and the pediatric MD-OD working relationships in these institutions.

Target Audience: Pediatric Ophthalmologists, pediatric optometrists permitted to attend AAPOS, orthoptists, and trainees.

Current Practice: Despite the shortage of pediatric eye care providers nationwide, and many pediatric eyeMDs wish for a more complex practice mix, and more efficiency in providing for their patients. Pediatric optometrists and ophthalmologists work together harmoniously in some places, but there is misunderstanding and friction in other settings. Pediatric optometrists trained in medical institutions differ from those trained in 'Behavioral Optometry'. Vision training in its classic form often poses challenges to children/families and their pediatric ophthalmologists, while high-quality providers of primary pediatric eye care are in short supply.

Best Practice: This workshop provides attendees an in-depth look at the programs currently training pediatric optometrists solely in a medical facility, and offers insights into the rewarding working relationship that Pediatric ODs and MDs can have.

Expected Outcomes: This workshop is intended to increase the attendee's understanding of: 1) what the pediatric optometry residency in a medical setting includes; 2) necessary ingredients to start additional training programs, and 3) mutually satisfying pediatric MD-OD working relationships.

Format: Presentations on relevant topics from the OD Residency Directors (pediatric ODs) and their MD AAPOS 'Partners' at the four programs currently accredited to train ODs solely in a medical setting. Audience questions/comments will be encouraged.

Summary: We will provide an inside look at the inner workings of a Pediatric OD residency training program in a medical setting, including 'how to' create additional programs, and how the graduating pediatric ODs can work in harmony with their pediatric MD colleagues. We will provide practice information and will be open to panel and group discussion.

Workshop #9
Friday, 8:30 am – 9:45 am

AAP Workshop: Cortical/Cerebral Visual Impairment 2019: What You Need to Know to Diagnose and Treat

Sharon S. Lehman, MD; Linda M. Lawrence, MD; Terry L. Schwartz, MD

Nemours/AI duPont Hospital for Children
Wilmington, Delaware

Purpose/Relevance: Cortical/Cerebral Visual Impairment (CVI) is the most common cause of visual loss in children in developed countries. Lack of a standardized method for evaluation, diagnosis and providing recommendations for children with CVI creates challenges for the pediatric ophthalmologist. This workshop will provide practical information to close those existing gaps.

Target Audience: ophthalmologists, orthoptists

Current Practice: Lack of knowledge and attitudes of pediatric ophthalmologists concerning the care of patients with CVI limits the effectiveness of the team in caring for patients

Best Practice: A pediatric ophthalmologist familiar with the latest information about CVI using standardized tools will improve the effectiveness of the pediatric ophthalmologist as a part of the team caring for a child with CVI and ultimately provide the best care for the patient.

Expected Outcomes: Exploration of varied case studies will allow the pediatric ophthalmologist to have practical tools that will allow for easier diagnosis, evaluation and communication of recommendations to the child's team.

Format: Case presentation, didactic lecture, question and answer

Summary: Lack of a standardized method for evaluation, diagnosis and providing recommendations for children with CVI creates challenges for the care team. Education of pediatric ophthalmologists and development of standardized tools which can provide the necessary information are practical ways to approach this problem.

References: Lueck AH, Dutton GN, editors. Vision and the Brain: Understanding Cerebral Visual Impairment in Children. New York, NY: AFB Press; 2015
Roman-Lantzy C. Cortical Visual Impairment: An Approach to Assessment and Intervention. Second Edition. New York, NY: AFB Press; 2018

Workshop #10
Friday, 8:30 am – 9:45 am

Pediatric Anterior Segment Problems You Don't Want to Miss

Federico G. Velez, MD; Stacy L. Pineles, MD; Deborah Vanderveen, MD; Kamiar Mireskandari, MD; Phoebe Lenhart, MD; Bibiana J. Reiser, MD

Duke Eye Center
Durham, North Carolina

Purpose/Relevance: Familiarize pediatric ophthalmologists with uncommon systemic etiologies that are rarely associated with relatively common anterior segment findings. Despite being rare, the systemic etiologies to be discussed should not be missed as they are typically associated with high levels of morbidity and even mortality.

Target Audience: Pediatric Ophthalmologists, Fellows and Specialists

Current Practice: Serious and complex ocular and systemic diseases may affect the anterior segment in children. Several anterior segment findings that are commonly seen by pediatric ophthalmologists can rarely be caused by a more systemic condition. These conditions are rare and usually managed only by experts at tertiary centers.

Best Practice: Basic and advanced discussion

Expected Outcomes: Participants will be familiarized with uncommon anterior segment findings of conditions that are associated with serious ocular and systemic comorbidity.

Format: Video/text and case presentations.

Summary: Panelist will present and discuss rare cases and conditions affecting the anterior segment with significant ocular and systemic implications. Audience participation will be expected and encouraged.

References: 1. Pillai GS, Radhakrishnan N. Ocular Manifestations of Pediatric Systemic Diseases. Indian J Pediatr. 2018 Mar;85(3):217-227
2. Sadiq MA, Vanderveen D. Genetics of ectopia lentis. Semin Ophthalmol. 2013 Sep-Nov;28(5-6):313-20.
3. Poll-The BT, Maillette de Buy Wenniger-Prick LJ, Barth PG, Duran M. The eye as a window to inborn errors of metabolism. J Inherit Metab Dis.2003;26(2-3):229-44.

Workshop #11
Friday, 10:30 am – 11:45 am

Evaluating the Evidence: AAPOS Research Committee In-Depth Analyses of What's New in Pediatric Ophthalmology

Gil Binenbaum; Alejandra de Alba Campomanes; Steven E. Brooks; Brian Forbes; Fatema Ghasia; Iris Kassem; Stacy Pineles

The Children's Hospital of Philadelphia
Philadelphia, PA

Purpose/Relevance: To help clinicians evaluate in greater detail the quality and clinical generalizability of recent high-profile research studies presented by the AAPOS Professional Education Committee at the 2019 Meeting, and in the process, build the critical appraisal skills of the audience.

Target Audience: Pediatric ophthalmologists and strabismologists who wish to evaluate noteworthy new research publications in pediatric ophthalmology and strabismus and acquire new skills in critical analysis of the literature.

Current Practice: Clinicians often are aware of new key articles in their field but feel unsure of how to evaluate the quality and validity of the studies, as they decide whether to incorporate new findings into their own practice. While research workshops have been conducted at past AAPOS meetings, these workshops have been mostly conceptual.

Best Practice: Practicing ophthalmologists should have the skills to critically evaluate the methodology and findings of new research findings, particularly recent studies that have a potential to change clinical practice. They need to appreciate limitations posed by bias and generalizability and assess the impact of such limitations before making changes in practice. Such skills are best taught by practical application, using studies of particularly high interest to the field.

Expected Outcomes: The audience will gain more in-depth, high-yield analysis of the most recent important studies in pediatric ophthalmology and strabismus and develop critical appraisal skills in the process.

Format: This workshop is a companion-workshop' to 'What's New in Pediatric Ophthalmology and Strabismus' and will occur in the same room and immediately follow the 'What's New' workshop. A panel of AAPOS Research Committee members will critically analyze for the audience (in much greater detail than presented in the 'What's New' workshop) 4-5 studies selected in collaboration with the Professional Education committee as being among the most important from those presented in the 2019 'What's New' workshop.

Summary: In an innovative collaboration between AAPOS committees, attendees will receive a helpful, in-depth analysis of new research studies, which may impact their clinical practice. In the process, they will increase their understanding of study design and critical appraisal, so that they can make to their own, well-informed judgments about research publications in the future.

References: Moons et al. Prognosis and prognostic research: what, why, and how? BMJ. 338:1317-20. 2009.

Workshop #12
Friday, 10:30 am – 11:45 am

'Returning to the Scene': IOL Implant-Related Reoperations

Erick D. Bothun, MD; Edward Wilson, MD; David A. Plager, MD; David Morrison, MD; Faruk Orge, MD

Mayo Clinic
Rochester Minnesota

Purpose/Relevance: Pediatric cataract surgeons hope that aphakia management, whether with contact lenses (CTLs) or intraocular lenses (IOLs), will meet the refractive needs of a patient long term. Unfortunately, CTL issues can arise which limit visual development and functioning. These include wearing compliance, surface disease, and fitting challenges. The IOLs we've counted on lasting a lifetime may opacify, decenter, or become an optical hindrance. Additionally, as the age of primary implantation was reduced, the number of severe myopes from overpowered IOLs in our practices has dramatically expanded. For these reasons, the frequency of secondary IOL placement or IOL removal, repositioning, and exchange has meaningfully increased in our practices. A discussion of the indications, challenges, options and tips for such IOL related re-operations is warranted.

Target Audience: Pediatric Ophthalmologists

Current Practice: Re-operation is often needed after cataract surgery in young children, either for placement of a secondary IOL or for the management of an IOL that decenters, lose optical clarity or contributes to high myopia. These challenges are under-reported in children. This panel includes pediatric cataract surgeons with expertise in managing such IOL challenges.

Best Practice: Clinical and surgical management with high level evidence.

Expected Outcomes: Attendees will understand the limits of aphakic management and IOL stability and be prepared to surgically manage secondary, piggyback, subluxated, and opacified IOLs.

Format: Panel presentations and discussion of patient care and surgical videos.

Summary: 1. We will discuss the indications for secondary IOL placement and IOL removal, exchange, or repositioning including literature review.
2. Surgical management of IOL related high myopia and piggyback lenses will be explained.
3. Videos will be displayed with surgical advice and tips including techniques and instrumentation.

References: 1. Causes of intraocular lens opacification or dislocation. J Cat Refract Surg. 2007 Apr;33(4):713-26.
2. Hanging by a thread: The long-term efficacy and safety of scleral sutured intraocular lenses in children (An Am Ophthalmol Soc thesis). Buckley EG. Trans Am Ophthalmol Soc 2007.
3. Long term endotheial cell loss after traumatic dislocation and repositioning of Artisan phakic IOL. J Refrac Surg. 2008;May 24(5):546-8.
4. Katherine S. Wood, Dina Tadros, Rupal H. Trivedi, M. Edward Wilson. Secondary Intraocular Lens Implantation Following Infantile Cataract Surgery: Indications, Lens Placement, and Long-term Postoperative Outcomes. Eye. 2016, September; 30(9): 1182-1186.
5. Courtney L. Kraus, Rupal H. Trivedi, M. Edward Wilson. Intraocular Lens Exchange for High Myopia in Pseudophakic Children. Eye. 2016, September; 30(9): 1199-1203.

Workshop #13
Friday, 10:30 am – 11:45 am

Challenging Cases in Pediatric Neuro-Ophthalmology - Is this Neurologic?

Lauren C. Ditta, MD; R. Michael Siatkowski, MD; Jane C. Edmond, MD; Paul H. Phillips, MD

University of Tennessee Health Science Center, Le Bonheur Children's Hospital
Memphis, TN

Purpose/Relevance: Pediatric Neuro-Ophthalmologic disorders are often clinical conundrums that create anxiety for patients, caregivers, and physicians. Additionally, neurologic disease can be particularly challenging to recognize when patients present with atypical symptoms or unusual clinical findings. By focusing on clinical history, examination, diagnostic testing, and critical interpretation of ancillary tests, the diagnosis can often be obtained...eventually. Through a case based approach, this workshop will discuss a systematic approach to evaluating patients who may present with neurologic disease or mimickers of neurologic disease.

Target Audience: Pediatric ophthalmologists and ophthalmologists evaluating pediatric patients with neuro-ophthalmologic conditions

Current Practice: Patients with complex visual and ocular symptoms are difficult to diagnose. Failure to recognize key features of the history and clinical examination can lead to incorrect diagnoses, delays in care, and unnecessary ancillary testing or erroneous interpretation of diagnostic tests.

Best Practice: A systematic approach is needed to recognize characteristics suggestive of neurologic disease processes from other benign or pathologic ocular diseases, initiate appropriate diagnostic evaluations, deliver treatment and refer care.

Expected Outcomes: At the end of this workshop, participants should be able to develop a systematic approach to evaluating symptoms which may represent neurologic disease. Additionally, the participant should feel more comfortable discriminating ocular from neurologic disease. Through discussion of clinical cases, attendees will gain tips and techniques to incorporate into daily practice.

Format: Case presentations, panel discussion, focused didactics.

Summary: The workshop will provide examples of challenging patients presenting to the pediatric neuro-ophthalmology clinic, where discerning a neurologic process can be particularly challenging. Discussion of the cases will highlight pearls and pitfalls to help discriminate ocular from neurologic disease.

References: Common Neuro-Ophthalmic Pitfalls, Case Based Teaching. Valerie A. Purvin, Aki Kawasaki. Cambridge University Press, Cambridge, UK, 2009.

Workshop #14
Friday, 10:30 am – 11:45 am

AAPOS Genetic Eye Disease Committee Workshop: Does This Patient Have a Genetic Eye Disease? Should I Refer?

Arlene V. Drack, MD; Deborah M. Alcorn, MD; Deborah M. Costakos, MD; Alex V. Levin, MD, MHScal; I. Christopher Lloyd, MBBS, FRCOphth; Virginia A. Miraldi Utz, MD; Melanie A. Schmitt, MD; Elise Heon, MD; Mary Whitman, MD, PhD; Wadih Zein, MD; Alina Dumitrescu, MD

AAPOS Genetic Eye Disease Committee

Purpose/Relevance: Recent molecular genetic advances, including FDA approval of the first gene therapy for an inherited retinal disease, RPE65 LCA, compel pediatric ophthalmologists to take increasing responsibility for accurately identifying, counseling or referring patients with genetic eye diseases. Understanding the role of genetic testing and interpretation of results is complex and continuing education is needed.

Target Audience: Pediatric ophthalmologists, residents, fellows

Current Practice: Pediatric ophthalmologists have varying levels of experience with evaluating genetic eye diseases. Many are concerned that during a busy clinic, a patient with underlying genetic disease identifiable by testing and amenable to treatment could be missed. For others, their confidence in management may not reflect the current standard of care.

Best Practice: Establishing pathways for coordination of care with a genetic eye disease specialist, genetic counselor or medical geneticist is vital. Understanding benefits and limitations of genetic diagnostic testing in relation to clinical phenotype helps to ensure correct diagnosis, counseling, and prompt referral for clinical trial enrollment or treatment interventions.

Expected Outcomes: (1) Clinicians will develop a systematic approach to identify patients with genetic eye disorders. (2) Clinicians will be able to devise pathways for comprehensive care, including differentiating among disorders appropriate for work-up by pediatric ophthalmologists versus those which require referral.

Format: Workshop will begin with an overview of different types of clinically available genetic testing. Case-based presentations focusing on algorithms for specific categories of genetic eye disorders will then be presented, e.g., work-up or refer patients who have: Photophobia? Nightblindness? Optic atrophy? School-age decreased best corrected vision? Hearing loss with/without vision loss? Albinism? Congenital nystagmus? Cataract? Poor vision in infancy? Congenital glaucoma? Summary sheets on specific eye disorders will be available and will be posted on the AAPOS website.

Summary: In a rapidly changing field, this case-based workshop will provide up-to-date algorithms to confidently provide the best care for patients with genetic eye disorders.

References: Stone EW, Aldave AJ, Drack AV, MacCumber MW, Sheffield VC, Traboulsi E, Weleber RG. Recommendations for Genetic Testing of Inherited Eye Diseases. Ophthalmology 2012;119:2408–2410.

Workshop #15
Friday, 1:15 pm – 2:30 pm
No CME for this workshop

Become a Leader in AAPOS: The Inside Tips

Darron A. Bacal, MD, FAAP; Gil Binenbaum, MD; John Roarty, MD; David Epley, MD; Mike Siatkowski, MD; David Wallace, MD; Stacy Pineles, MD; Rich Hertle, MD

Professional Education Committee of AAPOS

Purpose/Relevance: Have you ever wanted to expand your professional horizons, for your own personal fulfillment as well as for the betterment of AAPOS? What does it take to become a leader in the AAPOS community? Do you want to engage new activities or enhance current ones you participate in?
This is especially useful information for younger AAPOS members who are interested in getting involved with the society.

Target Audience: Pediatric Eye care providers with a special emphasis on those earlier in their training

Current Practice: In our training, many of the issues and opportunities (beyond medical care) are either not taught or given brief coverage.
Many Pediatric Ophthalmologists and Orthoptists want to be more involved beyond direct patient care, in areas such as political advocacy, academics etc. but do not have the tools to proceed. Others are unsure as to how to initiate the process or have fears of failure.

Best Practice: Pediatric Ophthalmologists and Orthoptists should provide great care for their patients; however this alone is insufficient in today's medical paridigm.
Providers need to step out of their comfort zone and engage in active contribution to the medical community beyond patient examinations and also to be an advocate for their patients.

Expected Outcomes: The panel will share their own stories as to how they pursued their leadership roles. They will offer a blueprint to pursue these leadership activities and discuss pearls and pitfalls from their experiences

Format: An informative panel of leaders in the AAPOS organization will share tips, strategies and stories in 8 different areas of leadership: Research, Political Advocacy, on-line Promotion, AAPOS committees, Pediatric Eye Disease Investigator Group, Residency Program Directorship, and Public Speaking.
This will be a panel discussion with ample time for audience question/answer

Summary: Leaders in AAPOS will share their stories of active engagement
Leaders in AAPOS will provide a roadmap for others to follow
Areas covered will include research, political advocacy, on-line promotion, AAPOS committee engagement, PEDIG, assuming a leadership role in academic training, and public speaking

References: Do Medical Professionalism and Medical Education Involve Commitments to Political Advocacy?
Sud, Sohil R. MD, MA; Barnert, Elizabeth S. MD, MS; Waters, Elizabeth MD; Simon, Peter MD, MPH

Academic Medicine: September 2011 - Volume 86 - Issue 9 - p 1061

Workshop #16
Friday, 1:15 pm – 2:30 pm

Periocular Dermatologic Conditions: Clinical Pearls

Lora R. Dagi Glass, MD;[1] Pavlina Kemp, MD;[2] Euna Koo, MD;[3] Alexandra Elliott, MD[4]

1. Columbia University Medical Center, New York, NY USA
2. University of Iowa, Iowa City, IA USA
3. Stanford University, Palo Alto, CA USA
4. Boston Children's Hospital, Boston, MA USA

Purpose/Relevance: Appropriate evaluation and management of the child presenting with periocular dermatologic conditions, including congenital and acquired entities such as those found in atopic, allergic, blepharitic, infectious and autoimmune conditions. These are common pediatric dermatologic conditions of the eyelid that will present to most pediatric ophthalmologists during their careers.

Target Audience: Pediatric Ophthalmologists

Current Practice: Periocular dermatologic conditions are often treated using regimens recalled from residency and fellowship, and do not necessarily incorporate practice techniques from other medical specialties.

Best Practice: This workshop will present updated, best-in-class techniques for evaluation and management of pediatric periocular dermatologic conditions. Clinical pearls will highlight pertinent signs and symptoms of congenital and acquired entities such as those found in atopic, allergic, blepharitic, infectious and autoimmune conditions; the judicious use of biopsy for diagnostic and therapeutic purposes; medical management including topical and systemic choices; and co-management with other ophthalmic subspecialists and non-ophthalmic specialties.

Expected Outcomes: Participants will have a more discerning approach to the evaluation, treatment and co-management of pediatric periocular dermatologic conditions.

Format: Clinical pearls will be presented using case presentations; presenters will also participate in a panel discussion with questions from the audience.

Summary: This workshop will review the presentation, evaluation and management of a variety of periocular dermatologic conditions in the pediatric population, focusing on congenital and acquired entities such as those found in atopic, allergic, blepharitic, infectious and autoimmune conditions. Clinical pearls will be provided through case-based learning and a panel discussion.

References:

Borok J, Holmes R, Dohil M.Idiopathic facial aseptic granuloma-A diagnostic challenge in pediatric dermatology. Pediatr Dermatol. 2018;35(4):490-493.
Pandit SA, Glass LRD. Non-glaucoma periocular allergic, atopic, and irritant dermatitis at an academic institution: A retrospective review. Orbit. 2018;9:1-7.
Rodriguez-Garcia A, Gonzalez-Godinez S, Lopez-Rubio S. Blepharokeratoconjunctivitis inchildhood: corneal involvement and visual outcome. Eye (Lond). 2016;30(3):438-46.
Viswalingam M et al. Blepharokeratoconjunctivitis in children: diagnosis and treatment. Br J Ophthalmol. 1005;89(4):400-3.

Workshop #17
Friday, 1:15 pm – 2:30 pm

Pediatric Uveitis Task Force: A Multi-Disciplinary Approach to Management Challenges in Pediatric Uveitis

Virginia A. Miraldi Utz, MD; Sheila T. Angeles-Han, MD, MSc; Brenda L. Bohnsack, MD, PhD; Ashley M. Cooper, MD; Stefanie L. Davidson, MD; Jing Jin, MD, PhD; Kara C. Lamattina, MD; PhD; Alex V. Levin, MD; Erin Stahl, MD

Purpose/Relevance: Increased understanding of the medical and surgical management of non-infectious pediatric uveitis is vital in preventing severe complications and vision loss in these patients. Our goal is to discuss the diagnosis, workup, and management of pediatric uveitis using a multi-disciplinary approach.

Target Audience: Pediatric ophthalmologists, fellows and residents

Current Practice: Although clinical guidelines and treatment algorithms exist, the optimal timing of systemic treatment initiation, surgical intervention, and discontinuation of topical and systemic medications in pediatric uveitis needs further clarification. Timely and direct communication does not always exist between the ophthalmologist and rheumatologist, potentially contributing to suboptimal control of ocular inflammation.

Best Practice: Ideal management of pediatric uveitis includes timely diagnosis, evaluation for underlying etiology, and implementation of appropriate steroid-sparing medications. Surgical intervention for ocular complications of uveitis should ideally be deferred until inflammation is controlled. Attempts to taper systemic immunosuppression may be initiated only after long-term, steroid-free remission with close monitoring and coordination of care with rheumatology. In most cases, vision-threatening complications can be avoided when the disease is expeditiously treated and closely monitored.

Expected Outcomes: Based on panel and audience discussions surrounding representative cases, clinicians will develop an evidence-based approach to the work-up and management of pediatric uveitis with emphasis on: 1) diagnostic evaluation 2) treatment algorithm that focuses on timely initiation and duration of systemic treatment, 3) use of biologic agents for uveitis, and 4) surgical management of secondary cataracts and glaucoma.

Format: Case presentations with audience participation followed by key points and algorithms by pediatric ophthalmology and rheumatology faculty.

Summary: Ophthalmology and rheumatology faculty will present an update on the current practice patterns for the evaluation and management of pediatric uveitis. Routine as well as challenging clinical vignettes encountered in practice will be presented and discussed. A multi-disciplinary approach is often required to achieve optimal vision outcomes.

References: 1. Cann et al. Pediatric Rheumatology (2018) 16:51 https://doi.org/10.1186/s12969-018-0266-5
2. Constantin T, et al. Ann Rheum Dis 2018;0:1–11. doi:10.1136/annrheumdis-2018-213131
3. Sood AB, Angeles-Han, S. Curr Treatm Opt Rheumatol. 2017 Mar; 3(1): 1–16.

Committee Members: Virginia A. Miraldi Utz, MD; Sheila T. Angeles-Han, MD, MSc; Brenda L. Bohnsack, MD, PhD; Lisa Bohra, MD; Mary Louise Z. Collins, MD; Ashley M. Cooper, MD; Stefanie L. Davidson, MD; Jing Jin, MD, PhD; Kara C. Lamattina, MD; PhD; Melissa A. Lerman, MD, PhD, MSc; Alex Levin, MD; Erin Stahl, MD; Christie Morse, MD

Workshop #18
Friday, 1:15 pm – 2:30 pm

Adult Strabismus Workshop

David Stager, Jr., MD; Steven M. Archer, MD; Edward G. Buckley, MD; David B. Granet, MD; David L. Guyton, MD; Joanne Hancox, FRCOphth; Gena Heidary, MD, PhD; Irene H. Ludwig, MD

Purpose/Relevance: The management of adults with strabismus is a growing portion of the clinical and surgical volume for many pediatric ophthalmologists. This workshop is designed to educate attendees about surgical treatment of adults with strabismus and offer practical ways to better prepare one's practice to manage this often neglected group.

Target Audience: Pediatric ophthalmologists, strabismologists, and orthoptists interested in evaluating and treating adults with strabismus.

Current Practice: Pediatric ophthalmologists may be intimidated by preparing one's practice for the unique challenges that arise in treating adult strabismus. Complicated forms of strabismus, post-operative diplopia, management of torsion, re-operations, and adjustable sutures are among the adult-specific challenges that can deter surgical intervention.

Best Practice: Clinicians will gain a more thorough understanding of surgical approaches and techniques which yield better outcomes in adults with strabismus.

Expected Outcomes: At the conclusion of this workshop, attendees will have a better understanding of how to prepare their practice for adults with strabismus through specialized diagnostic tools, surgical techniques, and advice on how to increase referrals of affected adults.

Format: The workshop will include case presentations, useful advice unique to the adult population, and discussion by a panel of experts. In addition, time for audience participation with questions of the panelists is planned. Use of video for teaching will be included. Throughout the discussions, pertinent scientific literature will be presented and reviewed.

Summary: Topics will include challenging cases of adults with complicated forms a strabismus and special surgical considerations for the adult population, as well as tips, pearls, and advice on how to prepare one's practice for adult strabismus from surgeons with years of experience.

References: Stager D Jr. Adult Strabismus: it's never too late. *JAAPOS* 2014 Apr;18(2):103-4.

Pineles S; Capo H; de Alba Campomanes A; Holmes JM; Kushner B; Velez F. Case-based overview of the management of adult strabismus secondary to ocular surgery. *JAAPOS* 2017 Aug;21(4):e54.

Kushner BJ. The benefits, risks, and efficacy of strabismus surgery in adults. *Optom Vis Sci.* 2014 May;91(5):e102-9.

Workshop #19
Friday, 2:45 pm – 4:00 pm

Alternative Treatments: Bogus or Bona Fide?

Steven Archer, MD; Kimberly Merrill, CO; Douglas Fredrick, MD; Sarah Whitecross, CO, OC(C);
Mary DeYoung Smith, CO; Anna Horwood, PhD, DBO(T); Laura Heinmiller, MD; Kathryn Haider, MD; Karl Henson, CO;
Brenda Boden, CO

University of Michigan
Ann Arbor, MI

Purpose/Relevance: We often encounter patients seeking an opinion regarding alternative vision treatments. It is important that we, as clinicians, are familiar with these therapies in order to intelligently discuss how they may or may not benefit patients.

Target Audience: Orthoptists, Pediatric Ophthalmologists

Current Practice: Orthoptists and physicians have limited familiarity with the plethora of currently promoted vision treatments that originate outside of mainstream medicine.

Best Practice: Clinical counseling supported by evidence-based knowledge of unconventional treatment alternatives.

Expected Outcomes: Attendees will be prepared to discuss the most common alternative treatments.

Format: Presentation, moderator-led discussion.

Summary: This workshop will give an overview of some of the most prevalent alternative treatments for vision-related issues. It will explore vision therapy, anti-accommodative treatments, Myovision and Neurolens, neurodevelopment businesses, sports vision training, orthokeratology, accommodative dysfunction treatments, and acupuncture/chiropractic therapies. This workshop will provide a basis to discuss these therapies with patients using evidence-based information.

References: 1. Horwood, A. Convergence accommodation in orthoptic practice. British & Irish Orthoptic Journal. 2016; 13:2-8.
2. Zhao J, Lam DS, Chen LJ, Wang Y, Zheng C, Lin Q, Rao SK, Fan DS, Zhang M, Leung PC, Ritch R. Randomized controlled trial of patching vs acupuncture for anisometropic amblyopia in children aged 7 to 12 years. Arch Ophthalmol 2010; 128:1510-7.

Workshop #20
Friday, 2:45 pm – 4:00 pm

Practical Oculoplastics for Pediatric Ophthalmologists

Laura B. Enyedi, MD; David I. Silbert, MD; Gregg T. Lueder, MD; Michelle T. Cabrera, MD; Faramarz Hidaji, MD

Purpose/Relevance: This workshop will discuss oculoplastic cases and oculoplastic surgical procedures relevant to pediatric ophthalmologists. These cases may include ptosis, epiblepharon, blepharophimosis syndrome, orbital dermoid cysts, and nasolacrimal duct obstruction. Emphasis will be on surgical treatment of these conditions including pre-operative evaluation and planning, and a post-operative care and complications.

Target Audience: Pediatric ophthalmologists and trainees

Current Practice: Pediatric ophthalmologists are presented with a challenging variety of cases including many disorders of the eyelid, orbit, and nasolacrimal system. Many pediatric ophthalmologists do not feel completely comfortable with pediatric oculoplastic procedures and may refer these to oculoplastic surgeons. Pediatric ophthalmologists who currently perform oculoplastic procedures can benefit from discussion of surgical techniques and pearls. Those who do not perform these procedures may choose to do so with further training from their peers.

Best Practice: Pediatric Ophthalmologists may perform common pediatric oculoplastic procedures. Discussion of surgical techniques can improve patient outcomes.

Expected Outcomes: At the conclusion of the workshop the the panel will have shared their experiences and techniques for the surgical management of common pediatric oculoplastic problems.. The practitioner in the audience is expected to gain confidence in these surgical procedures.

Format: Each panelist will present surgical photographs, videos and diagrams of pediatric oculoplastic cases. Panelists will discuss pearls for success for each technique.

Summary: This workshop will present surgical techniques for oculoplastic problems commonly encountered by pediatric ophthalmologists.

References: Morris CI, Buckley EG, Enyedi LB, Stinnett S, Freedman SF. Safety and efficacy of silicone rod frontalis suspension surgery for childhood ptosis repair. J Pediatric Ophthalmol Strabismus 2008;45:280-8.

Woo KI, Yi K, Kim YD. Surgical correction for lower lid epiblepharon in
Asians. Br J Ophthalmol 2000;84:1407–1410.

Beckingsale PS, Sullivan TJ, Wong VA, Oley C. Blepharophimosis: a recommendation for early surgery in patients with severe ptosis. Clin Exp Ophthalmol. 2003 Apr;31(2):138-42.

Workshop #21
Friday, 2:45 pm – 4:00 pm

Musculoskeletal Symptoms Among Ophthalmologists and How to Prevent Them

Scott E. Olitsky, MD; Donny Suh, MD; Safeer Siddicky, PhD

University of Missouri - Kansas City School of Medicine
Kansas City, MO

Purpose/Relevance: Musculoskeletal symptoms (MSSs) affect a large number of ophthalmologists. Unfortunately, our awareness of this increasingly frequent problem is far behind some of our colleagues in the healthcare industry. This leads to unnecessary injury, shortened careers and decreased capacity for healthcare delivery. Awareness and preventative measures are important not only to protect ourselves but also our patients who depend on us for their healthcare. This workshop will discuss the nature of the ergonomic issues important in the field of ophthalmology in general as well as some that may be specific to pediatric ophthalmology. Discussion will focus on the need for increased awareness, better clinic and equipment design and techniques that can be used in the operating room to lower the risk of injury. Preliminary evidence from recently designed motion analysis studies will be presented.

Target Audience: Pediatric ophthalmologists

Current Practice: Many pediatric ophthalmologists are unaware of the risks they face with regard to their own health while seeing patients or performing surgery. Improved knowledge of this issue and the ergonomic changes that can be made in both the clinic and the operating room can decrease these risks.

Best Practice: Utilization of data-driven qualifying criteria for equipment design (including surgical loupe selection and adjustment) and understanding of basic clinical ergonomics principles are crucial to maintaining balanced postures while seeing patients and while operating.

Expected Outcomes: Decreasing the risk of MSSs among pediatric ophthalmologists. Format: This workshop will consist of a panel discussion, latest research information, selected case presentations and audience participation. Specific recommendations regarding surgical loupe selection will be given. Summary: This workshop will consist of an overview of MSSs that occur among ophthalmologists who treat children and adults with strabismus, with recommendations targeted at decreasing attendant musculoskeletal risks. It will also present preliminary findings from a recently designed motion analysis study that targets postures that may contribute to MSSs.

Format: Lecture, discussion, question and answer

Summary: The workshop will discuss causes for the high incidence of MSSs in ophthalmologists. It will also discuss prevention and current and future studies looking into this important topic.

References: Dhimitri KC, McGwin G, McNeal SF, et al., Symptoms of musculoskeletal disorders in ophthalmologists. Am J Ophthalmol 139:179-81, 2005.

Workshop #22
Friday, 2:45 pm – 4:00 pm

Multimodal Imaging of the Infant and Paediatric Eye: Pearls and Pitfalls

Bhamy Hariprasad Shenoy, MBBS, MS, FICO, FRCOphth; Vinod Sharma, MBBS, MS, DNB, FRCSEd, FRCOphth; Jane Ashworth, BMCh, FRCOphth, PhD; Chethan K. Patel[1], B.Sc., MBBS, FRCOphth; Krishanthy Sornalingham;

Manchester Royal Eye Hospital, Manchester, United Kingdom
[1]Oxford Eye Hospital, Oxford, United Kingdom

Purpose/Relevance: There has been a significant increase in available imaging modalities that can be applied to paediatric ocular conditions. The application of multimodal imaging in paediatric ophthalmology practice assists clinicians in diagnosing and managing many disorders more effectively. The purpose of this workshop is to demonstrate utility and limitations of a variety of current and new imaging modalities like ultrasound bio-microscopy (UBM), optical coherence tomography (OCT), OCT-angiography, wide-field fundus imaging and autofluorescence, and integrating these to better diagnose and manage various paediatric ocular conditions.

Target Audience: Paediatric ophthalmologists, general ophthalmologists, researchers and trainees.

Current Practice: There is a gap in knowledge regarding interpretation of results obtained from the above motioned imaging-based investigations and their utility in paediatric ophthalmology practice. Not being aware of the limitations of these individual modalities can lead to false-negative or false-positive results thereby compromising patient care.

Best Practice: Ophthalmologists should be aware of utility and limitations of each of these imaging modalities and how integrating multimodal imaging could help overcome these limitations to improve diagnostic accuracy.

Expected Outcomes: The workshop will provide pearls and pitfalls in performing and interpreting the variety of imaging modalities employed in paediatric ophthalmology. Case-based discussion will highlight how multimodal imaging can be applied in a variety of disorders including metabolic eye diseases and other inherited and acquired disorders of the anterior and posterior segment.

Format: Interactive case-based discussions highlighting limitations of individual imaging modality and utility of multi-modal imaging to overcome these limitations followed by a Q&A session.

Summary: Pros, cons and limitation of commonly employed imaging modalities in paediatric ophthalmology will be discussed. Utility of multimodal imaging in overcoming limitations of individual imaging modality and improving diagnostic accuracy will be highlighted using case-based scenarios.

References: 1.Lee H, Proudlock FA, Gottlob I. Pediatric Optical Coherence Tomography in Clinical Practice-Recent Progress. Invest Ophthalmol Vis Sci. 2016;57(9):OCT69-79.
2.Toto L, dell' Omo R, Tosi GM, Querques G, Zweifel SA, Labbé A. Multimodal Imaging in Ophthalmology. Journal of Ophthalmology. 2016;2016:312-9.
3.Pichi F, Morara M, Veronese C, Nucci P, Ciardella AP. Multimodal Imaging in Hereditary Retinal Diseases. J Ophthalmol. 2013;2013:634-51.

Workshop #23
Friday, 4:15 pm – 5:15 pm

Learning Resiliency to Improve Wellness in the Workplace

LaTasha B. Craig, MD

University of Oklahoma Health Sciences Center
Oklahoma City, OKlahoma

Purpose/Relevance: Resiliency is the ability to persist in the face of adversity, and to recover from or adjust easily to misfortune or change. Resiliency is a result of positive attributes we develop through our life experiences. Although these are inherent in some individuals, it is important to know that resiliency can also be taught.

Target Audience: Medical professionals

Current Practice: In the turmoil of today's medical environment, does it appear that some of your colleagues and learners are better at coping with life's ups and downs than you?

Best Practice: The goals of this session are to arm attendees with strategies to maintain a peaceful balance by cultivating their resiliency assets.

Expected Outcomes: Development of strong resiliency assets can help us cope with setbacks, adjust to change, and deal with the normal stresses and challenges of life. We will discuss the current literature about work place resilience, and how to cultivate and develop it in ourselves. Five components of resiliency will be described, and they include relationships, emotional intelligence, competence, optimism, and coping skills.

Format: Didactic lecture with open discussion using audience polling

Summary: Resiliency can be taught and developed, even in people who do not inherently possess this skill. The author will review the literature regarding workplace resiliency, including the 5 resiliency assets. Participants will leave with a 'toolbox' of ideas to implement, and a list of resources.

References: Improving Physician Resiliencey. American Medical Association StepsForward. www.stepsforward.org/PhysicianResiliency

Workshop #24
Saturday, 2:00 pm – 3:15 pm

From Getting Started to Retirement, Practice Management Strategies That Do (and Don't) Work.

Eric A. Packwood, MD; Shira L. Robbins, MD; Michael G. Hunt, MD; G. Vike Vicente, MD; Jim Hiles, ChFC; Robert Wiggins, MD; Scott E. Olitsky, MD

Cook Children's Medical
Fort Worth, Texas

Purpose/Relevance: From getting started to retirement, pediatric ophthalmologists face scores of strategic decisions that influence their practices' effectiveness. In this workshop, experienced pediatric ophthalmologists will dissect practice life into the 3 phases of start-up, growth and retirement.

Target Audience: This program is targeted to ALL pediatric ophthalmologists and practice administrators regardless of type of practice.

Current Practice: Start-up considerations will include assembling a team of professionals, evaluating different practice options, creating and promoting a brand and building bridges with strategic partners. The growth phase involves distinct issues such as capturing collateral value (eg Real Estate, Optical, Surgery Centers, etc), recruiting partners and expanding one's scope of practice (research, teaching, etc). Retirement phase will address issues of delegating authority, sculpting one's legacy and preparing for the financial transition. Most physicians have never had formal practice management training leaving our practices more vulnerable than we would accept for patient care issues. Speakers will address strategies that have worked as well as mistakes they have made.

Best Practice: Best practice should be an educated approach to the many different business goals depending on the phase of a practice.

Expected Outcomes: Our goal is for every attendee to more carefully consider the business landscape of where their practice is now and where it is going.

Format: This material will be presented in a panel format. We will conclude with a time for questions and answers. Annual benchmarking data will be reviewed at the end of the symposium.

Summary: From start-up to retirement, pediatric ophthalmologists face scores of strategic decisions that influence their practices' effectiveness. In this workshop, experienced pediatric ophthalmologists will dissect practice life into the 3 phases of start-up, growth and retirement. Our goal is for every attendee to more carefully consider the business landscape of where their practice is now and where it is going.

References: Reider, Alan. Shuren, Allison. Simerson, Candy. 'From Obamacare to Trumpcare.' The Ophthalmologist. March 2017.

Workshop #25
Saturday, 3:30 pm – 5:30 pm

Coding a Day in the Life of the Pediatric Ophthalmologist 2019

Sue J. Vicchrilli, COT, OCS, OCSR; Shira L. Robbins, MD; Michael J. Bartiss, OD, MD; Robert S. Gold, MD, FAAP; Traci Fritz, COE

American Academy of Ophthalmology
655 Beach Street

Purpose/Relevance: Section 1 of this intensive two-hour course will begin with testing your coding competency with a rapid-fire question and answer session. Section 2 will follow with real life case presentations and coding (CPT and ICD-10) options depending upon the payer. Section 3 will address the most common payer denials and how to rectify them. All sections designed to help pediatric ophthalmologists appropriately maximize reimbursement and bullet proof their documentation in any audit situation. Participants are encouraged to email coding questions to coding@aao.org. Please list AAPOS in the subject line.

Target Audience: Ophthalmologists and their staff

Current Practice: Often erroneously applying one set of documentation requirements to all.

Best Practice: Know the documentation and claim submission rules of each individual payer.

Expected Outcomes: Upon completion of this course the participant should be able to:

- Accurately answer questions on the fundamentals of pediatric coding
- Apply principles of chart documentation, testing services requirements, and surgical coding for all payers
- Identify and correct claim submission errors which are costly to the practice

Format: Presentation with panel discussion

Summary: Section 1 of this intensive two-hour course will begin with testing your coding competency with a rapid-fire question and answer session. Section 2 will follow with real life case presentations and coding (CPT and ICD-10) options depending upon the payer. Section 3 will address the most common payer denials and how to rectify them. All sections designed to help pediatric ophthalmologists appropriately maximize reimbursement and bullet proof their documentation in any audit situation. Participants are encouraged to email coding questions to coding@aao.org. Please list AAPOS in the subject line.

References: American Academy of Ophthalmology Health Policy Committee
AAPOS section committee

Workshop #26
Sunday, 7:00 am – 8:00 am

Video Demonstrations of Signs, Diagnostics of Diseases, and Complex Surgical Procedures in Pediatric Ophthalmology and Strabismus

Sharon F. Freedman, MD; Nikos Kozeis, MD; Hana Leiba, MD; Phoebe D. Lenhart, MD; Stacy L. Pineles, MD; Ankoor S. Shah, MD, PhD

Duke University Medical Center
Durham, NC

Purpose/Relevance: Video demonstration of unusual signs, diagnostics of diseases, and surgical procedures in pediatric ophthalmology and strabismus, with an emphasis on both pediatric ophthalmology and strabismus.

Target Audience: Pediatric Ophthalmologists and Strabismologists, Orthoptists, and Ophthalmologists in training.

Current Practice: Video offers the opportunity to demonstrate clinical signs, as well as complex (and even difficulties encountered in 'common') surgical procedures that are difficult to describe fully in text or with still photographs or diagrams. Some 'common' but difficult surgical scenarios can be greatly eased by simple 'pearls' while other, more rare conditions and certain surgical approaches are seldom seen outside tertiary referral centers, but are of great interest to all who care for children and patients young and old with strabismus.

Best Practice: This workshop allows the attendees to view videos of rare signs and both common and complex surgical procedures, presented and explained by the ophthalmologist who recorded them first-hand, with discussion by an expert panel and the audience.

Expected Outcomes: This workshop is intended to increase the attendee's level of familiarity with, and confidence in examining, diagnosing, and planning treatment for these unusual clinical scenarios.

Format: Six experienced pediatric ophthalmologists and strabismologists will present and discuss videos of signs, diseases, and surgical procedures. Panelists will discuss the differential diagnosis and potential treatment options. Audience participation is encouraged.

Summary: Demonstration of classical or rare signs, diseases, surgical procedures using high quality video presentations.

Workshop #27
Sunday, 8:10 am – 9:10 am

Difficult Non-Strabismus Problems

Laura B. Enyedi, MD; Matthew Gearinger, MD; Mary A. O'Hara, MD; Ricardo Rodriguez-Rosa, MD;
David K. Wallace, MD; Tammy L. Yanovitch, MD

Purpose/Relevance: This workshop will discuss non-strabismus pediatric ophthalmology cases in which the diagnosis, findings, and / or treatment pose a clinical dilemma to even an experienced pediatric ophthalmologist. These cases may include rare diagnoses or more common diagnoses with unusual presentations and / or atypical courses. Discussion will include the experiences with similar cases of a panel of seasoned pediatric ophthalmologists, as well as audience participants, and consideration of alternative evaluation and treatment plans.

Target Audience: Pediatric ophthalmologists , orthoptists, vision scientists and trainees|

Current Practice: Pediatric ophthalmologists are presented with a challenging variety of cases. Consultation with colleagues and review of the literature can provide insights into best practices.

Best Practice: If the diagnosis and / or treatment plan for a particular patient is in doubt, consultation with colleagues can be very helpful to provide patients with the best potential for good outcomes. Group presentation of cases in some instances is helpful, particularly with very rare pediatric opthalmology problems. Advanced practitioners and audience members may have valuable insights that can assist in patient care.

Expected Outcomes: At the conclusion of the workshop the audience and the panel will have shared their experiences and strategies for the diagnosis and management of a few challenging non-strabismus pediatric ophtalmology cases. The practitioner in the audience is expected to gain new insights into the clinical reasoning behind each diagnosis and the purpose of any intervention.

Format: Each panelist will present one case and invite the other panelists to discuss their approaches to diagnosis and treatment. The audience will participate by asking questions or providing personal insights.

Summary: Case-based learning experience involving several challenging pediatric ophthalmology non-strabismus cases.

Workshop #28
Sunday, 9:20 am – 10:20 am

Difficult Problems in Strabismus.

Rosario Gomez-de-Liaño, MD; Seyhan B. Özkan, MD; Andrea Molinari, MD; Gill Adams, MD; Mohamad S. Jaafar, MD; Galton Vasconcelos, MD

International Strabismological Association
USA

Purpose/Relevance: To summarize the collective experience of our panel in the management of Difficult Problems in Strabismus in a case-based format. This workshop will address difficult cases strabismus secondary to cranial nerve palsy, restrictive strabismus, prior strabismus surgeries or orbital deformity, to fill a potential knowledge gap for the practicing ophthalmologist.

Target Audience: Pediatric Ophthalmologists, Strabismus Specialists, Ophthalmic Residents, Fellows, and Orthoptists.

Current Practice: Strabismus presents surgical dilemmas given the myriad of potential etiologies. Strabismus surgeons should understand the indications for various strabismus surgical techniques in the management of these difficult cases. Primary research in this area is limited. Practitioners utilize strategies and surgical techniques taught in fellowship or addressed at professional meetings, on the listserve, in journals, and as a result of peer-to-peer discussion.

Best Practice: This workshop allows the attendees to observe challenging cases presented and discussed by experienced strabismologists enhancing with the opportunity to discuss with the audience.

Expected Outcomes: At the conclusion of the extensive discussion the audience and the panel will have shared their experiences and strategies for the diagnosis and management of challenging cases. Exposure is designed to enhance future practice by enabling participants to apply new concepts presented.

Format: The workshop will consist on Case-based panel format presentations with short expositions focused on management of these patients. Panelists will discuss the differential diagnosis and potential treatment options. Audience questions and participation will be encouraged, time permitting.

Summary: All panel participants are internationally recognized experts in the field of strabismus. Each expert will present a difficult case for discussion by the others in an open forum format.

References: Strabismus Surgery. Basic and Advanced Strategies. Ophthalmology Monographs 17. The American Academy of Ophthalmology, Oxford University Press. 2004
Coats DK.Strabismus Surgery and Its Complications. Springer Verlag 2007.
Kuschner BJ. Strabismus: Practical Pearls You Won't Find in Textbooks. Springer Verlag 2017.

American Association for Pediatric Ophthalmology and Strabismus

www.aapos.org